

ABSTRACT BOOK

M C R

MALAYSIAN CONGRESS OF RADIOLOGY

26th - 28th July 2024



Beyond The Report: Interplay of Language and Radiology

Dewan Tun Abdul Razak,
Menara Kembar Bank Rakyat, Kuala Lumpur

Jointly Organised by:



www.malaysiancongressofradiology.com



The design of the cover page for the Malaysian Congress of Radiology 2024 feature elements such as exploring into the world of Natural Language Processing (NLP) and its potential to shake up how we do things in radiology. Together, let us embark on this enlightening journey to examine the vast potential of NLP and its direct relevance to our everyday clinical practices. Welcome to a congress that's all about embracing innovation and pushing the boundaries of what's possible in our field!

Foreword

We stand at the crossroads of medical progress, where the intricate tapestry of tradition intertwines seamlessly with the boundless realms of innovation. The Malaysian Congress of Radiology 2024, held from 26-28th July 2024 in the vibrant city of Kuala Lumpur, serves as a beacon for the convergence of foundational knowledge and cutting-edge advancements in the field of radiology.

Within the pages of this abstract book, we present the culmination of intellectual pursuit and scientific rigor, showcasing the abstracts carefully curated from a pool of brilliant minds. The theme of "Beyond The Report: Interplay of Language and Radiology" encapsulates the essence of this congress, as radiologists, radiology trainees, and allied health professionals come together to explore the harmonious interplay between time-honoured practices and pioneering technologies.

I commend the dedication and expertise of all those who have contributed to this abstract book. May it inspire fruitful discussions, ignite fresh insights, and foster collaborations that will shape the future of radiology, ensuring the highest standards of patient care and medical excellence.

Professor Dr Norlisah Mohd Ramli
President
College of Radiology, Academy of
Medicine of Malaysia 2022 – 2025
&
President
Malaysian Society of Radiologists
2023 – 2025

Professor Dr Kartini Rahmat
Organising Chair
Malaysian Congress of
Radiology 2024

Assoc Prof Dr Farhana Fadzli
Scientific Chair
Malaysian Congress of
Radiology 2024

JOURNAL OF HEALTH AND TRANSLATION MEDICINE

(formerly known as Journal of the University of Malaya Medical Centre)

JUMMEC

Contents

ORAL01: UNRAVELLING THE SECRETS OF OBESITY AND SARCOPENIA IN RELATION TO FALL AND FALL-RELATED OUTCOME IN OLDER PEOPLE (OSFOP): USE OF MAGNETIC RESONANCE IMAGING (MRI) OF BILATERAL THIGH .	8
ORAL02: AI-ENHANCED GADOLINIUM DOSING IN MRI: A PROMISING FUTURE	9
ORAL03: ROLE OF MAGNETIC RESONANCE PLANIMETRY AND MAGNETIC RESONANCE PARKINSONISM INDEX IN DISCRIMINATING PARKINSON’S DISEASE AND PROGRESSIVE SUPRANUCLEAR PALSY: A RETROSPECTIVE STUDY BASED ON 1.5 AND 3 T MRI.....	10
ORAL04: COMPOSITE SERUM PSA FACTOR IN THE PI-RADS CATEGORY IMPROVES THE DETECTION ACCURACY IN PATIENT WITH SUSPECTED PROSTATE CARCINOMA.....	11
ORAL05: ULTRASOUND MEASUREMENT OF QUADRICEPS MUSCLE AS AN ASSESSMENT TOOL FOR SARCOPENIA IN HOSPITALIZED OLDER PATIENTS	12
ORAL06: COMPUTED TOMOGRAPHY AND MAGNETIC RESONANCE IMAGING OF HYDATID CYSTS: A CASE SERIES IN AFGHANISTAN	13
ORAL07: INTERPRETATIVE PERFORMANCE OF OPPORTUNISTIC SCREENING DIGITAL BREAST TOMOSYNTHESIS IN A TERTIARY CARE HOSPITAL	14
ORAL08: MAMMOGRAPHIC SURVEILLANCE FOR BREAST CANCER SURVIVORS_A SYSTEMATIC REVIEW AND META-ANALYSIS	15
ORAL09: ACCURACY OF MRI IN DETECTING 1P/19Q CO-DELETION STATUS OF GLIOMAS: A SINGLE-CENTER RETROSPECTIVE STUDY.....	16
ORAL10: AI IN MAMMOGRAPHY IN AN OPPORTUNISTIC SCREENING AND DIAGNOSTIC CLINICAL SETTING	17
ORAL11: ACUTE ACL INJURY RELATIONSHIP WITH INCREASED VASTUS MEDIALIS TO SEMIMEMBRANOSUS CROSS-SECTIONAL RATIO AND ASSESSING OTHER CONCURRENT INJURIES USING WORMS SCORE AS A TOOL: A CASE CONTROL RETROSPECTIVE STUDY.....	18
ORAL12: BREAST MRI IMAGING FEATURES IN INVASIVE BREAST CANCER AND ITS RADIOMICS SIGNATURE AS AN IMAGING BIOMARKER	19
ORAL13: ESTABLISHING THE FIRST NEURORADIOLOGY SERVICES IN HERAT, AFGHANISTAN	20
ORAL14: RADIOLOGICAL AND CLINICAL PROGNOSTIC FACTORS IN ADULT INTRACRANIAL TUBERCULOSIS	21
ORAL15: SPIGELIAN HERNIA: A RARE CASE PRESENTATION AND REVIEW LITERATURE.....	22
POS01: IMAGING MANIFESTATIONS AND COMPLICATIONS OF ODONTOGENIC INFECTIONS: AN ILLUSTRATIVE REVIEW	23
POS02: ATYPICAL PRIMARY CNS LYMPHOMA, A GHOST TUMOUR	24

POS03: LEPTOMENINGEAL METASTASES IN NEURO-ONCOLOGY: IT'S ALL ABOUT TIMING	25
POS04: DIAGNOSTIC ACCURACY OF HYPERDENSE ARTERY SIGN IN EARLY DETECTION OF MIDDLE CEREBRAL ARTERY INFARCTION: A CROSS-SECTIONAL VALIDATION STUDY.....	26
POS05: ASSESSMENT PRECISION OF CT PERFUSION IMAGING IN THE DETECTION OF ACUTE ISCHEMIC STROKE: A SYSTEMATIC REVIEW AND META-ANALYSIS.....	27
POS06: UNVEILING THE NEUROVASCULAR ODYSSEY: A CASE OF PERSISTENT TRIGEMINAL ARTERY MIMICKING STROKE-LIKE SYMPTOMS IN A NEWLY DIAGNOSED HYPERTENSIVE PATIENT	28
POS07: PRIMARY RENAL SYNOVIAL SARCOMA PRESENTING AS COMPLEX RENAL CYST COMPLICATED WITH A LARGE PERINEPHRIC COLLECTION- A RARE CASE	29
POS08: CONTRAST-ENHANCED MAMMOGRAPHY AND MRI IN BREAST CANCER DIAGNOSIS AND EVALUATION	30
POS09: CHEST WALL DESMOID TYPE FIBROMATOSIS MIMICKING BREAST CARCINOMA - A CASE REPORT	32
POS10: A RARE CASE OF URACHAL MUCINOUS CYSTIC NEOPLASM	33
POS11: CANAL OF NUCK CYST: A RARE CAUSE OF INGUINAL SWELLING IN ADULT FEMALES.....	34
POS12: THE CT QUADRATE LOBE FOCAL HOT SPOT SIGN IN SUPERIOR VENA_CAVA OBSTRUCTION.....	35
POS13: GIANT PENILE ELEPHANTIASIS FOLLOWING MULTIPLE CIRCUMCISIONS: A RARE COSMETIC AND FUNCTIONAL COMPLICATION.....	36
POS14: ABDOMINAL PAIN WITH A TWIST: A RARE CASE OF OMENTAL TORSION	37
POS15: RARE CASE OF GIANT SIGMOID DIVERTICULUM.....	38
POS16: INTERNAL HERNIA THROUGH BROAD LIGAMENT DEFECT: A RARE CASE REPORT	39
POS17: DECIPHERING THE PUZZLE: CHALLENGES IN DIAGNOSING CAECAL BASCULE WITH SMALL BOWEL DILATATION.	40
POS18: SPONTANEOUS HEMORRHAGE OF LEIOMYOMA– A TALE OF RARE LEIOMYOMA COMPLICATION	41
POS19: INCIDENTAL FINDING OF LITHOPEDION IN A PATIENT WITH VAGUE PELVIC SYMPTOMS	42
POS20: COMPLIANCE OF THE USAGE OF WATER AS NEUTRAL ORAL CONTRAST IN CT ABDOMEN.	43
POS21: IMAGING FINDINGS OF PRIMARY PRIMITIVE NEUROECTODERMAL TUMOUR OF THE LIVER - A CASE REPORT	44
POS22: LIFE-THREATENING PULMONARY COMPLICATIONS FROM BREAST FILLER INJECTION	45
POS23: WUNDERLICH SYNDROME: A CASE REPORT	46
POS24: RENAL VASCULAR ABNORMALITIES IN A MISSED RENAL MASS.....	47
POS25: PLANTAR FASCIITIS TREATED WITH AUTOLOGOUS WHOLE BLOOD	48
POS26: MORPHOLOGY AND MORPHOMETRY EVALUATION OF ADULT COCCYX WITH MULTIDETECTOR COMPUTED TOMOGRAPHY IN SULTAN AHMAD SHAH MEDICAL CENTRE @IIUM	49
POS27: ASSOCIATION BETWEEN MEAN PLATELET VOLUME AND HEMORRHAGIC TRANSFORMATION AMONG PATIENTS WITH CEREBRAL INFARCTION IN DR. JOSE N. RODRIGUEZ MEMORIAL HOSPITAL AND SANITARIUM. 50	

POS28: DIAGNOSTIC EFFICACY OF DUAL ENERGY CT FOR DIFFERENTIATING INTRACEREBRAL HEMORRHAGE FROM IODINATED CONTRAST MATERIAL STAINING	51
POS29: LOEFFLER ENDOCARDITIS WITH VENTRICULAR LAMINAR THROMBUS	52
POS30: ATYPICAL PROSTATE METASTASIS: A CASE SERIES	53
POS31: BROAD LIGAMENT SOLITARY FIBROUS TUMOR MIMICKING HUGE OVARIAN NEOPLASM: A RADIOLOGICAL PERSPECTIVE	54
POS32: ATYPICAL MANIFESTATION OF ACUTE APPENDICITIS MASQUERADING AS MALIGNANT LESION ON CT IMAGING	55
POS33: GALLSTONE ILEUS WITH PROXIMAL SMALL BOWEL PERFORATION, A RARE COMPLICATION CARRYING SIGNIFICANT RISK OF INCREASED MORTALITY, NOT TO BE MISSED.	56
POS34: A RARE PRESENTATION: SIGMOID VOLVULUS AS THE CAUSE OF INTESTINAL OBSTRUCTION IN A YOUNG FEMALE	57
POS35: PRIMARY RENAL LYMPHOMA PRESENTING AS BILATERAL RENAL PELVIS SOFT TISSUE LESIONS- A RARE CASE	58
POS36: RUPTURED ABDOMINAL AORTIC ANEURYSM (AAA) AS A RARE CAUSE OF STROKE.....	59
POS37: COMPLICATION FROM CONSUMPTION OF ‘KING OF FRUIT’: A CASE REPORT OF SMALL BOWEL OBSTRUCTION DUE TO DURIAN SEED IMPACTION	60
POS38: UTILIZATION OF 3D MRI IN DIAGNOSING EARLY CAESAREAN SCAR ECTOPIC PREGNANCY: A CASE REPORT	61
POS39: BEYOND THE CONVENTIONAL: EXPLORING RADIOLOGICAL APPROACHES IN DIAGNOSING CERVICAL PREGNANCY	62
POS40: MISDIAGNOSED LEFT ADNEXAL MASS REVEALED AS <i>PERITONEAL</i> SPLENOSIS.....	63
POS41: PERITONEAL PARADOX: TUBERCULOSIS MASQUERADING AS ABDOMINAL MALIGNANCY	64
POS42: QUANTITATIVE MEASUREMENT OF MYELIN IN NEURODEGENERATIVE DISEASE	65
POS43: PYLEPHLEBITIS MIMICKING A MESENTERIC MASS: A RARE COMPLICATION OF PERFORATED APPENDICITIS WITH UNIQUE RADIOLOGICAL FINDINGS.....	66
POS44: PRIMARY NON-HODKIN’S LMYPHOMA MIMICKING CHOLANGIOCARCINOMA	67
POS45: HEPATIC ANGIOMYOLIPOMA MIMICKING HEPATOCELLULAR CARCINOMA.....	68
POS46: MESENTERIC FIBROMATOSIS: A LITTLE KNOWN AND RARE AGGRESSIVE BENIGN TUMOR	69
POS47: UTERINE DEHISCENCE: A RARE BUT RELEVANT POSTPARTUM COMPLICATION THAT DEMANDS ATTENTION.....	70
POS48: INCIDENCE OF RETROAORTIC RENAL VEIN IN PATIENTS WITH ACUTE FLANK PAIN	71
POS49: A RARE CASE OF METACHRONOUS SECOND PRIMARY PENILE MALIGNANCY IN A CONFIRMED PROSTATE CANCER.....	72
POS50: FREE SILICONE BREAST INJECTIONS: DIAGNOSTIC IMAGING CHALLENGES	73

POS51: ADVANCE MRI APPROACH TO DETECT RESIDUAL BREAST MALIGNANCY: A CASE REPORT.....	74
POS52: NAVIGATING THE NEXUS: PRIMARY ANGIOSARCOMA OF THE BREAST: IMAGING INSIGHTS AND HISTOPATHOLOGICAL CORRELATION	75
POS53: DIAGNOSIS CHALLENGE: SMALL BOWEL PERFORATION FROM FISH BONE INGESTION IDENTIFIED BY RADIOLOGICAL IMAGING.....	76
POS54: HISTOLOGICALLY PROVEN HIGH GRADE GLIOMA SHOWING HIGH SIGNAL ACTIVITY AMIDE PROTON TRANSFER WEIGHTED MRI: A CASE SERIES.	77
POS55: DEVELOPMENT OF VASOGENIC CEREBRAL EDEMA AFTER CT MYELOGRAM WITH NONIONIC CONTRAST	78
POS56: LYMPHOMATOSIS CEREBRI: A DIAGNOSTIC DILEMMA.....	79
POS57: DIABETIC FIBROUS MASTOPATHY MASQUERADING AS BREAST MALIGNANCY	80
POS58: LYRE SIGN – WHERE SCHWANNOMA MIMICS A CAROTID BODY TUMOUR.	81
POS59: TUBERCULOMA – A MIMICKER OF POSTERIOR FOSSA MASS IN YOUNG ADULT	82
POS60: ARTERY OF PERCHERON INFARCTION: A CASE REPORT	83
POS61: OMENTAL TORSION, AN UNACCUSTOMED MIMICKER OF ACUTE APPENDICITIS	84
POS62: THE MISSING PIECE OF A BLEEDING PUZZLE	85
POS63: UNLOCKING SOLUTIONS: THE CRUCIAL ROLE OF EMBOLIZATION IN MANAGING BLEEDING COMPLICATIONS IN AML WITH ACUTE PANMYELOSIS AND MYELOFIBROSIS.....	86
POS64: PERCUTANEOUS BIOPSY OF RETROPHARYNGEAL LESION; APPROACH AND STRUCTURES TO AVOID	87
POS65: TWO BECOME ONE: A DILEMMA BETWEEN SOFT TISSUE SARCOMA AND MALIGNANT PHYLLODES TUMOR	88
POS66: NAVIGATING THE CURVE: TORTUOUS VERTEBRAL ARTERY INDUCING NEURAL FORAMINA NARROWING CAUSING CERVICAL RADICULOPATHY.....	89
POS67: A RARE CASE OF DIEULAFOY LESION IN A MIDDLE AGED WOMAN.....	90
POS68: ISOLATED SINONASAL CRANIOPHARYNGIOMA PRESENTED AS LEFT NASAL CAVITY MIXED CALCIFIED AND CYSTIC LESIONS WITH NO SUPRASELLAR COMPONENT - A RARE CASE.	91
POS69: A CASE REPORT OF INTERVENTRICULAR MEMBRANOUS SEPTAL ANEURYSM WITH SUPRAVENTRICULAR TACHYCARDIA: CLINICAL COURSE AND CT FINDINGS.....	92
POS70: VEIN OF GALEN ANEURYSMAL MALFORMATION: A RARE CONGENITAL MALFORMATION OF CEREBRAL VASCULATURE	93
POS71: SPONTANEOUS TEMPORAL LOBE HERNIATION INTO TRANSVERSE SINUS MIMICKING VENOUS SINUS THROMBOSIS.	94
POS72: A RARE PRESENTATION OF GASTROINTESTINAL CARCINOID TUMOUR OF THE COLON	95
POS73: MORPHOLOGICAL ANALYSIS OF SUBAXIAL CERVICAL PEDICLE IN A MALAYSIA POPULATION BY USING COMPUTED TOMOGRAPHY SCAN.....	96

POS74: HEART-BREAKING EXODUS: A RARE CASE OF PERICARDIAL ABCESS BY DELAYED TUNNELLED CATHETER MIGRATION	97
POS75: 3T MRI FINDINGS OF POST TRAUMATIC ANOSMIA: A CASE REPORT	98
POS76: THE IMPACT OF THE AWARENESS CAMPAIGN ON THE FISTULOPLASTY REFERRAL AND SUCCESS RATE OF FISTULOPLASTY IN HOSPITAL USM.....	99
POS77: ATYPICAL CASE OF RUPTURED INTRACRANIAL DERMOID CYST	100
POS78: SPONTANEOUS RECOVERY OF BILATERAL OVARIAN VEINS RUPTURE FOLLOWING A MOTOR VEHICLE ACCIDENT IN A NON-PREGNANT WOMAN.....	101
POS79: GIANT ADENOMATOID ODONTOGENIC TUMOR OF MAXILLA: RADIOGRAPHIC AND PATHOLOGIC FINDING	102
POS80: REVIEW OF BREAST CANCER IMAGING CHARACTERISTICS: CORRELATION WITH CLINICOPATHOLOGICAL FEATURES AND TUMOUR MICROENVIRONMENT.....	103
POS81: UNRAVELLING THE MYSTERY: NAVIGATING AN UNUSUAL CASE OF ACUTE ABDOMEN	104
POS82: ATYPICAL PRESENTATION OF LOWER LIMB WEAKNESS AND PAIN WITH PARAVERTEBRAL SOFT TISSUE MASSES IN ACUTE LYMPHOBLASTIC LEUKAEMIA: A RARE CASE REPORT	105
POS83: ABSENT MECKEL'S CAVE AS A CAUSE OF TRIGEMINAL NEURALGIA	106
POS84: CASE OF AN UNFORESEEN CAUSE OF SMALL BOWEL OBSTRUCTION – SMALL BOWEL BEZOAR	107
POS85: NEUROIMAGING MANIFESTATIONS OF WILSON'S DISEASE.....	108

UNRAVELLING THE SECRETS OF OBESITY AND SARCOPENIA IN RELATION TO FALL AND FALL-RELATED OUTCOME IN OLDER PEOPLE (OSFOP): USE OF MAGNETIC RESONANCE IMAGING (MRI) OF BILATERAL THIGH

Vijeya PS1, Fadhli MS2, Ng KH3

Biomedical Imaging, University Malaya, Jalan Professor Ungku Aziz, Kuala Lumpur, Malaysia,

Keywords: *Obesity, Sarcopenia, Fall*

Background

The study investigates the relationship between increased thigh fat and muscle loss and the incidence of falls in elderly individuals.

Methodology

This single-center, prospective case-control study at University Malaya Medical Centre involved 76 randomly selected volunteers aged 60-80 who had MRI scans of their thighs, and 26 also had DXA scans. Data were analyzed using SPSS.

Results

Of the 76 participants, 57.9% were female, and 64.5% had experienced falls. The median age was 68, and the average BMI was 25.2. A strong correlation ($r>0.8$) was found between thigh adiposity and muscle mass in MRI and DXA scans. Overweight and obese elderly participants had significantly lower muscle mass in both cross-sectional area at 50% femur length (CSAF) ($\ln=1.82$, $p=0.031$) and mean volume of the mid-thigh (VMTT) ($\ln=6.40$, $p=0.023$) compared to non-fallers. No significant relationship was found between thigh adiposity and falls.

Conclusion

MRI of the CSA at 50% femur length correlates well with DXA for muscle mass and fat, making it effective for assessing sarcopenia. Elderly fallers with $\text{BMI} \geq 25 \text{ kg/m}^2$ had lower muscle mass, but no significant link between thigh adiposity and falls was found.

AI-ENHANCED GADOLINIUM DOSING IN MRI: A PROMISING FUTURE

Prof. Charbel Saade

University of College Cork, Ireland

Keywords: *Artificial Intelligence, Gadolinium, Dose*

Background

Artificial intelligence (AI) is revolutionizing medical imaging, and one area where it shows great promise is in optimizing gadolinium dosing during magnetic resonance imaging (MRI). Gadolinium-based contrast agents enhance MRI images, providing crucial diagnostic information.

Methods

Recent studies have revealed trace amounts of gadolinium remaining in patients' bodies after contrast-enhanced MRI exams. The implications of this deposition are not fully understood, prompting researchers to explore ways to reduce gadolinium exposure while maintaining diagnostic quality.

Results

Researchers at Stanford University have turned to deep learning - a sophisticated AI technique - to address this challenge. By training a deep learning algorithm on pre-contrast scans (zero-dose), low-dose scans (10% of standard gadolinium dose), and full-dose scans (100% dose), they achieved remarkable results. The algorithm learned to approximate full-dose images from lower-dose data, demonstrating that AI could potentially create equivalent contrast-enhanced images without any contrast agent use. Importantly, image quality remained comparable between low-dose AI-enhanced images and full-dose contrast-enhanced images.

Conclusion

This breakthrough suggests that AI has the potential to dramatically reduce gadolinium dose while preserving diagnostic accuracy. As further advancements occur, AI-driven gadolinium dosing may become a standard practice, enhancing patient safety and clinical outcomes in MRI examinations. While AI holds great promise, ongoing research and clinical validation are essential to fully realize its benefits in medical imaging. The future of dosing lies at the intersection of AI and patient care.

ROLE OF MAGNETIC RESONANCE PLANIMETRY AND MAGNETIC RESONANCE PARKINSONISM INDEX IN DISCRIMINATING PARKINSON'S DISEASE AND PROGRESSIVE SUPRANUCLEAR PALSY: A RETROSPECTIVE STUDY BASED ON 1.5 AND 3 T MRI

Fatima Mubarak

Radiology Department, Aga Khan University Hospital, Karachi. Pakistan

Keywords: *Magnetic Resonance Imaging, Parkinsonism, Parkinsons Disease, Progressive Supranuclear Palsy*

Background

Magnetic resonance imaging (MRI) has a substantial role in the diagnosis of various movement disorders. The aim of study was to evaluate the diagnostic accuracy of MRPI measured by quantitative MRI analysis and to propose MRI-based criteria to help the clinician to recognize these parkinsonian syndromes.

Methodology

After ethical approval was obtained, analysis of 34 consecutive patients with PSP, 34 patients with PD and 34 healthy controls (HCs) was performed from retrospective data from the past 10 years. The measurements of pons area–midbrain area ratio (P/M) and MCP width–superior cerebellar peduncle (SCP) width ratio (MCP/SCP) were used, and MRPI was calculated by the formula $([P/M] \times [MCP/SCP])$.

Results

Midbrain area and SCP width in patients with PSP (19 males, 15 females; mean age =66.7 years) were significantly ($P < 0.001$) smaller than in patients with PD (20 males, 14 females; mean age =66.7 years) and control participants (17 males, 17 females; mean age =66.1 years). MRPI value was significantly higher in patients with PSP (mean 21.00) than in patients with PD (mean 9.50; $P < 0.001$) and control participants (mean 9.6; $P < 0.001$), without any overlap of values among groups. No patient with PSP received a misdiagnosis when the index was used (sensitivity and specificity, 100%)

Conclusion

MRPI should be made an essential part of all MRI brain reporting whenever differentiation between PD and PSP is sought for.

COMPOSITE SERUM PSA FACTOR IN THE PI-RADS CATEGORY IMPROVES THE DETECTION ACCURACY IN PATIENT WITH SUSPECTED PROSTATE CARCINOMA

Yogambigai B¹, Hazeman Z², Idris I³, Fathinul FAS⁴

1,3 Radiology Department, Hospital Sultan Abdul Aziz Shah UPM, Persiaran Mardi UPM, Serdang, Selangor, 2, 3 Centre for Diagnostic Nuclear Imaging, Universiti Putra Malaysia, 43400 Serdang, Selangor

Keywords: *Prostate Carcinoma, Multiparametric MRI, PI-RADS*

Background

Prostate Imaging Reporting and Data System (PI-RADS) standardise the evaluation and reporting system for multiparametric MRI prostate (mpMRI) which has been used for prostate carcinoma diagnosis. However, equivocal PIRADS 3 lesions with malignant changes pose uncertainty to true positive findings. This study aimed to determine diagnostic accuracy of a composite PI-RADS (V2.1) and serum prostate specific antigen (PSA) in detecting prostate carcinoma.

Methodology

A cross-sectional retrospective study was done on 36 patients (median age 67) who underwent multiparametric-MRI (mp-MRI) prostate. PI-RADS scoring was evaluated based on the PIRADS (V2.1) categories and combined with the serum PSA. The patients were dichotomized into the PIRADS-only (PIRADS >3 versus PIRADS >4) and the composite PIRADS-serum PSA for the category of PIRADS >3 for high susceptibility of malignancy.

Results

The median PSA level was 10.5 ng/ml. Thirty-four patients (94.0%) had lesions with PIRADS 3 above in the mp-MRI. The biopsy results were positive for prostate carcinoma in 14 patients (39.0%). For the PIRADS-only category, the sensitivity and specificity of PIRADS >4 and PIRADS >3 were 78.6% and 81.8% and 100% and 9.1% respectively. For the PIRADS-PSA category, utilizing the PSA of 10 ng/ml as cut off, the PIRADS>3 revealed the sensitivity and specificity of 85.7% and 61.5%.

Conclusion

The PIRADS V2.1 category 4-5 is highly accurate in detecting prostate carcinoma with improved accuracy of the category 3-5 when the serum PSA is used as an integral factor for the composite PIRADS category.

ULTRASOUND MEASUREMENT OF QUADRICEPS MUSCLE AS AN ASSESSMENT TOOL FOR SARCOPENIA IN HOSPITALIZED OLDER PATIENTS

Muhammad Nizamuddin Bin Othman¹, Mohammad Nazri Bin MD Shah², Terence Ong³

^{1, 2} Department of Biomedical imaging, Faculty of Medicine, University Malaya,

³ Department of Medicine, Faculty of Medicine, University Malaya

Keywords: Sarcopenia, SARC-F, SARC-Calf, Calf Circumference, Ultrasound Quadriceps

Background

Sarcopenia is defined as 'age-related loss of muscle mass, reduced muscle strength, and/or diminished physical performance'. Ultrasound can be used to assess muscle mass, specifically the quadriceps femoris. This study aimed to examine the relationship between the risk of sarcopenia among hospitalized older patients and quadriceps muscle using ultrasound.

Methodology

A single-centre prospective study involving 40 participants aged ≥ 65 who were admitted to the medical ward between June 2021 and July 2022. Ultrasound measurements of quadriceps muscle were taken, including quadriceps muscle layer thickness (QMLT), rectus femoris cross-sectional area (RFCSA), pennation angle (PA), and fascicle length (FL). Participants were assessed for sarcopenia risk using SARC-F (score ≥ 4) and SARC-calF (≥ 11).

Results

The mean age was 75.9 (± 7.0) years, 25(62.5%) were female, and majority being Malay (17,42.5%). Mean duration of scan was 1.5 days from admission with mean time was 8.6 minutes. SARC-F identified 21(52.5%) at risk, SARC-calF 22(55.0%), and calf circumference 25(62.5%). No difference in age, gender, ethnicity (except Malay, p-value:0.021) and body mass index (except SARC-calF, p-value:0.016) between those at risk and not at risk. Statistically significant relationship between SARC-calF and QMLT (No risk: mean (SD): 2.55 ± 0.66 , at risk: 1.99 ± 0.54 , 95% CI: 0.559, p-value: 0.005), RFCSA (No risk: 3.37 ± 1.10 , at risk: 2.49 ± 1.18 , 0.887, 0.02), and PA (No risk: mean (SD): 13.56 ± 3.25 , at risk: 10.34 ± 2.65 , 3.222, 0.002). No significant associations were observed with SARC-F.

Conclusion

Ultrasound quadriceps muscles provides a possible method to identify older hospitalised patients at risk of sarcopenia.

COMPUTED TOMOGRAPHY AND MAGNETIC RESONANCE IMAGING OF HYDATID CYSTS: A CASE SERIES IN AFGHANISTAN

Abdul Qadir, QADER

1. Radiology Department of Herat Medical Faculty, Herat University, Herat, Afghanistan. 2. Section Global Health, University Hospital Bonn, Venusberg Campus 1, 53127 Bonn, Germany

Keywords: Hydatid Cysts, Case Series

Abstract

Hydatid cysts, caused by the parasitic tapeworm *Echinococcus*, can manifest in various organs. Different sizes and shapes of hydatid cysts may create diagnostic challenges. Although ultrasound imaging with high resolution is the first choice for diagnosis, it rarely leads to a definite diagnosis. We describe the varying imaging findings seen in 10 cases of hydatid cysts on computed tomography (CT) and magnetic resonance imaging (MRI) encountered in Afghanistan from 2021 to 2024. In our cases, hydatid cysts were found in the liver, brain, orbit, chest, spleen, kidney, spine and muscle. CT is particularly valuable for osseous organ involvements and best shows cyst wall calcification. MRI can differentiate HD from neoplasms and is preferable in biliary or neural involvements. Familiarity with typical clinical presentation, CT scan and MR imaging findings of hydatid cysts in these sites facilitate the radiologic diagnosis and guiding timely intervention.

INTERPRETATIVE PERFORMANCE OF OPPORTUNISTIC SCREENING DIGITAL BREAST TOMOSYNTHESIS IN A TERTIARY CARE HOSPITAL

Dr Lim Shu Syi¹, Prof Dr Kartini R¹, Dr Leong Wai Ling¹
Biomedical Imaging Pusat Perubatan Universiti Malaya

Keywords: Breast cancer, Digital breast tomosynthesis, Full film digital mammogram, screening

Background

In Malaysia, breast carcinoma contributes to 8418 (32.9%) of all newly diagnosed cancers among women in the year 2020. Screening mammography has 30 – 40% relative reduction in breast cancer mortality. Unfortunately, sensitivity of mammography decreases 30 - 48% in women with dense breasts. Digital breast tomosynthesis (DBT) is an advanced imaging technique used for diagnosing and screening breast lesions, particularly in dense breasts. Therefore, this study aims to assess the diagnostic accuracy of DBT in combination with full film digital mammogram (FFDM).

Methodology

Retrospective study which recruits women underwent DBT at the Department of Biomedical Imaging, University of Malaya Medical Centre (UMMC) in year 2019. These include opportunistic screening, targeted screening and diagnostic mammograms. Histological diagnosis was obtained from BIRADS 4 and 5 lesions and analysis was done. Cancer detection rate (CDR), biopsy rate (percentage of biopsies performed) and positive predictive value (PPV) for biopsy (number of malignancies from histopathology test) were calculated.

Results

A total of 1064 patients were included, ranging from 30 to 98 years old. Of these, 869 women were screening (82.65%), 108 targeted screening (10.1%) and 87 diagnostic (8.2%) examinations. Biopsies for suspicious lesions were carried out for 43(5%)in opportunistic screening, 17(15.8%) in targeted screening and 50 (57.5%)in diagnostic group. The PPV for biopsies was 39.5 % in the opportunistic screening group, 29.4% in targeted screening group and 44% in diagnostic group respectively. 434 (40.7%) of the patients were in BIRADS density C and D category. 141 (13.1%) and 489 (45.9%) patients were in BIRADS density A and B respectively. 19 out of 44 (43%) cancer detected in dense breast (BIRADS density C and D).

Conclusion

DBT improves the diagnostic accuracy of mammography compared to FFDM as evidenced by higher CDR and PPV for biopsy.

MAMMOGRAPHIC SURVEILLANCE FOR BREAST CANCER SURVIVORS: A SYSTEMATIC REVIEW AND META-ANALYSIS

Ajeng VI1-3, Lina C1, Afdina MGF4, Afina ALK4, Dhite BN2,5

1Department of Radiology, Faculty of Medicine, Public Health and Nursing, Universitas Gadjah Mada, Yogyakarta, Indonesia

2Clinical Epidemiology and Biostatistic Unit (CEBU), Faculty of Medicine, Public Health and Nursing, Universitas Gadjah Mada, Yogyakarta, Indonesia

3Department of Health Sciences, University of Groningen, University Medical Center Groningen, Groningen, the Netherlands

4Faculty of Medicine, Public Health, and Nursing, Universitas Gadjah Mada, Indonesia

5Department of Internal Medicine, Faculty of Medicine, Public Health and Nursing, Universitas Gadjah Mada, Yogyakarta, Indonesia

Keywords: *Mammography, Breast Cancer, Mortality, Surveillance, Cancer Survivors*

Background

The number of breast cancer survivors has significantly increased due to the success of treatment, which has improved the clinical outcomes for patients. Despite recommendations for annual mammograms among survivors, few studies have explored into whether mammography lowers the risk of death in the post-treatment years. This review aimed to investigate the efficacy of mammographic surveillance in reducing mortality among breast cancer survivors.

Methodology

We conducted a systematic search at the Cochrane Central Register of Controlled Trials, Medline, and Scopus. Two reviewers screened the titles and abstracts of all identified articles and then selected relevant studies through full-text reviews. Studies on mortality outcomes associated with mammographic surveillance in breast cancer survivors were included. Data were extracted, and a meta-analysis was performed using the statistical software R. The risk of bias was evaluated using New-castle Ottawa Scale.

Result

From a total of 1,643 studies, we identified six eligible studies. Five studies exhibited a low risk of bias, while one showed a moderate risk. Five studies were finally included in the meta-analysis (N=2,514) and revealed that mammography surveillance reduced the odds of mortality by 50% (OR 0.50; 95% CI 0.27, 0.92) compared to cases without surveillance. There was high heterogeneity in the meta-analysis ($I^2=92%$), possibly due to variations in intervention delivery (e.g. frequency, intensity) and outcome measures (e.g. breast cancer mortality, all-cause mortality).

Conclusion

Mammographic surveillance significantly reduced the mortality for breast cancer survivors, making post-treatment follow-up essential in their care.

ACCURACY OF MRI IN DETECTING 1P/19Q CO-DELETION STATUS OF GLIOMAS: A SINGLE-CENTER RETROSPECTIVE STUDY

Fatima Mubarak

Radiology Department, Aga Khan University Hospital, Karachi. Pakistan

Keywords: *Magnetic Resonance Imaging, 1p19q Co-Deletion, Gliomas*

Background

Oligodendrogliomas, in the frontal lobe's white matter, are reshaped by molecular markers like isocitrate dehydrogenase mutations and 1p/19q co-deletion, influencing outcomes. Despite initial indolence, these tumors pose a significant risk, with median survival of 10-12 years. Non-invasive alternatives, such as magnetic resonance imaging (MRI) for assessing T2-fluid-attenuated inversion recovery (FLAIR) mismatch and calcifications, provide insights into molecular subtypes and aid prognosis. Our study explored these features to predict the oligodendroglioma status and refine patient management to improve outcomes.

Methodology

In this retrospective study, patient undergoing MRI, revealing low-grade gliomas. Surgical biopsy and 1p/19q fluorescence in situ hybridization confirmed the co-deletion status. MRI was used to assess various morphological features. Statistical analyses included x2 tests, Fisher's exact tests, Kruskal-Wallis tests, and binary logistic regression models, with significance set at $p < 0.05$.

Results

Seventy-three patients (median age, 37 years) were stratified according to 1p/19q co-deletion. Most (61.6%) 18-40 years old and mostly male (67.1%). Co-deletion cases, primarily frontal lobe lesions (67.6%), unilateral (88.2%), 55.9% non-circumscribed margins and 58.8% ill-defined contours. Smooth contrast enhancement and no necrosis were observed in 48.1% of 1p/19q co-deletion cases. Logistic regression analysis showed a significant association between ill-defined/irregular contours and 1p/19q co-deletion. Fisher's exact test confirmed this but raised concerns about the small sample size influencing the conclusions.

Conclusion

This study established significant link between glioma tumor contour characteristics, particularly irregular and ill-defined contours, and likelihood of 1p/19q co-deletion. Our findings underscore the clinical relevance of using tumor contours in treatment decisions and prognosis assessments.

AI IN MAMMOGRAPHY IN AN OPPORTUNISTIC SCREENING AND DIAGNOSTIC CLINICAL SETTING

Nazimah AM¹, Marlina Tanty RH¹, Shamsiah AH¹, Kartini R²

1 Department of Radiology, Faculty of Medicine, Universiti Teknologi MARA, Jalan Hospital, 47000, Sungai Buloh, Selangor

2 Department of Biomedical Imaging, Faculty of Medicine, Lembah Pantai, 50920, Kuala Lumpur

Keywords: *Mammography; Breast; Neoplasm; Artificial Intelligence*

Background

Artificial intelligence (AI) has the potential to revolutionize breast cancer screening and diagnosis by compensating the limitations of mammography. This study assesses the efficacy of AI in mammography for combined screening and diagnosis in a clinical context.

Methodology

A retrospective analysis was conducted on 543 mammograms. Three breast radiologists independently interpreted the mammograms in two sessions: one without AI support and one with AI assistance. Assessment criteria included breast density, BI-RADS categories, and diagnostic parameters such as accuracy, sensitivity, specificity, positive predictive value (PPV), negative predictive value (NPV), and the rate of unnecessary biopsies.

Results

Among the 543 mammograms, 69.2% revealed detected lesions, leading to biopsies in 25% (n=136), resulting in 48.5% benign and 51.5% malignant cases. There was substantial agreement between radiologists and AI in assessing breast density ($\kappa = 0.606$, $p < 0.001$) and BI-RADS categories ($\kappa = 0.74$, $p < 0.001$). Sensitivity, specificity, PPV, and NPV for radiologists alone, radiologists with AI, and AI alone were 81.9%, 90.4%, 56.0%, and 97.1%; 81.0%, 93.1%, 55.5%, and 97.0%; and 90.0%, 76.5%, 36.2%, and 98.1%, respectively. The AI reduced unnecessary biopsies, particularly in BI-RADS 4 lesions. The rate of unnecessary biopsies decreased from 16.5% (n=22/136) without AI to 12.5% (n=17/136) with AI for BI-RADS 4a and from 2.9% (n=4/136) without AI to 2.2% (n=3/136) with AI for BI-RADS 4b, indicating reductions of 4.0% and 0.7%, respectively.

Conclusion

AI software demonstrates potential in enhancing the accuracy of breast lesion diagnosis, thereby improving diagnostic performance in opportunistic screening and diagnostic examinations.

ACUTE ACL INJURY RELATIONSHIP WITH INCREASED VASTUS MEDIALIS TO SEMIMEMBRANOSUS CROSS-SECTIONAL RATIO AND ASSESSING OTHER CONCURRENT INJURIES USING WORMS SCORE AS A TOOL: A CASE CONTROL RETROSPECTIVE STUDY

Shaukani, M.A.; Rozalli, F. I.; Rahmat, K.; Fadzli, F.

Bio-medical Imaging, University Malaya, Jalan Prof Diraja Ungku Aziz, Kuala Lumpur, Malaysia.

BACKGROUND

This study aims to evaluate the vastus medialis (VM) with semimembranosus muscle (SM) cross-sectional area (CSA) ratio in cases of ACL tear with control group, and secondary degenerative changes using WORMS score.

METHODOLOGY

This is a single-centred retrospective cross-sectional study of 50 patients with ACL tears and another group of 50 control patients in the University Malaya Medical Centre (UMMC) from the 1st of June 2021 to the 31st of October 2022. The VM and SM CSA ratio were measured in both case and control groups, and WORMS score was used to assess degenerative changes and concurrent knee injuries.

RESULTS

This study reveals that there is no statistically significant difference in the VM: SM CSA ratio between the case and control group ($p=0.596$), contradicts the findings of a study conducted by Weischhoff et al. However, a significant number of ACL tear patients demonstrate degenerative and other concurrent intra-articular injuries such as in menisci (78%), ligaments (60%), and synovitis (70%). In addition, there were degenerative alterations including cartilage abnormalities (44%), bone lesions (48%), bone attrition (36%), and osteophytes (36%). The majority of the changes occurred at the medial femoral-tibial joint (56%), followed by the lateral (56%) and patellofemoral (52%) joints.

CONCLUSION

In summary, while the study did not establish a statistical significance in the VM:SM CSA ratio or its correlation with ACL tears, it reveals important insights into the concurrent injuries that can occur with ACL tear and degenerative changes, within the intra-articular knee structures.

BREAST MRI IMAGING FEATURES IN INVASIVE BREAST CANCER AND ITS RADIOMICS SIGNATURE AS AN IMAGING BIOMARKER

Nazimah Ab Mumin¹, Chuin-Hen Liew², Song-Quan Ong³, Marlina Ramli Tanty Hamid¹, Hsiu Ding Wong⁴, Kartini Rahmat⁴, Kwan Hoong Ng⁴

1. Department of Radiology, Faculty of Medicine, Universiti Teknologi MARA, Malaysia

2. Hospital Tuanku Ampuan Najihah, Negeri Sembilan, Malaysia

3. Institute For Tropical Biology and Conservation, University Malaysia Sabah, Kota Kinabalu, Sabah, Malaysia

4. Department of Biomedical Imaging, Faculty of Medicine, Universiti Malaya, Malaysia

Objectives

Accurate subtyping of breast cancer is essential. This study investigated visual analysis and machine learning of MRI breast features with the breast cancer molecular subtype.

Methods

This retrospective study included MRI images of treatment-naive patients with invasive breast carcinoma. Four MRI sequences were analysed: T1-weighted, T2-weighted, STIR/TIRM, and T1-weighted post-contrast. Breast MRI features were recorded based on ACR-BIRADS criteria. Associations between MRI features were analysed in relation to breast cancer subtypes, determined via immunohistochemistry (IHC). Texture features were extracted and trained with a classifier algorithm to identify the best predictors for each subtype.

Results

The study included 194 patients: 41.8% Chinese, 40.7% Malay, and 17.5% Indian, with subtypes including 71.6% luminal-like, 12.9% HER-2 enriched, and 15.5% Triple-negative breast cancer (TNBC). TNBC was associated with rim enhancement ($p=0.002$) and peritumoral oedema ($p=0.004$). HER-2 tumours were associated with larger size ($p=0.041$). Luminal-like cancer was associated with irregular shape ($p=0.005$) and circumscribed margins ($p=0.003$). For machine learning, 162 cases were analysed. The texture feature included 303 variables, and feature selection used a hybrid Random Forest (RF) and Recursive Feature Elimination (RFE) algorithm. Using 5-fold cross-validation, the top 10 features for each subtype were selected to maximize AUROC. Redundant features were removed, resulting in 5 predictive variables for luminal-like, 5 for HER-2, and 4 for TNBC. The AUROC was 0.770 for luminal, 0.650 for HER-2, and 0.747 for TNBC when combining radiologists' assessments and texture features.

Conclusion

Specific MRI features from visual assessment and radiomics were identified to differentiate breast cancer molecular subtypes.

ESTABLISHING THE FIRST NEURORADIOLOGY SERVICES IN HERAT, AFGHANISTAN

Abdul Qadir, QADER

1. Radiology Department of Herat Medical Faculty, Herat University, Herat, Afghanistan.

2. Section Global Health, University Hospital Bonn, Venusberg Campus 1, 53127 Bonn, Germany

Keywords: *Neuroradiology, Low-Income Country, Afghanistan*

Background

Radiology is one of the underdeveloped medical fields within the healthcare landscape in Afghanistan. The diagnostic imaging services in local hospitals are limited to basic modalities. In 2022, the first state-of-the-art diagnostic and medical imaging centre was established in Herat, Afghanistan by a radiologist upon returning from Malaysia for his specialization in Radiology.

Methodology

Neuroradiology service is one of the first services to be provided by the imaging centre due to a severely unmet need within the region. We present the detailed establishment process from the conceptualization to the actualization phases. The neuroradiology cases are reported by a resident radiologist and a radiologist working off-site via telemedicine and interventional cases performed with cooperation of neurosurgeons.

Results

MRI, CT, CTA of the brain, spine, head and neck, and cerebral angiograms are some of the neuroradiology services currently available. To date, the average number of neuroradiology imaging performed daily and monthly are 15 and 360 cases respectively. The center also works closely with the Faculty of Medicine, Herat University to provide training sessions to students in various disciplines.

Conclusion

The first neuroradiology service was successfully established in Herat, Afghanistan in 2022 after overcoming challenges in terms of lack of funding, qualified healthcare workers and technical support. Continuous collaboration with local and international organizations are required to ensure the provision of a sustainable neuroradiology service and to fulfil our aspiration to provide interventional neuroradiology services to the local community.

RADIOLOGICAL AND CLINICAL PROGNOSTIC FACTORS IN ADULT INTRACRANIAL TUBERCULOSIS

Andrew Leslie Lee¹, N Ariana Azlee¹, Jeannie Hsiu Ding Wong², Nur Safira Abd Isa², Norlisah Ramli²

¹Faculty of Medicine, University of Malaya, Kuala Lumpur, Malaysia, ²Department of Biomedical Imaging, University of Malaya Medical Centre, Kuala Lumpur, Malaysia

Keywords: Intracranial Tuberculosis, Imaging, Prognostic Factors

Background

Intracranial tuberculosis (TB) is the most severe form of extra-pulmonary TB, carrying significant morbidity and mortality. Our study examined factors influencing outcomes in these patients.

Methodology

This retrospective study included all patients diagnosed with intracranial TB at University Malaya Medical Centre (2010-2020) using the Lancet consensus criteria. Clinical, laboratory and radiological (CXR/CT/MRI) findings on admission were identified. On brain imaging, presence of tuberculomas, enhancement pattern, hydrocephalus and infarction were assessed. Findings were compared according to functional outcome on the modified Rankin scale (mRS) at 90 days (good: mRS 0-2, poor: mRS 3-6), using the Fisher's exact test and Mann-Whitney test (p values < 0.05 considered significant). Correlation with functional outcomes was done using logistic regression. Cases without imaging were excluded.

Results

This study included 31 adults diagnosed with intracranial TB (median age: 37 years, range: 18-67 years). Poor functional outcomes were observed in 51.61% patients and were independently associated with lack of BCG inoculation (adjusted odds ratio (aOR) 8.170, 95% CI 1.130-59.064) and abnormal CXR (aOR 7.619, 95% CI 1.129-51.41). We found significant differences between good and poor outcomes in patients with cerebrospinal fluid (CSF) lymphocytes (median: 91.5% vs median: 38%), CSF polymorphs (median: 8.5% vs median: 52%) and cerebral infarction (0% vs. 100%).

Conclusion

Poor functional outcomes in adults with intracranial TB were associated with lack of BCG inoculation and an abnormal CXR. Cerebral infarction was significantly higher in patients with poor outcomes. These findings may guide treatment optimisation.

SPIGELIAN HERNIA: A RARE CASE PRESENTATION AND REVIEW LITERATURE

Ramanathan SRM

Department of Radiology, KPJ Damansara, Petaling Jaya, Selangor, Malaysia

Keywords: *Acute abdomen, Hernia, Spigelian Hernia*

Spigelian hernia is an uncommon variety of abdominal wall hernia which has a probability of 0.1-2% of occurrence. 172-year-old female patient with no known medical history complained of extreme abdomen pain since the day before the diagnosis. The pain was at the lower side of the abdominal . She was admitted when there was no cessation of the pain. An abdominal CT scan was done and showed Spigelian hernia. Given her age and fragility of the situation, the patient was suggested laparoscopic repair of Spigelian hernia. Spigelian hernia occurs in the abdomen and is the rarest form of all abdominal hernias. Clinically detecting hernia is not an easy task and imaging is helpful.

IMAGING MANIFESTATIONS AND COMPLICATIONS OF ODONTOGENIC INFECTIONS: AN ILLUSTRATIVE REVIEW

Alice Kwok Yan LI¹, Elva On Wa NG¹, Kenneth Hoi Ming KWOK¹

¹Department of Radiology, Kowloon West Cluster Hospitals, Hong Kong

Keywords: *Odontogenic Infection, Head And Neck Infection, Complications*

Abstract

Odontogenic infections are common conditions that harbour potential risk of significant morbidity if left untreated. Imaging plays a crucial role in the evaluation and management of these infections by facilitating the identification of infection source, allowing prompt detection of associated complications and determining the extent of involvement. Through illustrative cases, we will discuss the characteristic imaging features of complications such as cellulitis, abscess formation, Ludwig's angina, airway obstruction and necrotizing fasciitis. Furthermore, we will explore and elucidate the routes in which infection can extend from the oral cavity to the paranasal sinuses, orbits, intracranial and deep neck spaces, as well as down to the mediastinum. By familiarizing clinicians and radiologists to the imaging manifestations of odontogenic infections and emphasizing the anticipation in pathway of spread, we aim to enhance early recognition and enable timely intervention to prevent development of life-threatening complications.

ATYPICAL PRIMARY CNS LYMPHOMA, A GHOST TUMOUR

Muhammad Aminuddin, A¹; Asiah ZA²; Izzat Arslan CR¹; Shahizon Azura MM¹

¹Radiology Department, Hospital Canselor Tuanku Muhriz, Jalan Yaacob Latiff, Bandar Tun Razak, 56000, Kuala Lumpur, Malaysia, ²Radiology Department, Hospital Putrajaya, Presint 7, 62250 Putrajaya, Malaysia.

Keywords: *Atypical Primary CNS Lymphoma, MRI, Oncology*

Abstract

Atypical imaging characteristic of lymphoma often leads to delay in diagnosis and treatment initiation. Non enhancing CNS lymphoma is the most rarely reported, occurring at an incidence of 1%. We report a case of elderly woman, presented with forgetfulness without other significant clinical neurological. MRI brain revealed diffuse white matter changes in both hemisphere without any focal area of enhancement. This is highlighting that PCNSL should be considered even when non-enhancing, diffuse white matter lesions are seen on MRI.

LEPTOMENINGEAL METASTASES IN NEURO-ONCOLOGY: IT'S ALL ABOUT TIMING

Charbel Saade

University of College Cork, Ireland

Keywords: *Magnetic Resonance Imaging, Leptomeningeal Metastases, Gadolinium*

Background

Knowledge of the patterns and mechanisms of gadolinium enhancement facilitate radiologic differential diagnosis especially when understanding the mechanism of blood-brain barrier.

Methods

Brain enhancement is related to both intravascular and extravascular gadolinium enhancement. Leptomeningeal (pia-arachnoid) enhancement is present in meningitis and meningoencephalitis. Superficial gyral enhancement is seen after reperfusion in cerebral ischemia, during the healing phase of cerebral infarction, and with encephalitis. Nodular subcortical lesions are typical for hematogenous dissemination and may be neoplastic (metastases) or infectious (septic emboli).

Results

Postcontrast FLAIR MRI sequences have been shown to be valuable in the detection and evaluation of different leptomeningeal diseases, including subarachnoid hemorrhage, meningitis, and infectious meningitis. The nulling of the CSF signal due to the inversion time facilitates an optimized delineation of hyperintense pathology adjacent to the CSF in the sulcal and leptomeningeal space while the T1 shortening in FLAIR sequences is responsible for the highly sensitive delineation of pathologic contrast enhancement following application of gadolinium.

Conclusion

Understanding the classic patterns of lesion enhancement - and the radiologic-pathologic mechanisms that produce them—can improve image assessment and differential diagnosis.

DIAGNOSTIC ACCURACY OF HYPERDENSE ARTERY SIGN IN EARLY DETECTION OF MIDDLE CEREBRAL ARTERY INFARCTION: A CROSS-SECTIONAL VALIDATION STUDY

Fatima Mubarak

Radiology Department, Aga Khan University Hospital, Karachi. Pakistan

Keywords: *Hyperdense Artery, Middle Cerebral Artery Infarction, Diagnostic Accuracy*

Background

Hyperdense middle cerebral artery sign (HMCAS) on a non-enhanced multidetector computed tomography (MDCT) scan is considered an important radiological marker in detecting acute arterial thrombotic occlusion, and it is one of the earliest signs of ischemic cerebrovascular accident (CVA). This finding has been observed within 90 min of symptom onset. Modern approaches to patients with cerebral infarction emphasize early diagnosis and management.

Methodology

A total of 140 patients aged 35–70 years, referred to the radiology department of Aga Khan University Hospital with clinical suspicion of acute cerebral infarction, were included. After clinical suspicion of acute infarction, the patient underwent an initial complete MDCT scan of the brain, which was performed using Aquilion ONE 640 slice MDCT (Toshiba Medical Systems, Japan). Consultant radiologists, with a minimum of 5 years of experience in MDCT brain imaging, interpreted the images. Follow-up examination with MRA within 24 h was performed to confirm the diagnosis of MCA infarction.

Results

Overall sensitivity, specificity, positive predictive value, negative predictive value, and diagnostic accuracy of HMCAS in the early detection of MCA infarction on non-contrast-enhanced MDCT scan using MRA as the gold standard for definitive diagnosis was 96.20%, 93.44%, 95.0%, 95.0%, and 95.0%, respectively.

Conclusion

This study concluded that the diagnostic accuracy of hyperdense artery signs in the early detection of MCA infarction on non-contrast-enhanced MDCT scans is very high.

ASSESSMENT PRECISION OF CT PERFUSION IMAGING IN THE DETECTION OF ACUTE ISCHEMIC STROKE: A SYSTEMATIC REVIEW AND META-ANALYSIS

Fatima Mubarak

Radiology Department, Aga Khan University Hospital, Karachi. Pakistan

Keywords: *Ischemia, CT Perfusion, Metaanalysis*

Background

Stroke, a prevalent medical emergency, comprises ischemic and hemorrhagic subtypes, with acute ischemic stroke (AIS) being predominant type. The application of computed tomography perfusion (CTP) imaging has gained prominence due to its rapidity and accessibility in stroke evaluation.

Methodology

This study systematically reviews and conducts a meta-analysis of existing literature to assess the diagnostic accuracy of CTP in detecting AIS and predicting hemorrhagic transformation (HT). Employing Preferred Reporting Items for Systematic Reviews and Meta-Analyses (PRISMA) guidelines, an extensive search was conducted across electronic databases and relevant radiology journals. Studies conducted between 2007 and 2023 that fulfilled predetermined inclusion criteria underwent quality assessment using the Quality Assessment of Diagnostic Accuracy Studies 2 (QUADAS 2) tool. Cochrane diagnostic accuracy tools were used for data extraction. Thirteen studies involving a total of 1014 patients were included in the analysis.

Results

The diagnostic performance of CTP in predicting HT demonstrated high sensitivity (86.7%) and moderate specificity (77.8%), resulting in an overall accuracy of 79.1%. The negative predictive value (NPV) (92.9%). The positive predictive value (PPV) was (60.3%), highlighting the need for clinical context when making thrombolysis decisions. The false positive rate was 16.2%, while the false negative rate was minimal (9.8%).

Conclusion

The findings of this study emphasize the promising diagnostic accuracy of CTP imaging in predicting HT subsequent to AIS.

**UNVEILING THE NEUROVASCULAR ODYSSEY: A CASE OF PERSISTENT TRIGEMINAL ARTERY MIMICKING
STROKE-LIKE SYMPTOMS IN A NEWLY DIAGNOSED HYPERTENSIVE PATIENT**

Nurain M1, Nurhayati M2, Naveen R3, Thajunnisa H4

KPJ Damansara Specialist Hospital

Keywords: *Persistent Trigeminal Artery*

Persistent Primitive Trigeminal Artery (PPTA) is a rare vascular anomaly found in a small percentage of individuals, connecting the carotid and vertebrobasilar arteries. Originating during fetal development, this anomaly can persist into adulthood, deviating from the normal regression of fetal vessels. It often follows an atypical course, running along the trigeminal nerve or passing through specific anatomical structures. Associated with hypoplasia in nearby arteries, it can impact cerebral blood flow dynamics, potentially leading to complications like inadequate perfusion and thrombosis. In a recent case study of a 58-year-old male with left-sided body numbness, advanced imaging revealed a PPTA. This emphasizes the importance of understanding such anomalies, especially in cases with unusual neurological symptoms, as they may contribute to conditions like vertebrobasilar insufficiency. Recognizing the role of PPTAs in neurological presentations is crucial for accurate diagnosis and management, particularly in patients with vascular risk factors like hypertension and dyslipidemia.

PRIMARY RENAL SYNOVIAL SARCOMA PRESENTING AS COMPLEX RENAL CYST COMPLICATED WITH A LARGE PERINEPHRIC COLLECTION- A RARE CASE

Muhamad Asyraf Jamaluddin^{1,4}, Iqbal Hussain Rizuana^{1,4}, Marhani Yati Marmono², Noraini Mohd Dusa³

1 1 Department of Radiology, Faculty of Medicine, Universiti Kebangsaan Malaysia

2 Department of Radiology, Hospital Kuala Lumpur

3 Department of Pathology, Hospital Kuala Lumpur

4 Hospital Canselor Tuanku Muhriz

Keywords: *Renal Synovial Sarcoma; Monophasic Synovial Sarcoma, Perinephric Collection; Complex Renal Cyst; Computed Tomography Imaging.*

INTRODUCTION: Primary renal synovial sarcoma (PRSS) is an aggressive tumor with incidence less than one percent of all adult malignancies. Very few reports have tackled this tumor. REPORT: 36-year-old female, presented with left sided abdominal pain and palpable mass. Initial multiphase Computed Tomography (CT) of kidney showed complex left lower pole renal cyst, with new large complex non-enhancing subcapsular collection in the subsequent CT, which were persistent despite drainage and antibiotic. Fluid cytology revealed no malignancy. Patient underwent left radical nephrectomy in view of persistent subcapsular collection despite drainage and antibiotic, and tissue biopsy showed unexpected diagnosis of monophasic SS. Ifosfamide- and doxorubicin-based chemotherapy regimens was commenced. Surveillance CT showed no recurrence or metastasis. CONCLUSION: PRSS, although uncommon, should be considered, especially in young adults who present with complex cystic renal lesion or persistent perinephric collection. Surgical extirpation followed by ifosfamide- and doxorubicin-based chemotherapy regimens are the treatment of choice.

CONTRAST-ENHANCED MAMMOGRAPHY AND MRI IN BREAST CANCER DIAGNOSIS AND EVALUATION

Kartini Rahmat¹, Thum WQ¹, Farhana Fadzli¹, Wong Yee Voon¹, Lee Sui Cheng¹, Nazimah AB Mumin², Marlina Ramli¹, Anushya V¹, Leong Wai Ling¹

¹*Biomedical Imaging, Faculty of Medicine, Universiti Malaya, Malaysia*

²*Dept of Radiology, Universiti Teknologi MARA, Malaysia*

Background

To review the application and demonstration of preoperative evaluation breast cancer using contrast-enhanced mammography (CEDM) and breast MRI. CEDM has been shown to be non inferior to breast MRI in detecting breast lesions (diagnostic accuracy of 97% and 96%, respectively). This pictorial assay seeks to elucidate its role in diagnostic performance guiding treatment planning and ultimately improving patient outcomes in the management of breast cancer.

Learning Objective(s)

1. Understand the principles and technical aspects of CEDM versus breast MRI in the diagnosis of breast cancer.
2. Recognize the role of CEDM versus breast MRI in evaluating tumour size, extent, and multifocality/multicentricity in breast cancer staging.
3. Evaluate the potential impact of incorporating CEDM as an emerging modality into clinical practice on patient outcomes and treatment strategies.

Imaging Findings or Procedural Techniques

CEDM provides morphological and functional information of malignant lesions similar to breast MRI. Cancer and malignant tumour demonstrate rapid and disorganized growth, which results in increased angiogenesis and permeability.

The leaky vasculature in tumours can be highlighted in CEDM. In CEDM, iodine-based contrast material is injected intravenously two minutes before image acquisition. Subsequently, a pair of low energy (28– 32 kVp) and high energy (45kVp) images are acquired in quick succession while the breast remains compressed. Post-processing of the two images produces the recombined image where glandular tissue is suppressed and contrast uptake in breast lesion is highlighted.

Conclusion

CEDM is useful additional tool to allow improved assessment of Digital Mammography in selected cases. It is comparable to MRI in its ability to detect small lesions often obscured by conventional breast imaging. Further studies are required in the Asian population to further cement its place in the ever growing list of imaging modalities for women.

Figure 1: Case of irregular enhancing mass of a high grade DCIS in the right inner lower quadrant shown in mediolateral oblique view recombined image of CEDM and CE-MRI (axial MIP).

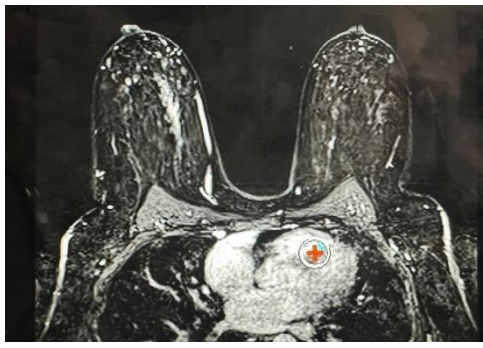
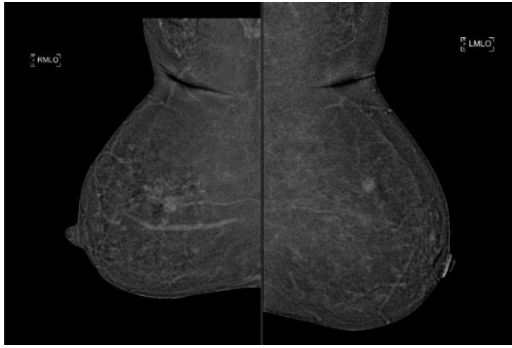
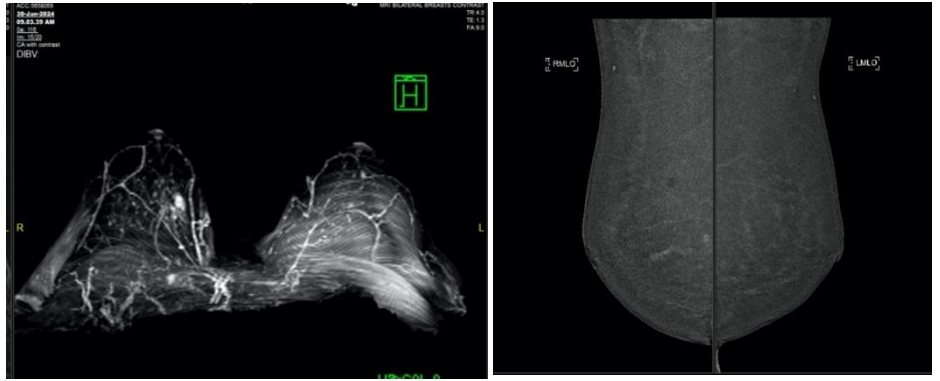


Figure 2. Recombined CEDM images showing enhancement at right upper inner quadrant (DCIS) and left upper outer quadrant (benign) . CE-MRI showed left UOQ enhancing breast lesion and right breast upper inner segmental heterogenous NME.

CHEST WALL DESMOID TYPE FIBROMATOSIS MIMICKING BREAST CARCINOMA - A CASE REPORT

W.A. Firdaus¹, Raihanah Haroon¹, Azaliana Bt Abdul Fuaat²

¹Department of Radiology, Sultan Ahmad Shah Medical Centre (SASMEC @IIUM) Kuantan, Pahang

²Department of Pathology, Sultan Ahmad Shah Medical Centre (SASMEC @IIUM) Kuantan, Pahang

Keywords: *Breast Imaging*

Fibromatoses, also referred to as desmoid tumors; are uncommon soft tissue tumors, which accounts for only 0.2% of breast neoplasms. We report a case of 47-years-old-lady presented with 2-months history of enlarging right breast lump. Mammogram revealed a high-density lesion only seen in MLO view. Ultrasound shows ill-defined lesion at 7-9 o'clock in position.. BIRADs category 4c was given. CT scan and MRI breast showed an irregular lobulated mass that arises from the right pectoralis muscle at the right upper quadrant of the chest wall with area diminished fat plane between the mass with the soft tissue. No enhancement in CT scan, however heterogeneously enhanced in MRI post contrast. In MRI dynamic post contrast curve shows Type 3 curve. Right breast mastectomy was performed due to its local aggressiveness and high rate of recurrence. Imaging is crucial for planning of treatment to delineating the lesion prior to surgical treatment.

A RARE CASE OF URACHAL MUCINOUS CYSTIC NEOPLASM

Ng WL1,3; A. Karim NK1,2

1 Department of Radiology, School of Medical Sciences, Health Campus, Universiti Sains Malaysia

2 Imaging Unit, Advanced Medical and Dental Institute, Universiti Sains Malaysia

3 Department of Radiology, Hospital Raja Permaisuri Bainun

Keywords: *Congenital Urachal Remnant, Urachal Cystic Neoplasm, Midline Abdominal Mass*

Congenital urachal remnant, which results from incomplete involution, predisposes to malignant transformation, predominantly adenocarcinoma. In contrast to adenocarcinoma, mucinous neoplasm of the urachus had a better prognosis if resected completely. Imaging features may overlap with other differential diagnoses and hence affect the management. An ultrasound examination was performed for a 50-year-old gentleman who presented with a lower abdominal mass which revealed a multicystic suprapubic mass with minimal curvilinear wall calcification and no solid component. No solid component nor Doppler signal demonstrated. Subsequent CT as a scan confirmed these findings which further delineated the relation of the mass with the umbilicus as well as the urinary bladder. Laparotomy and tumor excision was performed, confirming the attachment of the mass with the urinary bladder dome as well as extraperitoneal extension via paraumbilical defect. Histopathological examination (HPE) revealed a urachal mucinous cystic neoplasm of low malignant potential. The patient was well post surgery with no history of recurrence.

CANAL OF NUCK CYST: A RARE CAUSE OF INGUINAL SWELLING IN ADULT FEMALES

Nurul Amira, M1, Bushra J2; Nazimah AM3, Yahya MA4

1Department of Radiology, Faculty of Medicine, Universiti Teknologi MARA, Puncak Alam, Selangor, Malaysia,

2Department of Surgery, Faculty of Medicine, Universiti Teknologi MARA, Puncak Alam, Selangor, Country.

Keywords: Canal Of Nuck, Cyst, Ultrasound, CT

Introduction

Canal of Nuck cyst is seldom diagnosed in adult females, especially in Malaysia, with limited local literature on the topic. This case report aims to discuss the computed tomography (CT) features of Canal of Nuck cyst where MRI is unavailable and explore differential diagnoses for inguinal swelling in adult females [1].

Case Report

We present a 41-year-old woman with left inguinal discomfort and swelling. Ultrasound revealed a cystic lesion (**Figure A**), and CT confirmed a well-defined cyst anteromedial to the left femoral vessels (**Figure B**). Surgical exploration revealed a multiloculated cystic mass extending from the internal inguinal ring, confirming the diagnosis of Canal of Nuck cyst.

Conclusion

Although rare in females, cyst of the canal of Nuck should be considered in cases of groin swelling. While ultrasonography and MRI are preferred for evaluation, CT can provide valuable insights, especially when MRI is not accessible, aiding in accurate evaluation and management.

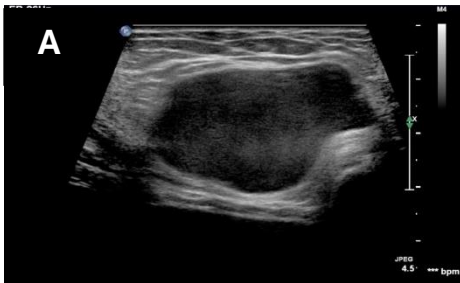


FIGURE A: Transverse grayscale ultrasound of left inguinal demonstrating a well-defined unilocular anechoic lesion with posterior enhancement. No internal vascularity demonstrated on color Doppler.

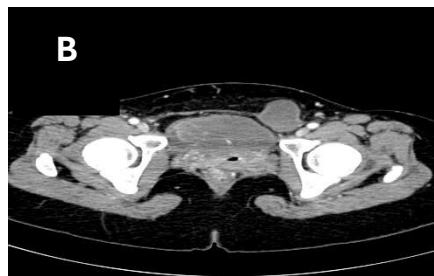

FIGURE B: Contrast enhanced CT Abdomen & Pelvis in axial plane at pelvic region revealing a well-defined, non-enhancing thin-walled cystic lesion anteromedial to the left common femoral vessels. No evidence of solid component, bowel loop or omentum within the lesion. No communication with the peritoneum.

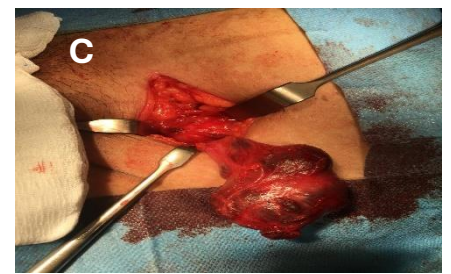

Figure C: Intraoperative photograph of left inguinal revealing an intact multiloculated cystic mass in left inguinal canal.

REFERENCE

1. Brainwood, M., Beirne, G., & Fenech, M. (2020). Persistence of the processus vaginalis and its related disorders. *Australasian journal of ultrasound in medicine*, 23(1), 22–29.

THE CT QUADRATE LOBE FOCAL HOT SPOT SIGN IN SUPERIOR VENA CAVA OBSTRUCTION.

Nabila FM; Mohd Radhwan A

*Department of Radiology, Sultan Ahmad Shah Medical Centre (SASMEC) at IIUM,
Jalan Sultan Ahmad Shah, 25200 Kuantan, Pahang.*

Keywords: *Quadrature Lobe Focal Hot Spot Sign; CT scan; Superior Vena Cava, Obstruction*

“Quadrature lobe focal hot spot sign” refers to a radiological finding seen on contrast-enhanced computed tomography (CT) scans of the liver. Quadrature lobe is the medial segment of left hepatic lobe (segment IV). It was initially observed on ^{99m}Tc sulphur colloid scan of liver as focal area of increased radiopharmaceutical uptake and was diagnostic of superior vena cava (SVC) syndrome. In CT, this sign is characterized by contrast accumulation in segment IV of liver during arterial or early portal venous phases. Contrast enhancement during the arterial phase is often related to increased blood flow and vascularization in certain liver lesions, which can make them stand out and appear as ‘hot spot’ on imaging. Presented herein is our diagnostic experience of an incidental CT ‘Quadrature lobe focal hot spot sign’ in a case of SVC obstruction in an ESRF patient and to discuss the physiological cause and importance of this sign.

GIANT PENILE ELEPHANTIASIS FOLLOWING MULTIPLE CIRCUMCISIONS: A RARE COSMETIC AND FUNCTIONAL COMPLICATION

Muhammad Azri Silmi, A^{1,2}, Noor Diyana, O³, Nor Syahida, Mr²

¹*Department Of Radiology, School Of Medical Sciences, Health Campus, Universiti Sains Malaysia, 16150 Kubang Kerian, Kelantan, Malaysia.*

²*Department Of Radiology, Hospital Sultanah Bahiyah, 05460 Alor Setar, Kedah, Malaysia.*

³*Department Of Biomedical Imaging, Advanced Medical And Dental Institute, Universiti Sains Malaysia, Bertam, 13200 Kepala Batas, Pulau Pinang, Malaysia.*

Keywords: *Giant Penile Elephantiasis, Penile Lymphoedema, Circumcision, Complication*

Lymphoedema of external genitalia can be caused by infection, neoplasm, chronic inflammation or rarely congenital. This report describes a rare case of giant penile elephantiasis in a 50-year-old male who had a history of circumcision twice previously due to phimosis. Ten years after the second circumcision, he presented with progressive penile and scrotal swelling, along with an abnormally-shaped penis likely related to the prior surgical procedures. Magnetic resonance imaging (MRI) was performed to better understand the structural anatomy revealed extensive soft tissue thickening and loss of fascial planes throughout the glans and shaft of the penis, with the glans buried within the thickened tissue. Additionally, similar findings were identified in the scrotal region. This case highlights the potential for rare complication following circumcision, and the importance of considering past surgical history when evaluating patients with penile abnormalities.

ABDOMINAL PAIN WITH A TWIST: A RARE CASE OF OMENTAL TORSION

Dr Nur 'Adlena BA1, Dr Noorasikin BAH2, Dr Siti Aspalekha J3

1Department of Radiology, Kajang Hospital, Selangor, Malaysia, 2Department of Radiology, Kajang Hospital, Selangor, Malaysia, 3Department of Radiology, Kajang Hospital, Selangor, Malaysia

Keywords: *Omental torsion, omental infarction, CT scan, acute abdomen*

A 44-year-old male presented to the emergency department complaining of right upper quadrant pain and was initially diagnosed with perforated gastric ulcer (PGU). Abdominal computed tomography showed a whirling pattern of fatty streaks and vessels within the greater omentum, and surgery confirmed infarction of the omentum secondary to torsion. Because of its rarity and nonspecific clinical features, the diagnosis is seldom made preoperatively. We describe a patient with characteristic CT findings of omental torsion. Preoperative diagnosis is important since conservative management has been suggested and it was confirmed on computed tomography (CT) inferring that imaging plays an important role in identification and management of the disease due to mimic of clinical pictures of acute abdomen which can mislead the diagnosis.

RARE CASE OF GIANT SIGMOID DIVERTICULUM

Low JJ¹, Vithiya S², Siti AH³

¹Radiology Department, Hospital Sultan Ismail, Johor Bahru, Malaysia

Keywords: *Giant Sigmoid Diverticulum*

Colonic diverticulosis is a fairly common disease in elderly patients. However, a solitary giant colonic diverticulum is relatively rare. Herein, we are presenting this case of a 74 years old man who presented with abdominal pain and loose stool for 4 days. His abdominal radiograph showed a central large round air-filled structure in the pelvis. Colonic malignancy with bowel obstruction was suspected. Cross-sectional imaging showed a large air-filled saccular outpouching arising from the sigmoid colon confirming the diagnosis of giant sigmoid diverticulum. No signs of inflammation or perforation seen. Patient was managed conservatively. We are presenting this case for its unique radiological features and as it is the first of its kind in our center.

INTERNAL HERNIA THROUGH BROAD LIGAMENT DEFECT: A RARE CASE REPORT

Livania C¹, Nur Alfalailah MA¹, Fadzrie Azim FD¹

¹*Department of Radiology, Hospital Melaka, Melaka, Malaysia.*

Keywords: *Internal Hernia, Broad Ligament, Intestinal Obstruction*

Broad ligament herniation is rarely reported and constitutes only 4% of all internal hernias. Most internal herniation complicated with strangulation resulting in acute small bowel obstruction. A 45-year-old female, no previous surgical history, presented with intense colicky left iliac fossa (LIF) pain. Upon examination revealed tenderness over the LIF and suprapubic region. Blood test showed leucocytosis. Normal abdominal radiograph. Ultrasound showed ascites with stagnant bowel loops. Subsequently CECT Abdomen showed abnormal cluster of small bowel loops within pouch of Douglas with evidence of obstructed internal hernia and impending ischemia. An emergency laparotomy was performed. Intraoperative findings revealed defect in left broad ligament causing strangulation of small bowel. Bowel resection and left broad ligament hernia repair done. Post operatively patient recovered well. Patients with broad ligament hernia can present with wide spectrum of symptoms, ranging from none to acute bowel obstruction. The diagnosis is challenging with nonspecific clinical and radiographic findings.

References

1. L.C. Martin, E.M. Merkle, W.M. Thompson. Review of internal hernias: radiographic and clinical findings. *AJR Am. J. Roentgenol.*, 186 (2006), pp. 703-717.
2. Abin Sajan, MD, Hazim Hakmi, MD, Daniel W. Griep, BE, Amir H. Sohail, MD, Helen Liu, DO, and David Halpern, MD. Herniation Through Defects in the Broad Ligament. *JSLs*. 2021 Apr-Jun; 25(2): e2020.00112.

DECIPHERING THE PUZZLE: CHALLENGES IN DIAGNOSING CAECAL BASCULE WITH SMALL BOWEL DILATATION.

Jennyfer JL¹, Alex LTL¹

¹*Radiology Department of Hospital Sultan Ismail, Johor Bahru, Malaysia*

Keywords: *Caecal Bascule, Caecal Volvulus, Dilated Caecum, Intestinal Obstruction*

Caecal bascule, a rare subtype of caecal volvulus, involves the anterior folding of the caecum over the ascending colon at a horizontal axis. This condition can lead to complications namely small bowel obstruction (SBO) due to mechanical effects on neighbouring structures or incompetent ileo-caecal valve. Clinical manifestations, including abdominal pain, distension, vomiting, and constipation, closely resemble those of primary SBO. Prompt diagnosis and management are crucial to prevent complications like bowel ischemia or perforation. We present the case of a 65-year-old woman admitted for femur fracture, who developed abdominal distension during her hospital stay, plain radiograph revealed a markedly dilated caecum with dilated small bowels. Subsequent CT confirmed caecal bascule with SBO. She underwent an emergency laparotomy, which confirmed the diagnosis of caecal bascule with small bowel dilation. She subsequently underwent bowel decompression and caecopexy. Recognising this entity in acute abdominal presentations facilitates timely intervention and improved patient outcomes.

SPONTANEOUS HEMORRHAGE OF LEIOMYOMA– A TALE OF RARE LEIOMYOMA COMPLICATION

Nabilah K¹, Fazliza H¹

¹*Department of Radiology, Hospital Sultanah Aminah, Johor Bahru, Malaysia*

Keywords: *Bleeding, Leiomyoma*

Uterine fibroids are common benign tumors in women. Clinical manifestations are well known. Acute complications necessitating emergent surgical intervention are rare. We hereby report a case of 40-year-old female presented with an acute abdomen. CECT Abdomen revealed huge abdominopelvic mass with area of increasing hyperdensities at the lateral aspect of the mass with hemoperitoneum. During emergency exploratory laparotomy, the subserosal vein overlying a uterine fibroid was identified as the source of bleeding. Hemostasis secured by myomectomy. Spontaneous hemorrhage from uterine leiomyoma is extremely rare, but may lead to life-threatening conditions. Therefore, high index of suspicion should be considered in female patients with acute abdominal pain with underlying uterine fibroid to ensure early diagnosis and prompt treatment.

INCIDENTAL FINDING OF LITHOPEDION IN A PATIENT WITH VAGUE PELVIC SYMPTOMS

Muhammad FF¹, Zarifa Z²

Radiology Department, Hospital Tengku Ampuan Afzan, Jalan Tanah Putih, Kuantan, Malaysia

Keywords: *Mummified, Lithopedion, Ectopic Pregnancy.*

Abstract

A lithopedion is a rare phenomenon that results from a missed ectopic pregnancy. This condition is a rare occurrence of only 0.0054% in all gestations. In most cases, these are found incidentally during investigation for abdominal complaints. A 49 year old woman with three previous pregnancies presented with symptoms of abnormal vaginal bleed and abdominal pain. Her last child birth was more than 30 years ago. An ultrasound done by the gynaecology team showed a large calcified mass with hypoechogenicity within. A scheduled Pelvic CT later revealed a bulky uterus and a well-formed extrauterine mummified fetus within the pelvic cavity with no surrounding fat streakiness to suggest acute or chronic infection at the time. This case can serve as a contribution to further understanding this condition and has shown that a mummified fetus can be considered as a differential diagnosis in cases of calcified pelvic lesions among women.

COMPLIANCE OF THE USAGE OF WATER AS NEUTRAL ORAL CONTRAST IN CT ABDOMEN.

Liyana MZ; Mohd Nazlin K; Huzairah AP; Nurul Shamira MA

Department of Radiology, Hospital Sungai Buloh.

Keywords: Water, CT Abdomen, Neutral contrast

Background

Computed Tomography (CT) Abdomen is one of the most frequently done CT scan in our department apart from CT Thorax and CT Pelvis as they reveal many important findings especially in post trauma patient. Prior to CT scan, patient will be given intravenous, oral and rectal contrast according to the indication of examination. Oral administration of positive contrast agents containing Barium Sulphate or Iodine has become a standard practise in abdominal CT. However, many studies have shown that use of water as oral contrast give equivalent delineation of the bowel and similar detection rate for intestinal pathologies as positive contrast agent. Benefits such as water is tasteless and odourless while gastrograffin has unpleasant taste. Water is easily available too. The aim of this study is to achieve >95% usage of water as oral contrast in CT abdomen and the objective is to improve compliance to use water as oral contrast in CT Abdomen instead of positive contrast.

Methodology

The study is done retrospectively using random sampling of 150 patients during pre-intervention, 120 patients for first cycle and 100 patients for second cycle. Exclusion criterias are perforation, fistula and anastomotic leak cases.

Results

Results for pre-intervention only 28% used water, 1st cycle improves to 89% while 2nd cycle 99% used water as oral contrast. The outcome has led to patient and staff satisfactions also cost saving.

Conclusion

There is increase compliance to usage of water as neutral oral contrast compared to first cycle.

IMAGING FINDINGS OF PRIMARY PRIMITIVE NEUROECTODERMAL TUMOUR OF THE LIVER - A CASE REPORT

Philip TWI1, Ng WL2

Radiology Department, University Malaya Medical Centre, Lembah Pantai, 59100. Kuala Lumpur, Malaysia.

Keywords: *Primitive Neuroectodermal Tumor, Extraskkeletal Ewing Sarcoma, Focal Hepatic Lesion.*

Primitive neuroectodermal tumor (PNET) is a member of the Ewing's sarcoma family that is a highly aggressive tumour with poor prognosis. Although PNETs can occur in numerous solid organs especially from the musculoskeletal system, a primary hepatic PNET is extremely rare. We have a 77-year-old female, whose initial CT liver 5 phase showed an arterially enhancing segment 4 mass that was treated as hepatocellular carcinoma. Patient underwent selective internal radiation therapy (SIRT). First CT follow-up post-SIRT showed favourable response from the tumour. 6 months later, the patient presented with worsening abdominal pain. A repeat CT liver 5 phase showed a new large segment 6 liver lesion. Biopsy was performed for both the segment 4 and 6 liver lesions and histological diagnosis of primitive neuroectodermal tumour of the liver was made. In this case report, we discuss the serial imaging findings of PNET of the liver.

LIFE-THREATENING PULMONARY COMPLICATIONS FROM BREAST FILLER INJECTION

Noor Shahida MP, Jolene LAH, Quah SY

Department of Radiology, Hospital Pulau Pinang, Malaysia.

Keywords: *Hyaluronic Acid, Injectable Filler, Diffuse Alveolar Haemorrhage*

Breast augmentation is a common aesthetic procedure with various techniques have been described, including injectable filler such as hyaluronic acid(HA). However, life-threatening pulmonary complications from HA injection is not well known. We hereby report a case of a young patient who developed diffuse alveolar haemorrhage after receiving unlicensed HA filler injection. She presented to us with acute breathlessness. On questioning, she disclosed prior history of breast filler injections, with the last injection done on day of presentation. CT scan prior to ICU admission showed bilateral multifocal consolidations with surrounding ground glass opacities, predominantly in peripheral location. Bronchoscopy showed minimal hemorrhages at both lower lobes. She was treated symptomatically and responded well to steroid treatment. Interval CT at 2 months showed complete resolution of lung changes. This case report is to create awareness among medical practitioners regarding this possible complication, given the rising popularity of breast augmentation procedures among the public.

WUNDERLICH SYNDROME: A CASE REPORT

Retriani S¹, Sri I²

1 Radiology Department, Pelita Harapan University, Karawaci, Tangerang, Indonesia, 2Radiology Department, Medistra Hospital, Gatot Subroto, Jakarta, Indonesia.

Keywords: *Wunderlich Syndrome, Angiomyolipoma, Flank Pain*

Wunderlich syndrome is a rare condition that is potentially life-threatening spontaneous renal hemorrhage into subcapsular and perirenal spaces. A 39-year-old woman presented with sudden severe colic flank pain. Abdominal ultrasound revealed a heterogeneous echogenicity mass occupying the left kidney's superior pole, suspected to be an Angiomyolipoma. Contrast-enhanced CT scan showed a mixed density mass (solid, fat, and blood components) in the superior pole, measuring approximately 111 mm x 86 mm, with perirenal blood collection suggesting a partial rupture of an Angiomyolipoma. Surgery and histopathology confirmed our suspected diagnosis of a spontaneous rupture of Angiomyolipoma. Wunderlich syndrome typically presents with sudden severe abdominal pain due to the spontaneous rupture of Angiomyolipoma and bleeding into the subcapsular and/or perirenal space. Diagnosis usually involves imaging studies like ultrasound, CT, or MRI. In this case, immediate medical attention and imaging confirmed the diagnosis, underscoring the importance of prompt intervention for successful management.

RENAL VASCULAR ABNORMALITIES IN A MISSED RENAL MASS

Tan GX¹, Soon YY²

*Radiology Department, Hospital Sultan Idris Shah Serdang,
Selangor, Malaysia*

Keywords: *Arteriovenous Malformation, Renal Cell Carcinoma*

Introduction

Differentiating between renal arteriovenous malformations (AVM) from malignancy may be challenging due to similar clinical and imaging findings.

Abstract

We report a case of a 55 years old female presented with painless hematuria. Ultrasound showed hypoechoic left kidney mass with dilated, tortuous vessels and increased colour Doppler. Multiphase CT revealed multiple tortuous vessels in arterial phase in a background of relatively hypoenhancing renal parenchyma with early drainage into the IVC. Initially reported as renal AVM but upon multidisciplinary discussion concluded the hypoenhancing areas as a renal mass. Left radical nephrectomy shows a very vascular mass and HPE confirmed clear cell carcinoma tumour with renal sinus invasion, distant metastasis to left adrenal and distal pancreas, with left renal vein thrombus.

Conclusion

These conditions are great mimickers of each other and can coexist together. Detailed image interpretation and a high index of suspicion is needed to ensure accurately monitoring with proper treatment.

PLANTAR FASCIITIS TREATED WITH AUTOLOGOUS WHOLE BLOOD

KENNETH SHEAH

Musculoskeletal Radiology And Intervention, Imaging Consulting, Singapore

Keywords: *Autologous Whole-Blood; Corticosteroid; Methylprednisolone; Placebo; Plantar Fasciitis*

Interest in biological treatment in plantar fasciitis and plantar fascial tears has increased in recent years. This is a case report of a 30 year old footballer with plantar facial partial rupture treated with autologous whole blood injection, and managed weight bearing. Imaging eight weeks after initial treatment reveals bridging of tear gap, with corresponding improvement clinically. This is a significant finding, as autologous whole blood injection is cheaper than the more popular platelet rich plasma, and can be used as an alternative in selected patients.

MORPHOLOGY AND MORPHOMETRY EVALUATION OF ADULT COCCYX WITH MULTIDETECTOR COMPUTED TOMOGRAPHY IN SULTAN AHMAD SHAH MEDICAL CENTRE @IIUM

Nur AS¹, Ahmad RMR¹, Karimah HAA²

¹Department of Radiology, Sultan Ahmad Shah Medical Centre (SASMEC) @International Islamic University Malaysia (IIUM), ²Kuliyah of Medicine, IIUM, Jalan Sultan Ahmad Shah, Kuantan, Malaysia.

Keywords: *Coccyx (Cy), Morphology, Morphometry, Multidetector Computed Tomography (MDCT)*

Background

The coccyx is often considered functionally insignificant, resulting in a lack of data on its normal morphology and morphometry in vivo. This study aims to assess the morphology and morphometry of the coccyx among Malaysian adults who underwent MDCT at SASMEC @IIUM.

Methodology

A cross-sectional study was conducted on 300 adult CT images from November 2021 to November 2022. The morphology of the coccyx (vertebral count, segmental number, intercoccygeal joint fusion, and coccyx type) and morphometric measurements (sacrococcygeal angle, intercoccygeal angle, curved index of coccyx, and sacrum) were evaluated.

Results

The most common coccyx vertebral count was four with average number of coccygeal segments was three, with intercoccygeal fusion predominantly at the last intercoccygeal joint, mainly at the Cy3/Cy4 level. The most prevalent coccyx type was II. In terms of coccyx morphometry, the curved index of the coccyx and sacrum as well as mean sacrococcygeal angle and intercoccygeal angle reveals straighter and shorter coccyx in females compared to males. Significant gender differences were observed in the coccygeal vertebral count, number of coccygeal segments, curved index of the coccyx, sacrococcygeal angle, and intercoccygeal angle. However, no significant gender disparity was found across coccyx types or curved index of the sacrum.

Conclusion

Our study reveals common anatomical variations in coccyx morphology and morphometry within the Malaysian population which has comparable prevalence with other studies. These findings are essential for recognizing and understanding anatomical variations in sacrococcygeal anatomy among different ethnicities, which can further facilitate the diagnosis and identification of risk factors associated with coccydynia.

ASSOCIATION BETWEEN MEAN PLATELET VOLUME AND HEMORRHAGIC TRANSFORMATION AMONG PATIENTS WITH CEREBRAL INFARCTION IN DR. JOSE N. RODRIGUEZ MEMORIAL HOSPITAL AND SANITARIUM

Regina Joyce, JOAQUIN P.

Department of Radiology, Dr. Jose N. Rodriguez Memorial Hospital and Sanitarium, Saint Joseph Avenue, Tala, Caloocan City 1427, Philippines

Keywords: *Ischemic Stroke, Hemorrhagic Transformation, Mean Platelet Volume, Prognostic Marker, Retrospective Study*

Background

Ischemic stroke remains a significant cause of morbidity and mortality worldwide, with hemorrhagic transformation representing a common complication. Platelet function plays a crucial role in the pathogenesis of ischemic stroke, with mean platelet volume (MPV) emerging as a potential marker of platelet reactivity.

Methodology

Data were collected from medical records of patients diagnosed with cerebral infarction between January 2022 and January 2023. MPV measurements were obtained from complete blood count tests, while cranial CT scans were reviewed to identify hemorrhagic transformation. Statistical analyses, including the Kruskal-Wallis test, were employed to assess the association between MPV and hemorrhagic transformation.

Results

Descriptive analyses revealed a significant correlation between elevated MPV levels and the presence of hemorrhagic transformation ($p < 0.05$). Patients with hemorrhagic transformation exhibited higher MPV values compared to those without (mean MPV: 11.5 fL vs. 10.2 fL, respectively). Subtypes of hemorrhagic transformation, including petechial hemorrhage and parenchymal hematoma, were observed, contributing to the overall burden of hemorrhagic transformation.

Conclusion

This study provides compelling evidence of a significant association between elevated MPV levels and hemorrhagic transformation among patients with acute cerebral infarction. MPV may serve as a valuable predictive biomarker for identifying patients at higher risk of hemorrhagic transformation and adverse outcomes in ischemic stroke. Integration of MPV measurements into routine clinical assessment may facilitate risk stratification and personalized management strategies for ischemic stroke patients. Further prospective studies are warranted to validate these findings and explore the therapeutic implications of modulating platelet function in ischemic stroke management.

DIAGNOSTIC EFFICACY OF DUAL ENERGY CT FOR DIFFERENTIATING INTRACEREBRAL HEMORRHAGE FROM IODINATED CONTRAST MATERIAL STAINING

Authors: *Shadab Kanwal, Misbah Durrani, Zainab Nasir, Ummarah Kamran*

Keywords: *Dual Energy Ct, Cerebral Haemorrhage, Contrast Staining*

Purpose: To evaluate the efficacy of dual energy CT in early differentiation of intracerebral hemorrhage from iodinated contrast material staining.

Background:

Iodine staining and intracerebral bleed is a common phenomenon after Mechanical thrombectomy. Differentiating them is important so that appropriate antiplatelet therapy can be initiated.

Methodology:

Patients with acute stroke who had undergone mechanical thrombectomy were evaluated post procedural on dual energy CT to differentiate contrast material staining from haemorrhage. Follow up imaging after 24 and 48 hours on conventional CT were used as the standard of reference.

Inclusion criteria: All post MT patients of any age, male or female, with or without co morbidities, will be included in the study

Sample size: 50

Results:

Mixed images obtained with Dual energy CT showed intra-parenchymal hyperattenuation in 46/50 patients. Out of these 46 hyperattenuations, 31 were classified as iodine staining, 7 were classified as hemorrhage and 8 were classified as a mixture of hemorrhage and contrast material. The sensitivity, specificity, and accuracy of DECT in the identifying hemorrhage was calculated as 100% ,93% and 95% respectively. The only cases where DECT failed to correctly identify the hyperattenuation was in the presence of parenchymal calcification and metallic streak artifact.

Conclusion:

DECT allows an early and accurate differentiation between cerebral hemorrhage and iodine staining after Stroke intervention

LOEFFLER ENDOCARDITIS WITH VENTRICULAR LAMINAR THROMBUS

Fakhriah MB¹, Mubarak MY²

¹ Department of Radiology, SASMEC @IIUM Jalan Sultan Ahmad Shah, 25200, Kuantan, Pahang, Malaysia.

² Department of Radiology, Hospital Tengku Ampuan Afzan, Kuantan, Pahang, Malaysia.

Keywords: *Loeffler's Endocarditis, Hypereosinophilic Syndrome, Eosinophilic Endocarditis*

Eosinophilic endocarditis or Loeffler's endocarditis, is an uncommon restrictive cardiomyopathy associated with eosinophilia and endomyocardial fibrosis. Loeffler's endocarditis can lead to serious complications, such as progressive heart failure, systemic thromboembolic event or arrhythmia. We reported case of a 37-years-old gentleman, unknown medical illness, presented with heart failure symptoms. A full blood count showed bicytopenia with leukocytosis and marked eosinophilia. Echocardiography revealed masses within the ventricles and minimal global pericardial effusion. MRI cardiac imaging showed biventricular thrombi in the absence of regional wall motion abnormalities, mesocardial and subendocardial late gadolinium enhancement (LGE) involving the right and left ventricles. This patient was treated with intravenous methylprednisolone, Warfarin and Imatinib. The subsequent cardiac MRI demonstrated resolved thrombi in the biventricular regions. Hence, we emphasize the utility of cardiac magnetic resonance imaging in providing accurate diagnostic information and detecting early changes.

ATYPICAL PROSTATE METASTASIS: A CASE SERIES

Muhammad Syazwan Mohd Zain^{1,2}, Iqbal Hussain Rizuana^{1,2}

¹Department of Radiology, Faculty of Medicine, Universiti Kebangsaan Malaysia,

²Hospital Canselor Tuanku Muhriz, Jalan Yaacob Latif, Bandar Tun Razak, Kuala Lumpur.

Keywords: *Lytic Bone Metastasis, Prostate Carcinoma, Prostate Metastasis, Osteoblastic Prostate Metastasis*

Prostate cancer can metastasize to several organs, most commonly to bone, distance lymph node, liver and thorax. Osseous metastasis of can manifest as osteolytic, osteoblastic or mixed of both. Case report 1: 65-year-old male who with initial presentation discomfort in the left hip and buttock region following a minor fall. Investigations revealed right anterior third rib and costochondral junction, left iliac bone and acetabulum expansile lytic lesion, associated with soft tissue components. Case report 2: 54-year-old male patient who with underlying acinar adenocarcinoma of the prostate, presented with left hip and inguinal pain. Investigations show lytic and sclerotic bone lesions of the left hip with large surrounding soft tissue mass. These case series emphasises the significance of identifying osteolytic metastatic osseous prostate cancer, despite the higher incidence of the osteoblastic form. It is important for radiologist to recognise that metastatic prostate cancer can manifest as lytic or sclerotic bone lesions.

BROAD LIGAMENT SOLITARY FIBROUS TUMOR MIMICKING HUGE OVARIAN NEOPLASM: A RADIOLOGICAL PERSPECTIVE

Suraini, MS, Siti Nabilah MM, Norafida, B

Department Radiology, Faculty Medicine and Health Sciences, Universiti Putra Malaysia, Selangor Darul Ehsan. Malaysia

Keywords: *Solitary Fibrous Tumor, Ovarian Neoplasm, Pelvic Mass, Broad Ligament*

Solitary fibrous tumors (SFT) arise from mesenchymal tissue, and are typically rare, with pelvic occurrences being particularly uncommon. Therefore, pelvic solitary fibrous tumors may be misinterpreted as ovarian neoplasm in women. The features of SFT in images obtained from CT or MRI scans are not distinctive, thus necessitating the need for further investigation. The diagnosis is confirmed by characteristic positive immunohistochemical staining for CD34 and STAT6, and negative staining for S-100 (Ginat et al, 2011). This case report underscores the significance of considering this diagnosis when encountering a woman with a solid pelvic mass, normal tumor markers, and an absence of ascites.

ATYPICAL MANIFESTATION OF ACUTE APPENDICITIS MASQUERADING AS MALIGNANT LESION ON CT IMAGING

Nurizdiha Shukor^{1,2}, Rafidah Zainon³, Fajariah Beevi²

1 Department of Radiology, School of Medical Sciences, Health Campus, Universiti Sains Malaysia, 16150 Kubang Kerian, Kelantan, Malaysia.

2 Department of Radiology, Hospital Sultan Abdul Halim, 225, Jalan Lencongan Timur, Bandar Amanjaya, 08000, Sungai Petani, Kedah

3 Department of Biomedical Imaging, Advanced Medical and Dental Institute, Universiti Sains Malaysia, Bertam, 13200 Kepala Batas, Pulau Pinang, Malaysia.

Keywords: *Appendix, Acute Appendicitis, Malignant, Abdominal Mass, CT Abdomen Pelvis*

Acute appendicitis is a common surgical emergency typically presenting with classic clinical features and imaging findings. Circumstances in which radiologically revealed features are consistent with neoplasm but post-operative pathology finds no evidence of neoplastic is rare. We describe a case of 23-year-old woman who presented with unusual presentation of acute appendicitis characterized by computed tomography (CT) findings mimicking malignancy. The patient presented with vague abdominal pain and abdominal mass. Patient has no typical symptoms and signs of acute appendicitis. CT findings revealed suspicious mass-like lesion in right lower quadrant, raising concerns for malignancy. The intra-operative findings and post surgical histopathological diagnosis did not concur with the radiological diagnosis and instead demonstrated findings compatible with acute appendicitis without neoplastic change. This case highlights the importance of considering atypical presentations of appendicitis, particularly when imaging findings mimic malignancy. Prompt recognition and surgical intervention are crucial to prevent complications and improve patient outcomes.

GALLSTONE ILEUS WITH PROXIMAL SMALL BOWEL PERFORATION, A RARE COMPLICATION CARRYING SIGNIFICANT RISK OF INCREASED MORTALITY, NOT TO BE MISSED.

Cheng CW¹, Izzat H¹, Nor Azalina MS¹

¹Radiology Department of Sultan Ismail Hospital, Johor Bahru, Malaysia.

Keywords: Gallstone ileus, Duodenal perforation

Presentation of gallstone ileus accounts for 0.5% of all gallstone disease, carrying significant average mortality of 18%. Mechanical obstruction is the prominent presentation with rare cases having distal bowel perforation, compounding the risk of mortality. Proximal small bowel perforation, however, is exceedingly rare with only a handful of reported cases in literature. We are presenting a case of a 74-year-old gentleman with history of Hartman's procedure of perforated sigmoid diverticulum coming in with 2-day history of acute intestinal obstructive symptoms associated with vague abdominal pain. Initial suspicions pointed to adhesions being the aetiology however subsequent Computed Tomography (CT) scan demonstrates findings of a cholecystoenteric fistula communicating with the D1 segment with mid ileal obstructing Gallstone complicated with large perforation at distal D2 with retroperitoneal collection. Midline laparotomy was performed confirming findings consistent with the CT images.

A RARE PRESENTATION: SIGMOID VOLVULUS AS THE CAUSE OF INTESTINAL OBSTRUCTION IN A YOUNG FEMALE

Nurizdiha Shukor^{1,2}, Rafidah Zainon³, Nur Ahida Md Ahir² Lim Yi Wei²

1 Department of Radiology, School of Medical Sciences, Health Campus, Universiti Sains Malaysia, 16150 Kubang Kerian, Kelantan, Malaysia.

2 Department of Radiology, Hospital Sultan Abdul Halim, 225, Jalan Lencongan Timur, Bandar Amanjaya, 08000, Sungai Petani, Kedah

3 Department of Biomedical Imaging, Advanced Medical and Dental Institute, Universiti Sains Malaysia, Bertam, 13200 Kepala Batas, Pulau Pinang, Malaysia.

Keywords: *Sigmoid Volvulus, Intestinal Obstruction, Colonoscopy, Bowel Decompression*

A sigmoid volvulus occurs when part of the colon segment twists upon its mesentery. It is associated with old age, multiple co-morbidities, and male sex. It is an uncommon problem in young age population, and is rarely considered a diagnosis in this group. We present a rare case of sigmoid volvulus that occurred in a healthy young female. A 22 year old female presented with a sudden onset of left hypochondriac pain and no bowel output for 2 days and associated with multiple episodes of vomiting. Physical examination revealed a distended abdomen. Plain abdominal radiograph and Computed tomography (CT) of the abdomen was consistent with sigmoid volvulus. Successful colonoscopic decompression was performed with flatus tube inserted. This case report emphasizes the importance of clinicians maintaining a sigmoid volvulus as a rare, yet important differential when approaching abdominal pain in young patient.

PRIMARY RENAL LYMPHOMA PRESENTING AS BILATERAL RENAL PELVIS SOFT TISSUE LESIONS- A RARE CASE

Nor Azlan Mohd Zin^{1,2}, Erica Yee Hing^{1,2}

1 Department of Radiology, Faculty of Medicine, University Kebangsaan Malaysia

2 Hospital Canselor Tuanku Muhriz, Jalan Yaacob Latif, Bandar Tun Razak, Kuala Lumpur, Malaysia

Keyword: Renal Pelvis Tumor; Primary Renal Lymphoma; Obstructive Uropathy; Synchronized Upper Renal Tract Tumor; Positron Emission Tomography Imaging.

Introduction

Primary renal pelvis lymphoma is uncommon with few cases reported.

Report:

A 65 years-old, investigated for bilateral obstructive uropathy detected on Ultrasonography (USG). Computed tomography (CT) shows bilateral renal pelvis enhancing soft tissue lesions with no enlarged lymph nodes. Retrograde Intrarenal Surgery (RIRS) and Uteroscopy (URS) does not shows any lesion within the urinary tract while cytology was negative for malignancy. Repeated CT shows increasing in size of bilateral renal pelvis lesions with encasement of the renal hilar vessels and collecting system. Positron Emission Tomography Scan (PET) shows high metabolic uptake within this soft tissue lesions. Biopsy of the right renal pelvis lesion revealed marginal zone lymphoma. Bone Marrow Aspiration Terphine Biopsy (BMAT) shows no lymphomatous infiltration. Patient was started on chemotherapy and surveillance PET CT shows good treatment response.

Conclusion:

Although uncommon, the diagnosis of lymphoma should be considered in the case of renal pelvis soft tissue lesion.

RUPTURED ABDOMINAL AORTIC ANEURYSM (AAA) AS A RARE CAUSE OF STROKE

Yun Hui, Ng¹, I. B. A. Bakar²; Y. Yaacob³

1 Imaging Centre, Institut Jantung Negara, Jalan Tun Razak, Kuala Lumpur, Malaysia

2 Radiology Department, International Islamic University Malaysia, Kuantan, Pahang, Malaysia

3 Radiology Department, Hospital Canselor Tuanku Muhriz UKM, Cheras, Kuala Lumpur, Malaysia

Keywords: *Abdominal Aortic Aneurysm Rupture; Altered Mental Status; Cerebrovascular Attack; Ischemic Stroke*

Introduction

Ruptured abdominal aortic aneurysm is a life-threatening surgical emergency.

Report:

69 year old man came with acute stroke as the first presentation of rupture abdominal aortic aneurysm (AAA). Patient presented with fall with altered mental status, aphasia, generalised bilateral weakness and hypotension. CT Brain plain showed hypodensity in the left frontal region with loss of normal grey white matter differentiation, feature suspicious of an acute left MCA infarct. Bedside ultrasound reviewed AAA. CTA Aorta showed ruptured infrarenal abdominal aortic aneurysm with large left retroperitoneal hematoma. No evidence of active bleeding. Blood transfusion was given. Family opted conservative management in view of mortality rate is high. DIL/NAR issued. Patient died.

Conclusion:

AAA rupture are clinically indistinguishable especially when it comes with non-specific symptoms and signs that often leads to misdiagnosis. Having a wide differential diagnosis in terms of acute stroke is vital to ensure prompt diagnosis and effective management.

COMPLICATION FROM CONSUMPTION OF 'KING OF FRUIT': A CASE REPORT OF SMALL BOWEL OBSTRUCTION DUE TO DURIAN SEED IMPACTION

Lim G1, Azham A2

1 Radiology Department, Hospital Sultanah Nora Ismail, Batu Pahat 83000 Johor, Malaysia.

2 Radiology Department, Hospital Putrajaya, Wilayah Persekutuan Putrajaya 62250, Malaysia.

Keywords: *Ingestion, Impaction, Durian, Seed, Bezoars, Ileum, Small Bowel Obstruction*

Introduction:

Acute mechanical intestinal obstruction (AMIO) occurs when intestinal contents are blocked, requiring emergency surgical intervention. AMIO accounts for about 20% of emergency surgical procedures.

Case Presentation:

61-year-old man presented with abdominal distention, no flatus or bowel output for 4 days, and 1 day of abdominal pain and vomiting. Examination showed a soft, distended abdomen with sluggish bowel sounds. Abdominal radiograph indicated small bowel obstruction. CT scan revealed an intraluminal oval hyperdense mass (1.9x1.8x3.7 cm) in the mid ileum. Exploratory laparotomy identified and removed a durian seed causing the obstruction, 70 cm from the ileo-caecal junction, followed by bowel repair. The patient had consumed durian a week earlier.

Conclusion:

Foreign bodies rarely cause small bowel obstruction without prior abdominal surgery or adhesions. Typically, they pass through the small bowel without issue. Durian seeds and laminated gallstones may appear similar on CT. Recent ingestion history aids diagnosis but not always available.

UTILIZATION OF 3D MRI IN DIAGNOSING EARLY CAESAREAN SCAR ECTOPIC PREGNANCY: A CASE REPORT

Tan HL^{1,2}, Roudhotul Nadiah MH², Nasuha MK², Ch'ng LS^{1,2}

¹*Department of Radiology, Faculty of Medicine, Universiti Teknologi MARA, Sungai Buloh, Selangor, Malaysia.*

²*Department of Radiology, Hospital Al-Sultan Abdullah, Universiti Teknologi MARA Puncak Alam, Selangor, Malaysia.*

Keywords: *Pregnancy, Scar Ectopic, 3D MRI*

Caesarean scar ectopic pregnancy, a rare occurrence, involves the implantation of a pregnancy within the scar tissue from a previous cesarean section. This condition can pose significant risks to maternal health, including uterine rupture, severe bleeding, and potential mortality. Diagnosis often relies on sonography, with Magnetic Resonance Imaging (MRI) serving as a crucial tool, particularly when sonographic findings are inconclusive, as it is a potentially life-threatening condition that requires prompt and appropriate management. However, in early pregnancy stages, especially when the fetal pole is minimally developed, identifying ectopic pregnancies on 2D MRI can pose challenges. Herein, we present a case of an early caesarean scar ectopic pregnancy, where sonographic findings were equivocal, and MRI, particularly 3D MRI, played a pivotal role in facilitating diagnosis.

BEYOND THE CONVENTIONAL: EXPLORING RADIOLOGICAL APPROACHES IN DIAGNOSING CERVICAL PREGNANCY

Devina Y¹, Irwan TR², Vincent L^{1,3}, Sariningsih H^{4,5}, Ratri W⁵, Zannuba AN², Lina C^{1,3}

¹Department of Radiology, Faculty of Medicine, Public Health, and Nursing, Universitas Gadjah Mada, Yogyakarta, Indonesia

²Department of Obstetrics and Gynecology, Faculty of Medicine, Public Health, and Nursing, Universitas Gadjah Mada, Yogyakarta, Indonesia

³Radiology Research and Training Office, Universitas Gadjah Mada, Yogyakarta, Indonesia

⁴Dharmais Cancer Hospital, Jakarta, Indonesia

⁵Doctoral Program, Faculty of Medicine, Public Health, and Nursing, Universitas Gadjah Mada, Yogyakarta, Indonesia

Keywords: *Cervical Pregnancy, Ectopic Pregnancy, Magnetic Resonance Imaging, Transvaginal Ultrasound*

Cervical pregnancy, a rare ectopic pregnancy in the cervical canal, requires prompt diagnosis to prevent severe complications. We present a case of a 32-year-old woman with a positive pregnancy test four months earlier and was diagnosed with a blighted ovum, leading to curettage. Persistent vaginal bleeding occurred post-curettage, causing severe anemia with a hemoglobin of 4 g/dL. Transvaginal ultrasound (TVUS) showed no intrauterine gestational sac but detected a mass suspected as cervical leiomyoma. Upon referral to our hospital, β -HCG was 935 mIU/mL. Magnetic resonance imaging (MRI) revealed a heterogeneous cervical lesion with no viable fetus and no trophoblastic invasion, suggesting retained product of conception from cervical ectopy pregnancy. Patients received methotrexate and β -HCG level steadily dropped to 14 mIU/mL. This case highlights that TVUS can misinterpret cervical lesions, necessitating advanced imaging modalities. MRI provides detailed anatomical views, enabling early diagnosis and proper treatment for ectopic pregnancy.

MISDIAGNOSED LEFT ADNEXAL MASS REVEALED AS *PERITONEAL SPLENOSIS*

Jeyaraaj J

Department of Radiology, University Malaya Medical Centre, Kuala Lumpur, Malaysia.

Keywords: *Splenosis, Adnexal Mass*

We present a compelling case in a 46-year-old nulliparous female with a history of splenectomy following a motor vehicle accident (MVA) presenting with suprapubic discomfort. Physical examination revealed a palpable lower abdominal mass. Blood investigations yielded normal results, indicating no acute systemic complications. CT abdomen-pelvis exhibited an enhancing left adnexal mass closely associated with the uterus, raising concerns of gynaecological pathology. No splenic tissue was visualized in the left hypochondrium, consistent with the patient's history of splenectomy. Diagnostic laparoscopy revealed a left adnexal mass likely of gynaecological origin, prompting a biopsy. Histopathological examination of the left adnexal mass revealed benign splenic tissue consistent with the diagnosis of splenosis. This case emphasizes the importance of considering peritoneal splenosis in the differential diagnosis of adnexal masses despite a history of splenectomy. Our report contributes to the expanding knowledge base surrounding this rare entity, emphasizing the significance of meticulous diagnostic evaluation to avoid misinterpretation and facilitate appropriate patient management.

PERITONEAL PARADOX: TUBERCULOSIS MASQUERADING AS ABDOMINAL MALIGNANCY

Ramanathan SRM

Department of Radiology, KPJ Damansara, Petaling Jaya, Selangor, Malaysia

Keywords: *Abdominal Tuberculosis*

22-year-old male smoker presented with abdominal pain, weight loss, and diarrhoea. He denied chronic cough or contact with tuberculosis-infected individuals. Clinical examination revealed tenderness and guarding in the right iliac fossa, while lung examination was unremarkable. Laboratory findings showed elevated neutrophils and C-reactive protein (CRP) levels. Initial management presumed peritonitis with suspicion of underlying malignancy, prompting a CT abdomen, which revealed diffuse thickening of the peritoneum with moderate ascites. Concurrently, a chest radiograph showed left upper lobe pneumonia, raising the possibility of pulmonary tuberculosis. A laparoscopic biopsy of the thickened omentum revealed peritoneal tuberculosis. This journey highlighted the difficulty in distinguishing it from abdominal malignancies due to similar symptoms. This case underscores the diagnostic complexities and stressing the need for vigilant diagnosis and balanced treatment approaches.

QUANTITATIVE MEASUREMENT OF MYELIN IN NEURODEGENERATIVE DISEASE

Nadiyah M¹, Norafida B²

¹Department of Radiology, Hospital Sultan Idris Shah, Serdang, Selangor, Malaysia,

²Department of Radiology, Hospital Sultan Abdul Aziz Shah, Serdang, Selangor, Malaysia.

Keywords: Myelin Correlated Volume, Neurodegenerative Disease, MRI, MDME

Background

Neurodegenerative disease is an umbrella term for adult-onset extensive variety of diseases which typically progresses slowly and is accompanied by variable gradual neurological deterioration. Few common neurodegenerative diseases include Alzheimer's and Parkinson's diseases. Often imaging findings of neurodegenerative disease are subtle and equivocal. Currently, with the emerging new techniques of myelin detection and quantification using MRI, several studies have shown that these techniques are beneficial in the diagnosis of neurodegenerative diseases. Thus, the purpose of this study is to obtain the quantitative measurement and analysis of myelin in neurodegenerative disease such as Alzheimer's and Parkinson's diseases.

Methodology

This is a retrospective study of patients that underwent MRI Brain neurodegenerative protocol with MDME included as one of the sequences. Quantitative analysis will automatically be done using the Synthetic MRI application where the myelin correlated volume among other datasets will be obtained and analyzed. These sets of data will then be plotted in graphs in comparison to a normal population database readily available within the application.

Results

In this small sample pilot study, we have found that lower myelin correlated volume is seen in the clinical and/or radiological suspected or confirmed cases of neurodegenerative disease patients.

Conclusion

Although the limitations of this study include a small sample size, the quantitative measurement and analysis have shown evidence of lower myelin correlated volume in neurodegenerative disease, thus should encourage more substantial and elaborated studies in future.

**PYLEPHLEBITIS MIMICKING A MESENTERIC MASS: A RARE COMPLICATION OF PERFORATED APPENDICITIS
WITH UNIQUE RADIOLOGICAL FINDINGS**

Low JJ¹, Vithiya S², Siti AH³

¹Radiology Department, Hospital Sultan Ismail, Johor Bahru, Malaysia

Keywords: *Pylephlebitis, Appendicitis*

Pylephlebitis is a rare complication of intra abdominal infection most commonly seen secondary to diverticulitis, appendicitis and necrotising pancreatitis. It typically appears as a filling defect within the mesenteric veins leading to abscess formation or bowel ischemia. We present this case of a 47 years old man with fever and abdominal pain 1 month post open appendicectomy for perforated appendicitis. He was in sepsis and the abdomen was soft but tender at the epigastric region. Infective markers were markedly raised. Cross sectional imaging performed showed a large mesenteric mass following the distribution of the superior mesenteric and portal veins with thrombosis of these vessels. Based on imaging a differential diagnosis of pylephlebitis or mesentery mass was given. Biopsy of this mass returned as inflammatory tissue confirming the diagnosis of pylephlebitis. Patient was treated conservatively. We are presenting this case for its unique radiological findings.

PRIMARY NON-HODKIN'S LYMPHOMA MIMICKING CHOLANGIOCARCINOMA

MOHD AS, Anushya V.

Bio-Medical Imaging Department, University Malaya Medical Centre, Jalan Prof Diraja Ungku Aziz, Kuala Lumpur, Malaysia.

Keywords: *Cholangiocarcinoma, Liver Lymphoma, CT Liver*

Primary hepatic lymphoma (PHL) is an uncommon variant of non-Hodgkin lymphoma originating primarily within the liver. A 60-year-old gentleman presented with jaundice for one month with severe headache and diplopia. On examination, he is deep jaundice, with complex ophthalmoplegia over the right eye with impaired third, fourth and sixth nerves. Per abdomen, noted hepatomegaly. The liver function test was deranged. CT brain shows asymmetry thickening of the cavernous sinus and subsequent MRI revealed cavernous sinus thrombosis. CT liver demonstrates numerous ill-defined hypodense lesions in liver with intrahepatic duct dilatation, suspicious of cholangiocarcinoma. Percutaneous trans biliary drainage was done. HPE showed high-grade non-Hodgkin B cell lymphoma. The patient was started on dexamethasone and hydrocortisone and planned for chemotherapy, however deteriorated in ward and expired. Although PHL is a rare diagnosis, it should be considered when there are solitary or multiple liver lesions in a middle-aged patient with normal tumor marker.

HEPATIC ANGIOMYOLIPOMA MIMICKING HEPATOCELLULAR CARCINOMA

Vrshni Menaka RSN¹, Lau CC¹, Nik Shah Hizan²

- 1. Department of Radiology, Hospital Universiti Sains Malaysia, 15100 Kubang Kerian, Kelantan, Malaysia*
- 2. Department of Radiology, Hospital Raja Perempuan Zainab II, 15000 Kota Bharu, Kelantan, Malaysia*

Keywords: *hepatic angiomyolipoma, hepatocellular carcinoma, computed tomography*

Hepatic angiomyolipoma is infrequently encountered as compared to renal angiomyolipoma. Furthermore, it is difficult to distinguish a hyper vascular hepatic angiomyolipoma from hepatocellular carcinoma from imaging, hence it poses a challenge for radiologists in providing the provisional diagnosis. We present a case of an asymptomatic patient incidentally found to have liver lesion during a routine follow-up ultrasound which subsequently led to a multiphase liver computed tomography (CT). The initial preoperative CT scan concluded the liver lesion as hepatocellular carcinoma whereby the patient underwent surgical resection and the biopsy yielded angiomyolipoma. In conclusion, it is important to differentiate between hepatic angiomyolipoma and hepatocellular carcinoma as the treatment that follows for both these diagnoses vary greatly whereby angiomyolipoma can be managed conservatively and conversely for hepatocellular carcinoma it is dealt by surgical resection or chemotherapy. Contrast magnetic resonance imaging (MRI) in a noncirrhotic liver may misdiagnose angiomyolipoma as hepatocellular carcinoma.

MESENTERIC FIBROMATOSIS: A LITTLE KNOWN AND RARE AGGRESSIVE BENIGN TUMOR

Nur Syafiqah MR 1, Mohd Hazeman Z 1

1Department of Radiology, Hospital Sultan Abdul Aziz Shah, UPM, Serdang, Malaysia.

Keywords: *Mesenteric Fibromatosis; Desmoid Tumor; Peritonism*

Mesenteric fibromatosis or desmoid tumor, is a rare benign tumor originating from fibrous tissue proliferation, commonly affecting young adults. Clinical presentations vary widely, often manifesting with abdominal symptoms. Here, we describe a 34-year-old man presenting with peritonism symptoms, incidentally, discovered to have a mesenteric mass on contrasted CT Abdomen. Surgical exploration unveiled extensive involvement, posing a risk of bowel ischemia, prompting biopsy for confirmation. Subsequent CT scans revealed postoperative complications, including a necrotic ruptured mass and intraabdominal collections, managed with drainage and antibiotics. Despite risks, surgical resection remained the primary treatment, albeit with potential complications due to the mass's proximity to the Superior Mesenteric Artery. Radiotherapy or chemotherapy were not suitable due to slow tumor growth. While mesenteric angiography with angioembolization was offered as an alternative, the patient opted for surveillance through repeated imaging. This case highlights the diverse clinical features, its potential complications and available management options.

UTERINE DEHISCENCE: A RARE BUT RELEVANT POSTPARTUM COMPLICATION THAT DEMANDS ATTENTION

Nurizdiha Shukor^{1,2}, Rafidah Zainon³, Tan Cheng Chong², Nurhasyida Mohd Rashid²

1 Department of Radiology, School of Medical Sciences, Health Campus, Universiti Sains Malaysia, 16150 Kubang Kerian, Kelantan, Malaysia.

2 Department of Radiology, Hospital Sultan Abdul Halim, 225, Jalan Lencongan Timur, Bandar Amanjaya, 08000, Sungai Petani, Kedah

3 Department of Biomedical Imaging, Advanced Medical and Dental Institute, Universiti Sains Malaysia, Bertam, 13200 Kepala Batas, Pulau Pinang, Malaysia.

Keywords: *Uterine Dehiscence, Postpartum, Caesarean Section, Computed Tomography*

Uterine dehiscence, although rare, presents a critical postpartum concern necessitating heightened clinical awareness. Uterine dehiscence in the postnatal period still remains elusive due to its vague presentation. An incorrect diagnosis or a delay in diagnosis can lead to unnecessary interventions or delay the management of patient symptoms. It possess substantial maternal morbidity and mortality risks. This particular case demonstrate a 32 year old woman underwent emergency lower segment caesarean section for fetal distress. On the 7th postpartum day, she developed heavy amount of foul smelling greyish watery vaginal discharge. Computed tomography revealed pelvic collection with suspicious of dehiscence at lower segment caesarean section incision site. Emergency laparotomy revealed a dehiscence of the lower uterine segment incision. The incision was repaired and the postoperative course was uneventful. Despite its infrequency, uterine dehiscence warrants meticulous consideration within obstetric practice to mitigate its potentially catastrophic consequences.

INCIDENCE OF RETROAORTIC RENAL VEIN IN PATIENTS WITH ACUTE FLANK PAIN

Abdulla Aljehani Aa1, Hamed Alharbi Ha1, Bander Alshomarani Ba1, Refah Alqahtani Ra1, Rogya Bamoharram Rb1

1radiology, Ministry Of Health – Jeddah First Health Cluster – King Abdulaziz Hospital, Almahjar Street, Jeddah, Saudi Arabia

Keywords: *Posterior Nutcracker Syndrome, Retroaortic Renal Vein, Renal Colic*

Background

The left retroaortic renal vein is a rare anatomical variation where the left renal vein takes a posterior course behind the abdominal aorta before joining the inferior vena cava. Unlike the typical anterior course of the left renal vein, the retroaortic course may lead to venous congestion, hinder renal blood flow, and potentially cause symptoms like flank pain, hematuria or varicocele.

Methodology

For the patient who present to the emergency department complaining of flank pain. We retrospectively evaluated plain KUB CT scans done in our radiology department at King Abdulaziz General Hospital between January 2016 and December 2022. Exclusion criteria include, recent history of trauma, known of renal stones or known for UTI infection/inflammatory process. CT scan performed in two scanners (GE128 slice slice scanner and Siemens Somatom 64 slice thickness). The images are obtained at 2.5 mm slice thickness with sagittal and coronal reformats. Positive cases are considered in patient with left-sided retroaortic renal vein with absent of renal stone. The CT scans studies were reviewed and interpreted by three radiologists.

Results

Among a total of 1592 patients, 62.2% were male, with an average age of 47.86 ± 16.78 years. Within this population, 6.34% exhibited a positive retroaortic left renal vein, while 42.39% were diagnosed with urinary tract stones. Furthermore, 2.7% of the patients had both urinary system stones and retroaortic renal vein.

Conclusion

Identifying left-sided retroaortic renal vein in patients experiencing flank pain or renal colic, can assist physicians in achieving precise diagnoses.

A RARE CASE OF METACHRONOUS SECOND PRIMARY PENILE MALIGNANCY IN A CONFIRMED PROSTATE CANCER

Nur Marini Zainal^{1,2}, Iqbal Hussain Rizuana^{1,2}, Basri Johan Jeet Abdullah³, Xeng Inn Fam^{4,2}.

¹Department of Radiology, Faculty of Medicine, Universiti Kebangsaan Malaysia,

²Hospital Canselor Tuanku Muhriz, Jalan Yaacob Latif, Bandar Tun Razak, Kuala Lumpur.

³Department of Radiology, Assunta Hospital, Jalan Templer, Petaling Jaya, Selangor, Malaysia.

⁴Department of Urology, Faculty of Medicine, Universiti Kebangsaan Malaysia, Kuala Lumpur, 56000, Malaysia.

Keywords: Penile Cancer; Prostate Cancer; Radiology; Cancer Of Penis; Metastatic Prostate Cancer.

Second primary malignancy (SPM) in prostate cancer patients are rare. SPM was more commonly involving lung and bronchus (24.90%). We described a case of a 73-year-old gentleman smoker presented with lower urinary tract symptoms. Initial computed tomography urography, showed prostatomegaly with penile urethra calcifications. Histopathological examination from the prostate biopsy revealed poorly differentiated adenocarcinoma with differentials of prostatic ductal adenocarcinoma or urothelial carcinoma. CT staging showed prostate malignancy with seminal vesicle, urinary bladder, right distal ureter, lower rectal infiltration with a few right lung nodules, suspicious of lung metastases. After 2 years of treatment with hormonal therapy, patient developed new symptoms of ulcerative penile swelling. CT shows features of penile malignancy, as well as mediastinal lymphadenopathies and lung nodules. HPE showed squamous cell carcinoma of the penis. To the best of our knowledge, this is the first reported case of secondary primary malignancy in prostate cancer in Malaysia.

FREE SILICONE BREAST INJECTIONS: DIAGNOSTIC IMAGING CHALLENGES

Nur Sakinah Abd Rasad¹, Cheah Sin Dee², Bashiron Binti Jamaludin¹, Wong Yi-Li (Grace)¹

¹ Radiology Department, Hospital Pulau Pinang, Jalan Resideni, 10990 George Town, Pulau Pinang

² Surgery Department, Hospital Pulau Pinang, Jalan Resideni, 10990 George Town, Pulau Pinang

Keywords: *Free Silicone Injections, Breast Imaging, Breast MRI, Mammogram, Breast Ultrasound*

Due to adverse effects, free silicon breast injections have been banned in most countries. However, it is still illegally performed by non-certified personnel due to low cost. The occasional patient may present weeks to decades from the time of injections with complications which range from mild to moderate. A 56-year-old lady with history of breast fillers 10 years ago presented with a right breast lump for a year. Free silicone injections stimulate foreign body reactions, leading to granulomatous formations i.e. siliconomas. Siliconomas appear as high-density lesions on MMG and cystic globules surrounded by echogenicities with posterior shadowing (“snowstorm” appearance) on ultrasound, mimicking or obscuring true lesions. The ACR BI-RADS recommends contrast-enhanced MRI as both a screening and diagnostic tool. The objective of this case study is to compare the appearance of siliconomas on different imaging modalities and illustrate differentiation between true breast lesions from siliconomas on MRI.

ADVANCE MRI APPROACH TO DETECT RESIDUAL BREAST MALIGNANCY: A CASE REPORT

Rifki B¹, Siti D¹, Devina Y¹, Lina C¹

¹Department of Radiology, Faculty of Medicine, Public Health and Nursing, Universitas Gadjah Mada, Yogyakarta, Indonesia.

Keywords: *DWI, MRI, DCE, Breast, Oncology*

Residual breast malignancy lesions present a challenge for radiologists to evaluate using conventional MRI sequences due to their small size. Advanced MRI techniques, such as dynamic contrast enhancement and both conventional and synthetic diffusion-weighted imaging with high b values, have shown significant clinical value. In this case report, we present the case of a 36-year-old female who underwent a follow-up MRI examination after breast-conserving surgery for invasive ductal carcinoma. The initial MRI showed a suspicious small lesion with intermediate restriction that was not clearly visible. However, the synthetic DWI with high b values demonstrated clear visibility of the lesion. Additionally, the DCE sequence revealed a plateau kinetic curve indicative of malignancy. Combining these advanced MR techniques might provide valuable information to evaluate residual breast malignancy.

NAVIGATING THE NEXUS: PRIMARY ANGIOSARCOMA OF THE BREAST: IMAGING INSIGHTS AND HISTOPATHOLOGICAL CORRELATION

Muhammad Nabil MK¹, Khoo SZ¹, Khatrulnada MS¹, Ahmad Fazlin N², Che Jamal Abdillah CA³

1 Department of Radiology, Hospital Sultan Haji Ahmad Shah, Temerloh, Pahang, Malaysia.

2 Department of Pathology, Hospital Sultan Haji Ahmad Shah, Temerloh, Pahang, Malaysia.

3 Department of Surgery, Hospital Sultan Haji Ahmad Shah, Temerloh, Pahang, Malaysia.

Keywords: *Angiosarcoma, high density lesion, heterogenous hypoechoic mass*

Angiosarcoma, a rare aggressive tumour arises from endothelial cells lining vascular channels, poses diagnostic challenges especially when arising in the breast as primary angiosarcoma. We present a case of a patient with left breast swelling for 7 years, progressively worsening in the last 6 months, associated with distended veins and hyperpigmented skin. Initial mammogram unveiled a large lobulated high-density mass within the left breast with mild architectural distortion, nipple retraction and skin thickening. Complementary ultrasound reveals a large lobulated heterogenous hypoechoic mass with minimal vascularity on colour doppler signal - prompting a BIRADS 5 highly suspicious mass. Subsequent CT demonstrates a heterogeneously enhancing mass occupying the entire left breast with no calcification or fat component within. Due to its similar course of presentation with other primary breast tumour, this case underscores the importance of multimodal imaging as well as histopathological correlation to disentangle the diagnostic conundrum and expedite appropriate management.

DIAGNOSIS CHALLENGE: SMALL BOWEL PERFORATION FROM FISH BONE INGESTION IDENTIFIED BY RADIOLOGICAL IMAGING

Cheng Cw¹, Vithiya S¹, Siti Ah¹

¹Radiology Department Of Sultan Ismail Hospital, Johor Bahru, Malaysia.

Keywords: *Fish Bone Ingestion, Small Bowel Perforation*

Fish bone is one of the most commonly ingested foreign bodies. While most instances pass spontaneously, complications such as perforation of the gastrointestinal tract can occur. The occurrence however is rare and accounts for < 1 % of cases, at which it poses a significant challenge in diagnosis as the clinical manifestations are non-specific and are subjected to the site of perforation. Cross sectional imaging plays a significant role in helping with the diagnosis. We are presenting a case of a 46-year-old immunocompromised woman with non-specific right iliac fossa pain and tenderness which started at the epigastric region. Initial clinical suspicions pointed to acute appendicitis and diverticulitis being the aetiologies. Cross sectional imaging however showed an intraluminal linear hyperdense object piercing through a markedly thickened small bowel loop with adjacent pneumoperitoneum suggestive of small bowel perforation secondary to foreign body ingestion. Emergency laparotomy performed confirmed the diagnosis.

HISTOLOGICALLY PROVEN HIGH GRADE GLIOMA SHOWING HIGH SIGNAL ACTIVITY AMIDE PROTON TRANSFER WEIGHTED MRI: A CASE SERIES.

Norfatin S1, Nur A1,2, Anani A3.

1Department of Radiology, School of Medical Sciences, Universiti Sains Malaysia, 16150 Kubang Kerian, Kelantan, Malaysia.

2Hospital Universiti Sains Malaysia, Universiti Sains Malaysia, Health Campus, Jalan Raja Perempuan Zainab 2, 16150 Kubang Kerian, Kelantan, Malaysia.

3Department of Pathology, School of Medical Science, Health Campus, Universiti Sains Malaysia, 16150 Kubang Kerian, Kelantan, Malaysia.

Keywords: *Magnetic Resonance Imaging, Amide Proton Transfer (APT) Weighted, High Grade Glioma*

Gliomas are the most common primary tumors of the central nervous system in adult. Current gold standard for gliomas' diagnosis and therapeutic decision relies on the histopathology. However, the heterogeneous characteristics of gliomas and their capacity for diffuse infiltration causing difficulty in sampling the highest-grade portion of tumor accurately. There have been limited case series reported on histologically proven high grade gliomas showing high APT signal activity. We present three patients with high APT signal activity and histologically proven to be high grade gliomas. Case 1 proven as glioblastoma multiforme, case 2 is proven to be anaplastic ependymoma and case 3 is proven as anaplastic astrocytoma. APT imaging is a novel non-invasive MRI technique which provides molecular information predominantly based on the amide protons in cellular proteins and peptides in the intracellular and extracellular spaces. Higher peptide and protein concentrations usually result from higher cell density in high grade gliomas.

DEVELOPMENT OF VASOGENIC CEREBRAL EDEMA AFTER CT MYELOGRAM WITH NONIONIC CONTRAST

Fatima Mubarak

Radiology Department, Aga Khan University Hospital, Karachi, Pakistan

Keywords: *Vasogenic Edema, CT, Myelogram, Non-Ionic Contrast*

Vasogenic edema is a very rare complication of CT myelogram. A 42-year-old female known case of diabetes, hypertension, focal segmental necrotizing glomerulonephritis, and permanent pacemaker in situ for ASD secundum underwent myelogram. Within less than twelve hours she developed altered sensorium and decreased consciousness. Contrast-enhanced CT brain was performed which showed diffuse effacement of cortical sulci with poor gray-white matter differentiation. There was crowding at the foramen magnum with evidence of tonsillar herniation. Diagnosis of CT myelogram-induced cerebral edema was made. The patient received mannitol along with steroid pulse therapy. There was interval resolution of cerebral edema and tonsillar herniation on follow up CT brain. Five doses of pulse therapy were given, and after a five-day admission and observation the patient was discharged in stable condition. We are reporting this case so that clinicians are familiar with this uncommon complication of CT myelogram to start early management for better patient outcome.

LYMPHOMATOSIS CEREBRI: A DIAGNOSTIC DILEMMA

Fatima Mubarak

Radiology Department, Aga Khan University Hospital, Karachi. Pakistan

Keywords: *Lymphomatosis, Cerebri, Dilemma*

Background

Lymphomatosis cerebri (LC) is a rare manifestation of primary central nervous system lymphoma (PCNSL) with only a few cases reported in the literature, appearing as diffuse infiltrating process rather than a solitary mass. It is a non-Hodgkin's type of lymphoma and is usually of the B-cell type origin. We intend to report this unique case of LC which came across as a diagnostic challenge.

Methodology

A 53-year-old gentleman presented with complaints of two episodes of seizures 24 h apart followed by postictal confusion for 10–15 min. He underwent multiple MRI scans and underwent a biopsy of the lesion which reported infection, but he did not benefit from the treatment.

Result

The imaging was reviewed, suspicion of LC was raised and a review of histopathology was requested which later confirmed primary CNS lymphoma.

Conclusion

LC is a rare but established manifestation of PCNSL which mimics multiple other conditions. Understanding of the imaging pattern is important in making the diagnosis and differentiating it from other mimic conditions.

DIABETIC FIBROUS MASTOPATHY MASQUERADING AS BREAST MALIGNANCY

See ST¹, Laili Suriani AL¹

¹Radiology Department, Hospital Pakar Sultanah Fatimah Muar, Jalan Salleh, Muar, Malaysia DFM

Keywords: *Diabetic Fibrous Mastopathy, Breast Cancer*

Diabetic fibrous mastopathy (DFM) is a rare benign entity in patients with longstanding diabetes mellitus. Its clinical presentation as a painless breast lump and imaging findings may mimic malignancy. Thus, histopathology examination (HPE) is required to confirm the diagnosis. This case reports a 42 years old diabetic female, who presented with painless left breast lump for 1 month. She has no axillary lymphadenopathy or constitutional symptoms. Her cousin has breast cancer and the patient had history of taking oral contraceptive pill for 6 months. Mammogram showed left periareolar focal asymmetry, no associated architectural distortion or calcifications. Her breast ultrasound revealed a suspicious irregular, wider-than-tall mass with posterior shadowing at the corresponding region. Ultrasound guided biopsy was performed and HPE showed features of diabetic mastopathy with no evidence of malignancy. This report highlights DFM as a benign breast condition, which is usually non-specific on mammogram, suspicious on ultrasound and requires pathological diagnosis.

LYRE SIGN – WHERE SCHWANNOMA MIMICS A CAROTID BODY TUMOUR.

Fatin NJS¹, Hilwati H¹, Norliana DMA¹, Masaany M², Wong PY³

1/ Radiology Department, Hospital Al-Sultan Abdullah, Universiti Teknologi MARA, Malaysia,

2/Otorhinolaryngology Department, Hospital Al-Sultan Abdullah, Universiti Teknologi MARA, Malaysia

3/ Pathology Department, Hospital Canselor Tuanku Muhriz, Universiti Kebangsaan Malaysia, Malaysia

Keywords: *Lyre Sign, Splaying Of Carotid Bifurcation, Schwannoma, Carotid Body Tumour*

Neural crest cell tumours are rare and diverse. They include schwannomas, benign nerve sheath tumours derived from Schwann cells, as well as paragangliomas or carotid body tumours, neuroendocrine tumours derived from the neural crest cells of the autonomic nervous system. We describe a parapharyngeal neck schwannoma mimicking a carotid body tumour in terms of characteristic vascular displacement. Carotid body tumours cause splaying of internal and external carotid arteries resulting in the classic appearance of Lyre sign on imaging. However, postoperative histologic examination confirmed a schwannoma and ruled out a carotid body tumour. This case highlights another cause of splaying of the carotid bifurcation other than carotid body tumours. It also discusses the relationship between parapharyngeal neck schwannomas and carotid body tumours to carotid bifurcation on imaging.

TUBERCULOMA – A MIMICKER OF POSTERIOR FOSSA MASS IN YOUNG ADULT

Mohd As, Nadia F.

Bio-Medical Imaging Department, University Malaya Medical Centre, Jalan Prof Diraja Ungku Aziz, Kuala Lumpur, Malaysia.

Keywords: *Tuberculoma, Posterior Fossa Mass, Children.*

Tuberculomas are uncommon intracranial manifestations of tuberculosis, typically presenting as space-occupying lesions. A 20-year-old woman with a history of pulmonary tuberculosis (completed anti-TB treatment) presented with a four-month history of headaches and double vision for one month. MRI showed multiple thick-walled rim-enhancing cystic lesions at the left cerebellum with hypointense signals on T1W, T2W and FLAIR sequences with no restricted diffusion or blooming artefacts. A diagnosis of left cerebellar tuberculoma was reported. Intra-operative findings demonstrated a thick fibrous intra-axial lesion over the left cerebellum. Samples were sent for histopathological examination, consistent with tuberculoma. Direct culture grew acid-fast bacilli (*Mycobacterium tuberculosis* complex). The patient was then started on anti-tuberculous medications for 12 months and was subsequently followed-up in clinic. In conclusion, T2W hypointense signal is useful for diagnosing a focal brain parenchymal mass as a tuberculoma. This pathology must be considered when treating patients in high endemic TB areas.

ARTERY OF PERCHERON INFARCTION: A CASE REPORT

Yogambigai B¹, Anas T²

*1, 2 Radiology Department, Hospital Sultan Abdul Aziz Shah UPM,
Persiaran Mardi UPM, Serdang, Selangor*

Keywords: *Artery Of Percheron, Infarct, Bilateral Thalami Infarction*

Artery of Percheron (AOP) is a rare anatomical variant which arises from the posterior cerebral artery (PCA). AOP infarction is uncommon and with various clinical presentation, the diagnosis relies on imaging findings. We present a rare case of AOP infarct in our centre, in which a 68 year old gentleman with underlying multiple comorbid presented with unresponsiveness. Non-contrast CT brain done in a private institution revealed no abnormalities. Urgent MRI Brain was then performed in our centre which showed areas of restricted diffusion at bilateral thalami, suggestive of acute infarct. The contrasted BB sequence showed stagnant sign at branch of right PCA with corresponding faintly opacified vessel on MRA sequence, likely to be AOP. The variable clinical manifestation and negative findings in standard imaging of CT poses limitation in early diagnosis of AOP infarct. Hence early MRI is vital to identify AOP infarct, particularly in patients with reduced consciousness state.

OMENTAL TORSION, AN UNACCUSTOMED MIMICKER OF ACUTE APPENDICITIS

Sarah J, Faizah M

Affiliations: Department of Radiology, Hospital Tuanku Jaafar Seremban, Negeri Sembilan, Malaysia

Keywords: *Omental Torsion, Inguinoscrotal Hernia*

Omental torsion is one of the rare causes of acute abdominal pain with an incidence of 0.0016 – 0.37% with 4 out of 1000 in patients admitted as appendicitis. The causes can be primary or secondary. In primary omental torsion, it occurs in the absence of any associated or secondary intra-abdominal pathology. Secondary omental torsion, on the other hand is associated with conditions such as tumours, cysts, internal or external herniation, foci of intra-abdominal inflammation and postsurgical wound. Clinical presentation is resemblant to acute appendicitis. Reported cases describe the classical signs as concentric linear strands in the omentum representing the “whirl” sign. However, surgical exploration remains the definitive gold standard for intraoperative diagnosis and therapeutic management.

THE MISSING PIECE OF A BLEEDING PUZZLE

May Foo Tse Ling^{1,2}, Noor Khairiah A. Karim³, Jeyaletchumy A/P Annamalai²

1 Department of Radiology, School of Medical Sciences, Health Campus, Universiti Sains Malaysia, 16150 Kubang Kerian, Kelantan, Malaysia.

2 Department of Radiology, Hospital Raja Permaisuri Bainun, 30450 Ipoh, Perak, Malaysia.

3 Department of Biomedical Imaging, Advanced Medical and Dental Institute, Universiti Sains Malaysia, Bertam, 13200 Kepala Batas, Pulau Pinang, Malaysia.

Keywords: *Obscure Gastrointestinal Bleeding, Small Bowel, Jejunal Ulcer, CT Enterography.*

Overt obscure gastrointestinal (GI) bleeding refers to visible bleeding from source not identifiable on endoscopy. A previously well 42-year-old lady initially presented with fluid overload symptoms secondary to end stage kidney disease. She subsequently developed haematemesis and fresh melaena requiring several blood transfusions. Multiple endoscopy and mesenteric computed tomography (CT) angiography were performed but failed to locate the bleeding source despite on-going GI bleed. She developed haemorrhagic shock requiring intensive care. A multiphase CT enterography was later performed demonstrating contrast extravasation and pooling in the proximal jejunum. She underwent emergency laparotomy surgery. Intraoperatively, she was found to have a jejunal ulcer, and histopathological examination confirmed to be ulceration with granulation tissue. She recovered fully with no further GI bleed. Primary jejunal ulcer is a rare cause of lower GI bleeding and remains a diagnostic challenge. CT enterography is helpful in facilitating accurate diagnosis, thus enabling prompt surgical intervention.

UNLOCKING SOLUTIONS: THE CRUCIAL ROLE OF EMBOLIZATION IN MANAGING BLEEDING COMPLICATIONS IN AML WITH ACUTE PANMYELOSIS AND MYELOFIBROSIS

Suaydiy,O¹, Bayhaqi,NA²

¹Resident of Radiology Specialist Study Program, Brawijaya University – Saiful Anwar Hospital. Malang, Indonesia

²Radiology Department, Brawijaya University– Saiful Anwar Hospital, Malang, Indonesia

Keywords: *Trans Arterial Embolization, Acute Panmyelosis with Myelofibrosis, Uterine Bleeding*

Introduction

Acute Panmyelosis with Myelofibrosis (APMF) is a rare-aggressive form of AML, with bleeding manifestations ranging from petechiae to life-threatening haemorrhages. Interventional radiology has emerged as important adjunctive approach that facilitates targeted vascular occlusion with minimal morbidity.

Report

27 year-old woman with AML and APMF presented recurrent and intractable menometrorrhagia for more than 6 months needing multiple blood transfusion. CT Scan revealed dilatation and tortuous bilateral uterine artery, possibly as the culprit of bleeding. Pre embolization DSA confirmed dilatation of bilateral uterine artery, subsequently embolized using 500-700 micron PVA leading to blushing reduction by 90%. On day 4 of follow-up shows uterine bleeding cessation. However, Patient had episode of melena and was resolved with medical treatment at day 5. Patient was discharged on day 15 after embolization.

Conclusion

Interventional radiology plays an important role in managing recurrent uterine bleeding manifestations of APMF, offering minimal invasive techniques and improving patient outcomes.

PERCUTANEOUS BIOPSY OF RETROPHARYNGEAL LESION; APPROACH AND STRUCTURES TO AVOID

Nasibah MOHAMAD NM1,2, Gayathri LETCHUMANAN GL1,2, Mohd Shafie ABDULLAH MSA1,2, Norhafiza LAZIM NL3

1Department of Radiology, School of Medical Sciences, Universiti Sains Malaysia;

2Department of Radiology, Hospital Universiti Sains Malaysia, Kubang Kerian, Kelantan;

3Department of Otorhinolaryngology-HNS, Universiti Sains Malaysia.

Keywords: *Biopsy, Ct-Guidance, Head And Neck*

Introduction

Retropharyngeal space is a potential space posterior to pharyngeal mucosal and anterior to prevertebral space, from the skull base to the T4 level. The deep head and neck spaces are tricky for biopsy, given the delicate anatomy of the region, including nerves, vessels and salivary glands. We would like to report a percutaneous retropharyngeal mass biopsy case and the available approaches and essential structures to avoid during puncture.

Case report

A 25-year-old male presented with difficulty in swallowing. Oral examination revealed medialisation of the right tonsil. Contrast-enhanced computed tomography (CECT) of the neck showed a right retropharyngeal mass. We proceeded with a CT-guided percutaneous biopsy using a paramaxillary approach. The histopathological examination came back as lymphoid hyperplasia.

Conclusion

CT-guided percutaneous deep neck space biopsy is considered safe and effective. Prerequisite knowledge of anatomy and suitable approaches are mandatory to ensure patient safety and avoid complications.

TWO BECOME ONE: A DILEMMA BETWEEN SOFT TISSUE SARCOMA AND MALIGNANT PHYLLODES TUMOR

Regina Joyce, JOAQUIN P.

Department of Radiology, Dr. Jose N. Rodriguez Memorial Hospital and Sanitarium, Saint Joseph Avenue, Tala, Caloocan City 1427, Philippines

Keywords: *CT: Computed Tomography; MRI: Magnetic Resonance Imaging; NCCN: National Comprehensive Cancer Network; PT: Phyllodes Tumor*

This case report presents a diagnostic challenge between soft tissue sarcoma and malignant phyllodes tumor in a 41-year-old female with a large anterior chest wall mass. Biopsy revealed spindle cell neoplasm, with considerations include high-grade phyllodes tumor and soft tissue sarcoma. The CT imaging findings are large, multilobulated, complex mass with heterogenous enhancement and intrinsic coarse calcifications. There is associated sclerotic and erosive changes of the sternum. Multiple bilateral pulmonary, subpleural and fissural nodules are likewise seen which are likely metastasis. Aforementioned findings cannot differentiate between soft tissue sarcoma and malignant phyllodes tumor. Treatment typically involves surgical excision with wide margins, but chemotherapy may be necessary for metastatic disease. Due to the rarity of both conditions, limited data and imaging constraints pose challenges. Ultimately, despite imaging and histopathologic findings, a definitive diagnosis remained elusive, highlighting the complexities of managing such case.

**NAVIGATING THE CURVE: TORTUOUS VERTEBRAL ARTERY INDUCING NEURAL FORAMINA NARROWING
CAUSING CERVICAL RADICULOPATHY.**

Jennyfer JL¹, Alex LTL¹

¹Radiology Department of Hospital Sultan Ismail, Johor Bahru, Malaysia

Keywords: *Vertebral Artery, Cervical Radiculopathy, Neural Foramina Narrowing*

Cervical radiculopathy is common amongst the world's population, giving rise to symptoms ranging from mild to debilitating caused by compression in the spinal cord or neural foramina through various aetiologies. Therefore, the treatment differs in each patient depending on the cause. We present a case of a 41-year-old lady, suffering from left upper limb numbness since childhood and recent upper back pain, who was managed conservatively. Subsequent cervical spine MRI showed no evidence of significant disc prolapse but on careful scrutinisation, it revealed a tortuous left vertebral artery causing narrowing of C4/C5 neural foramina, abutting the left C5 nerve root. Such cause for radiculopathy is uncommon, as a result, these findings are often unnoticed and may go unreported. This signifies the importance of including vascular abnormalities as differentials in patients with radiculopathies as it bears significant implications in the patient's management.

A RARE CASE OF DIEULAFOY LESION IN A MIDDLE AGED WOMAN.

THEEBASHINII TT1 / SITI ASPALEKHA SA2

1department Of Radiology, Kajang Hospital, Jalan Semenyih, Kajang, Selangor 2department Of Radiology, Kajang Hospital, Jalan Semenyih, Kajang, Selangor

Keywords: *Gastrointestinal, Bleeding, Hematochezia, Dieulafoy, Small Bowel, Vascular.*

Dieulafoy lesion was described by French surgeon in 1898 as a series of arterial based lesions. Its a rare congenital cause of non-variceal upper gastrointestinal haemorrhage. They are most commonly found in the stomach (70%). We present a 26 year old lady with sudden onset of hematochezia, anemic symptoms, hypotensive and tachycardia with Hb of 6.8. Urgent OGDS was inconclusive. CT Angiography Abdomen noted focal contrast extravasation at ileum in the left hypochondrium consistent with acute haemorrhagic event. Urgent laparotomy found a polypoidal lesion within the small bowel which was bleeding and hence wedge resection was done. Histopathological examination revealed a polypoid lesion measuring 4 x 3 x 3mm arising from the mucosa which was consistent with enlarged submucosal blood vessel consistent with Dieulafoy lesion. Although rare, Dieulafoy lesion should be considered in middle aged population presenting with lower gastrointestinal bleeding. It can be life threatening without prompt intervention.

ISOLATED SINONASAL CRANIOPHARYNGIOMA PRESENTED AS LEFT NASAL CAVITY MIXED CALCIFIED AND CYSTIC LESIONS WITH NO SUPRASellar COMPONENT - A RARE CASE.

Nor Azlan Mohd Zin^{1,3}, Amali Ahmad¹, Erica Yee Hing^{2,3}

1 Department of Radiology, Hospital Kuala Lumpur

2 Department of Radiology, Faculty of Medicine, University Kebangsaan Malaysia

3 Hospital Canselor Tuanku Muhriz, Jalan Yaacob Latif, Bandar Tun Razak, Kuala Lumpur, Malaysia

Keyword: *Infrasellar Craniopharyngioma; Sinonasal Tumor; Adamantinomatous Craniopharyngioma; Motor Oil Cyst.*

Introduction:

Isolated sinonasal craniopharyngioma is a very rare benign tumour which less than 30 cases reported.

Report:

18 year-old, female presented with 1 year history of worsening left nasal blockage, epistaxis and left periorbital swelling. Nasal scope shows left nasal fungating mass with easily bleed. Computed Tomography (CT) shows left nasal cavity heterogenous enhancing calcified soft tissue lesion with ethmoidal sinuses erosion. On Magnetic Resonance Images (MRI), it shows mixed signal intensity represent calcified component and microcystic 'motor oil cyst' with no orbit, sella or suprasellar involvement. Patient undergo endoscopic tumour excision which histopathology shows Adamantinomatous type craniopharyngioma. Post-surgery surveillance MRI shows no evidence of tumour recurrence.

Conclusion:

Sinonasal Adamantinomatous type craniopharyngioma although is very rare, in the young adult who presented with unresolved nasal blockage, this disease has to be considered. Surgical resection is the solely treatment with close follow up needed due to high possible of tumour recurrence.

A CASE REPORT OF INTERVENTRICULAR MEMBRANOUS SEPTAL ANEURYSM WITH SUPRAVENTRICULAR TACHYCARDIA: CLINICAL COURSE AND CT FINDINGS.

Nur Syafiqah MR¹, Nurashikin Jamaluddin², Nurul Ain Mat Idris³.

1Department of Radiology, Hospital Sultan Idris Shah, Serdang, Malaysia, 2Department of Radiology, Hospital Raja Perempuan Zainab II, Kota Bharu, Kelantan Malaysia.

Keyword: *Interventricular Membranous Septal; Supraventricular Tachycardia; Computed Tomographic Angiography.*

Interventricular membranous septal (IVMS) aneurysm is an uncommon condition with no accurate incidence. Typically asymptomatic, it can, however, lead to complications such as AV incompetence, conduction defects, and right ventricular obstruction. Here, we present a case of a 49-year-old woman with a history of supraventricular tachycardia (SVT) in 2013, characterized by frequent episodes of palpitations, which were successfully reverted with verapamil. Successful ablation procedures were conducted in 2015, resulting in improved symptoms. Echocardiography incidentally revealed an aneurysmal sinus of Valsalva, while subsequent CT angiography identified an aneurysm originating from the membranous portion of the interventricular septum, measuring 1.1 × 1.5 × 1.8 cm (AP × W × CC). This aneurysm extends into the right ventricle without any outflow tract obstruction. Currently, the patient remains well and asymptomatic, treated conservatively with annual follow-up appointments. This case highlights the significance of recognizing IVMS aneurysms and their management.

VEIN OF GALEN ANEURYSMAL MALFORMATION: A RARE CONGENITAL MALFORMATION OF CEREBRAL VASCULATURE

Chomala R1, Tan TK2, Noor Diyana O3

1Department of Radiology, Hospital University Sains Malaysia, Jalan Raja Perempuan Zainab II, 16152 Kubang Kerian, Kelantan, Malaysia.

2Department of Radiology, Hospital Sultan Abdul Halim, 225, Bandar Amanjaya, 08000 Sungai Petani, Kedah, Malaysia.

3Department of Biomedical Imaging, Advanced Medical & Dental Institute, University Sains Malaysia, 13200, Kepala Batas, Penang

Keywords: *Vein Of Galen Aneurysmal Malformation, Congenital Vascular Malformation, Median Proencephalic Arteriovenous Fistulas*

Vein of Galen aneurysmal malformation (VGAM) is an uncommon congenital malformation of the cerebral vasculature, associated with severe morbidity and mortality, found in neonates, infants and older children. The clinical presentation differs depending on the population of age related to the severity of malformation in which early detection is crucial to ensure a good outcome. Due to its rare entity, we would like to discuss the clinical and radiological features. We report a case of a 1 year old infant, postnatally diagnosed VGAM with non-communicating hydrocephalus and history of PDA and PFO. We would like to highlight the common manifestation as early diagnosis with appropriate imaging modality is required to prevent as an untreatable condition has high mortality rate. Therefore, this case would be to familiarize us with the common manifestation of the disease. A review of literature on clinical findings, diagnosis including radiological findings are herein.

SPONTANEOUS TEMPORAL LOBE HERNIATION INTO TRANSVERSE SINUS MIMICKING VENOUS SINUS THROMBOSIS.

Noor Shahida MP, Jolene LAH, Najwa AK.

Department of Radiology, Hospital Pulau Pinang, Malaysia.

Keywords: *Venous Sinus Thrombosis, Transverse Sinus, Temporal Lobe Herniation*

Herniation of brain parenchymal into dural venous sinus is often an incidental finding and rarely reported. Imaging features include filling defect in the dural venous sinus, hence simulating a thrombosis. We present a case of incidental finding of temporal lobe herniation into transverse sinus through arachnoid granulation. A 59 years old lady with underlying breast carcinoma, post mastectomy and chemoradiotherapy presented with lower back pain. MRI brain and spine was done to look for metastases. Her scan was initially reported as filling defect within left transverse sinus, suggestive of thrombosis and she was treated with anticoagulant. Surveillance MRI done post anticoagulant treatment showed persistent filling defect in the left transverse sinus, which now raises possibility of an alternative diagnosis. This case report is to discuss MRI imaging features of temporal lobe herniation into transverse sinus and other key features to differentiate this condition from other differential diagnoses.

A RARE PRESENTATION OF GASTROINTESTINAL CARCINOID TUMOUR OF THE COLON

Nur Nadia Sabrina AR¹, Patmapriya R¹

1 Radiology Department, Hospital Tengku Ampuan Afzan, Pahang, Malaysia.

Keywords: *Desmoplastic Reaction, Carcinoid, Gastrointestinal*

Introduction

Desmoplastic reaction of tumour denotes the growth of fibrous connective tissue around tumour cells, and has been recognized as a potential prognostic marker for colorectal cancer.

Case Description

60-year-old, Malay lady, with underlying hypertension and morbid obesity, presented with left sided colicky abdominal pain and three days history of no bowel movement or passing flatus, rectal bleed or mucoid stool. Abdominal examination shows tenderness over the left lumbar and iliac fossa region, but no mass palpable. A computed tomography scan done, revealed lobulated enhancing mass adjacent to sigmoid colon with calcification within and desmoplastic reaction of the surrounding tissues.

Conclusion

Carcinoid tumours are a type of neuroendocrine tumour that can occur throughout the gastrointestinal tract. Colon perforation is a rare complication and it's presentation characteristics differ based on the perforation site. In this case, perforation occurred in the cancer site and walled off with the tumoral desmoplastic reaction.

MORPHOLOGICAL ANALYSIS OF SUBAXIAL CERVICAL PEDICLE IN A MALAYSIA POPULATION BY USING COMPUTED TOMOGRAPHY SCAN

Han Liang T1, Shahizon Azura MM2, Kamalnizat I3

1Radiology Department, Hospital Kuala Lumpur, Jalan Pahang, Kuala Lumpur, Malaysia, 2Radiology

Department, Hospital Canselor Tuanku Muhriz UKM, Jalan Yaacob Latif, Cheras, Malaysia.

3Orthopaedic Department, Hospital Canselor Tuanku Muhriz UKM, Jalan Yaacob Latif, Cheras, Malaysia.

Keywords: *Cervical Spine, Morphology, Pedicle, Computed Tomography, Malaysia*

Background

Differences exist in cervical spine morphometric values across different study populations. Malaysia's population is multiracial with a possible variation in the cervical pedicle dimension. An analysis of the cervical pedicle morphology in different ethnicity in our population is crucial in determining any discrepancy if exist that may guide the surgeon to a safer and successful cervical pedicle screw insertion.

Methodology

Subaxial cervical pedicles of 224 subjects were evaluated retrospectively by using computed tomography (CT). Measured pedicle dimensions were outer pedicle width (OPW), inner pedicle width (IPW), outer pedicle height (OPH), inner pedicle height (IPH), and pedicle transverse angle (PTA). Results were compared among sides, genders and ethnics.

Results

The smallest mean OPW and IPW were both at C3 in males (5.36mm and 3.04mm) and females (4.45mm and 2.21mm). The smallest mean OPH was both at C3 in males (8.02mm) and females (6.85mm). The smallest mean IPH was both at C5 in males (3.97mm) and females (3.00mm). The smallest mean PTA was at C7 (40.38°) and the largest mean PTA was at C5 (44.08°). Statistically significant differences of OPW, IPW, OPH, and IPH values were seen in most subaxial cervical level among male gender. Pedicle size was generally larger in Chinese, followed by Malay and Indian.

Conclusion

There is a disparity observed among our study and previous studies from other populations. Familiarity with race-specific data in our population can provide a better guide to our local surgeon in choosing and handling cervical pedicle screw insertion.

HEART-BREAKING EXODUS: A RARE CASE OF PERICARDIAL ABCESS BY DELAYED TUNNELLED CATHETER MIGRATION

Fatin Nadzirah AR¹, Khairina Adliah KA¹, Khatrulnada MS¹, Low JM², Nur Ayub MA³

1 Department of Radiology, Hospital Sultan Haji Ahmad Shah, Temerloh, Pahang, Malaysia.

2 Department of Internal Medicine, Hospital Sultan Haji Ahmad Shah, Temerloh, Pahang, Malaysia.

3 Cardiothoracic Unit Department of General Surgery Hospital Canselor Tuanku Muhriz, PPUKM, Cheras, Wilayah Persekutuan Kuala Lumpur, Malaysia.

Keywords: *Delayed Tunnelled Catheter Migration, Cardiac Perforation, Pericardial Abscess*

Tunnelled haemodialysis catheters via internal jugular vein (IJV) are commonly used to perform haemodialysis in end-stage renal failure patients. Due to its increasing use, the complication rates have also escalated. Rare complications of these catheter insertions include heart perforations (incidence of 0.25-1.4%). We present a case of late migration of right IJV tunnelled haemodialysis catheter causing right atrial perforation 2 months post insertion with initial presentation of purulent fluid on aspiration before dialysis. Chest X-ray revealed deep-seated catheter tip, raising suspicion of malposition. Multiphasic CT unveiled right atrial perforation by the catheter tip with pericardial collection. Subsequently, exploratory sternotomy and atrial wall repair performed. Intraoperatively, it was confirmed that the catheter tip had eroded and perforated at cavo-atrial junction. She was fully recovered from the operation. Migration and perforation of a tunnelled haemodialysis catheter can occur late after implantation and is life-threatening thus requiring immediate diagnostic imaging upon clinical suspicion.

3T MRI FINDINGS OF POST TRAUMATIC ANOSMIA: A CASE REPORT

Geetha Rakwan¹, Muhammad Zakwan Bin Yahya¹

¹Department of Radiology, SASMEC@IIUM Jalan Sultan Ahmad Shah, 25200 Kuantan, Pahang, Malaysia

Keywords: *Anosmia, Olfactory Dysfunction, Traumatic Brain Injury*

Olfactory dysfunction can be caused by various aetiologies including traumatic brain injury, which has a reported incidence of 19%. We report a case of traumatic brain injury causing anosmia in a 36-year-old lady with no previous medical illness. She presented with loss of sense of smell for the duration of a year, which began after an episode of fall. CT Paranasal Sinuses was performed to rule out cribriform plate fracture, which revealed normal findings. Subsequently, MRI Brain was performed to assess the olfactory bulb and frontal lobes, which revealed characteristic atrophy of the right olfactory bulb with encephalomalacia changes of the bilateral gyrus rectus, and medial orbital gyrus consistent with the sequela of traumatic brain injury. Olfactory dysfunction has a significant impact on quality of life. MRI is a valuable objective investigative tool for assessing the olfactory pathway, identifying the cause of olfactory dysfunction, and for proper prognostications.

THE IMPACT OF THE AWARENESS CAMPAIGN ON THE FISTULOPLASTY REFERRAL AND SUCCESS RATE OF FISTULOPLASTY IN HOSPITAL USM

Nik Mohamed Firdaus NMK¹, Nasibah M¹

1Department of Radiology, Hospital Universiti Sains Malaysia

Keywords: *Meccdas, Fistuloplasty*

Background

The Malaysian East Coast Dialysis Access Symposium (MECDAS), initiated in 2017 by the Chronic Kidney Disease (CKD) unit and the East Coast Neuroradiology and Interventional Radiology (ECSNIR), is an awareness program designed to promote available services at the intervention unit and raise awareness about fistula failure. This study aims to evaluate the effectiveness of the MECDAS campaign as an intervention strategy in influencing fistuloplasty referral rates and procedures at Hospital Universiti Sains Malaysia (Hospital USM).

Methodology

This single-center retrospective cross-sectional study evaluated fistuloplasty procedures performed on end-stage renal failure patients with failed fistulas. The study aimed to determine the referral rates for fistuloplasty before and after the campaign by analyzing the number of referrals over a 10-years period. Additionally, the association between the timing of referrals (pre- or post-campaign) and the outcomes of fistuloplasty procedures was assessed using the Chi-Square Test.

Results

The analysis revealed a notable increase in the number of cases during the post-campaign period. However, the referral rates for fistuloplasty, categorized as early or late referrals, did not show a statistically significant difference between the pre- and post-campaign periods. Nonetheless, according to the Pearson's chi-square test, there was a significant association between early referral rates and successful outcomes for fistuloplasty procedures.

Conclusion

The study found a significant association between early referral and higher success rates of fistuloplasty procedures in end-stage renal disease patients. However, the timing of referrals did not significantly differ between the pre- and post-campaign periods. Further investigations incorporating other potential contributing factors and alternative assessment methods are warranted to enhance the outcomes of fistuloplasty interventions.

ATYPICAL CASE OF RUPTURED INTRACRANIAL DERMOID CYST

Nadiyah M¹, Norafida B², Ruwaida AR¹, Mohamad Syafeeq Faez MN², Ezamin AR²

¹Department of Radiology, Hospital Sultan Idris Shah, Serdang, Selangor, Malaysia,

²Department of Radiology, Hospital Sultan Abdul Aziz Shah, Serdang, Selangor, Malaysia.

Keywords: *intracranial dermoid cyst, ruptured, altered behaviour, middle cranial fossa*

An adult female with underlying Major Depressive Disorder presented with recurrent depressive episodes and altered behaviour. Plain CT and MRI showed right middle cranial fossa lesion with a typical CT and MRI features of ruptured dermoid cyst. Intracranial dermoid cysts are uncommon lesions with characteristic imaging appearances. They are rare, benign, congenital, slow-growing cystic lesions. On imaging, they are usually well-defined lobulated, midline masses that have fat density on CT and high signal intensity on T1- with variable signal on T2-weighted MR images, unlike intracranial lipomas, which follow fat density on all sequences. Rupture of intracranial dermoid cysts is a relatively uncommon phenomenon and characteristically associated with fat density material in the subarachnoid spaces, such as intraventricular fat-fluid levels or fat globules in the sulci. It can cause serious complications such as chemical meningitis, vasospasm, and cerebral infarction. MRI is a modality of choice to assess the extension of complications.

SPONTANEOUS RECOVERY OF BILATERAL OVARIAN VEINS RUPTURE FOLLOWING A MOTOR VEHICLE ACCIDENT IN A NON-PREGNANT WOMAN

Tan GX¹, Jessica Hwang Zhen Shan²

^{1,2} Radiology Department, Hospital Sultan Idris Shah Serdang, Selangor, Malaysia

Keywords: *Varicose ovarian veins, Ovarian veins rupture, Retroperitoneal hematoma*

Introduction:

Ovarian vein rupture is rare with only a few cases reported in international literature. We report a very rare case of retroperitoneal hematoma caused by rupture of the varicose veins of bilateral ovaries.

Report:

A 62-year-old lady who presented with vague lower abdominal pain after alleged hit by a motorcycle whilst walking. Post trauma, she was able to self ambulate to the hospital for treatment. Her admission contrasted computed tomography revealed bilateral retroperitoneal hematomas originated from rupture of the abnormally dilated bilateral ovarian veins which was confirmed on subsequent portovenous and delayed scans. No active arterial hemorrhage demonstrable. No nutcracker syndrome. She was hemodynamically stable hence treated conservatively in the ward. She was discharged home subsequently in few days time.

Conclusion:

In a case of a traumatic event with acute abdomen in a female patient demonstrating retroperitoneal hematoma, the possibility of ovarian veins hemorrhage should be kept in mind.

GIANT ADENOMATOID ODONTOGENIC TUMOR OF MAXILLA: RADIOGRAPHIC AND PATHOLOGIC FINDING

Humairah¹, Rafikah, R², Sri, A², Nur, AB², dr. Dario, N²

¹Radiology Resident, Radiology Department, Faculty of Medicine, Hasanuddin University, Makassar, Indonesia

²Radiology Consultant, Radiology Department of DR Wahidin Sudirohusodo Hospital, Faculty of Medicine, Hasanuddin University, Makassar, Indonesia²

Keywords: *Adenomatoid Odontogenic Tumor, Maxilla, Radiologic Finding*

Adenomatoid odontogenic tumors (AOTs) are rare benign locally aggressive epithelial tumors, comprising 3% of all odontogenic tumors. Often misdiagnosed as odontogenic cysts (OC), both presents as painless lesions. We present a 18 - y.o female presented with lump on left maxilla. Non-Enhanced Brain CT-Scan revealed a well-defined expansile dominant cystic lesion (3-28 HU) containing tooth measuring 6.4 x 4.7 x 5.7 cm expanding into the left maxillary sinus, alveolar process, inferior orbital wall, and left nasal cavity causing septum deviation. Both AOT and OC showing unilateral radiolucent lesion with clear boundaries. However, regular lesion morphology shows that CT were consistent with AOT and confirmed with pathology examinations which revealed thick fibrous connective tissue with foci of bone trabeculae in the wall and nodular tumor nests of proliferating odontogenic epithelial cells inside the cyst. In summary, AOTs are rare odontogenic tumors and should be included in the differential diagnosis of cystic maxillary lesions.

REVIEW OF BREAST CANCER IMAGING CHARACTERISTICS: CORRELATION WITH CLINICOPATHOLOGICAL FEATURES AND TUMOUR MICROENVIRONMENT

Raihanah H¹, Noor Khairiah K¹, Fakhriah Aiman MB¹, Norazilla MA¹, Siti Kamariah CM¹, Radhiana H¹, Azian AA¹, Mohd Radhwan A¹, Nor Ain R¹, Khairunisa AA²

¹Department of Radiology, Kulliyah of Medicine, International Islamic University of Malaysia, Kuantan, Malaysia

²Department of Pathology and Laboratory Medicine, International Islamic University of Malaysia, Kuantan, Malaysia

Keywords: Breast Cancer, Ultrasound, Mammography, Molecular Subtypes, Histopathology, Tumour-Infiltrating Lymphocytes, Lymphocyte-Predominant Breast Cancer

Background

Breast carcinoma (BC) is a highly heterogeneous disease with multiple laboratory-based facets critical for treatment planning, prediction of treatment response, and long-term survival rate. Of late, tumour-infiltrating lymphocytes (TILs) have also emerged to influence patient prognosis. Understanding how these relate with sonographic and mammographic characteristics of BC can guide personalized treatment strategies. This literature review aims to investigate the association between laboratory and imaging characteristics of BC.

Methodology

A comprehensive literature search was conducted, including studies published between 2000 till 2023. The key findings from these studies were analysed and synthesized to provide a comprehensive overview of the current knowledge in this field.

Results

Tumors with circumscribed margins were linked to high grade, hormone receptor-negative, and triple-negative BC (TNBC). Lesions eliciting posterior acoustic shadowing were likely to be hormone receptor positive. Posterior acoustic enhancement, circumscribed margin and large tumor size were related to TNBC. The presence of posterior mixed features with microcalcifications was related to HER2-enriched subtypes. Tumor margins were a robust predictor of histologic grade. Spiculated margins and sonographic posterior shadowing are associated with grade 1; while oval / round shapes, indistinct / microlobulated margins and sonographic posterior enhancement are associated with grade 3. Lobulated shape, sonographic hypoechogenicity and posterior acoustic enhancement were predictors of lymphocyte-predominant BC.

Conclusion

Mammography and ultrasound have demonstrated potential in assessing clinicopathological features and tumour microenvironment in BC. Further research are needed to establish the clinical utility of BC imaging features to enhance patient risk stratification and directing individualized treatment plans.

(248 words)

UNRAVELLING THE MYSTERY: NAVIGATING AN UNUSUAL CASE OF ACUTE ABDOMEN

May Foo Tse Ling^{1,2}, Noor Khairiah A. Karim³, Sharmila A/P Arumugam², Preetvinder Singh A/L Dheer Singh²

1 Department of Radiology, School of Medical Sciences, Health Campus, Universiti Sains Malaysia, 16150 Kubang Kerian, Kelantan, Malaysia.

2 Department of Radiology, Hospital Raja Permaisuri Bainun, 30450 Ipoh, Perak, Malaysia.

3 Department of Biomedical Imaging, Advanced Medical and Dental Institute, Universiti Sains Malaysia, Bertam, 13200 Kepala Batas, Pulau Pinang, Malaysia.

Keywords: *Acute Gastric Volvulus, Organo-Axial, Contrast Enhanced Computed Tomography*

Acute gastric volvulus is an uncommon surgical emergency, causing gastric outlet obstruction or vascular compromise with risk of rapidly developing strangulation and stomach perforation. A 75-year-old lady with previous history of laparoscopic paraesophageal hernia repair, complained of worsening abdominal pain and vomiting for 2-3 days. Clinically she had generalized abdominal tenderness and palpable vague central abdominal mass. Laboratory investigations showed leucocytosis and decompensated metabolic acidosis. Diagnosis of septic shock secondary to strangulated incisional hernia was initially made. However contrast enhanced computed tomography (CECT) of abdomen later revealed organo-axial gastric volvulus as evidenced by reversal of lesser and greater curvatures location with abrupt narrowing and twisting of pylorus, which was confirmed intra-operatively. The diagnosis can be challenging as patients often came with non-specific abdominal symptoms. CECT is helpful in such cases when diagnosis is in doubt as early surgical intervention are crucial in management of such condition.

**ATYPICAL PRESENTATION OF LOWER LIMB WEAKNESS AND PAIN WITH PARAVERTEBRAL SOFT TISSUE
MASSES IN ACUTE LYMPHOBLASTIC LEUKAEMIA: A RARE CASE REPORT**

Fadzrie Azim FD¹; Masiyati J¹, Diyana A²

1Radiology Department, Malacca Hospital, 2 Pathology Department, Malacca Hospital.

Keywords: *Leukaemia, Weakness, Paravertebral, Soft Tissue*

Acute Lymphoblastic Leukaemia (ALL) is the most common haematological malignancy in children accounting for 80% of cases, known for its systemic manifestation. Occasionally it may present with unusual extramedullary involvement. We present a case of a 3 year old boy presented with chronic recurrent lower limb pain and constitutional symptoms. Despite initial clinical and laboratory findings to be non-specific, initial lower limb X-ray radiological examination reveals symmetrical osteopenic bony lucencies with supplementary MRI lower limb and spine showing multiple medullary bone lesions with paravertebral soft tissue masses. Further diagnostic workup including bone marrow aspiration and biopsy confirmed diagnosis of pre-B cell acute lymphoblastic leukaemia, in which patient has commenced on an intensive chemotherapy regimen. This case underscores the importance of considering haematological malignancies as part of the differentials in patients presenting with unexplained neurological symptoms with soft tissue masses. Early recognition and management are crucial to optimise patient outcome.

ABSENT MECKEL'S CAVE AS A CAUSE OF TRIGEMINAL NEURALGIA

Hafeeza M 1, Hasyma AH 1, Hilwati H 2

1 Department of Radiology, Hospital Sultan Abdul Aziz Shah, Upm

2 Department of Radiology, Hospital Sultan Al-Abdullah, Uitm

Keywords: *Neuroradiology, Trigeminal Neuralgia, Absent Meckel's Cave*

Trigeminal neuralgia is one of the most common forms of craniofacial neuropathic pain with female predilection. It is most commonly due to vascular compression by adjacent blood vessels; usually the superior cerebellar artery. Other causes include external compression by tumours or demyelinating disease such as multiple sclerosis. Absent or deficient Meckel's cave is one of the rarest and least reported aetiology of trigeminal neuralgia. We present a case of a 34-year-old lady with a 3-week history of right sided facial pain of electrical sensation, triggered by touch, chewing and brushing her teeth. She was prescribed with Amitriptyline and Gabapentin for the treatment of trigeminal neuralgia. Subsequent MRI revealed deficient right Meckel's cave with atrophy of the cisternal and the cavernous segment of the ipsilateral trigeminal nerve. We will discuss on the imaging features and the diagnostic criteria.

CASE OF AN UNFORESEEN CAUSE OF SMALL BOWEL OBSTRUCTION – SMALL BOWEL BEZOAR

Sharllina P1, Mohd Norsyafi H1, Emy Saera R1

Radiology Department, Hospital Sungai Buloh, Jalan Hospital, Sungai Buloh, Malaysia

Keywords: *Phytobezoar, Small Bowel Faeces Sign*

Bezoars are aggregation of indigestible contents within the gastrointestinal tract and can cause small bowel obstruction. Radiological findings are valuable for the diagnosis of bezoars in the preoperative period. We report a case of a 68-year-old male with underlying diabetes mellitus, hypertension and major depressive disorder who presented with bowel obstructive symptoms for 4 days. Abdominal radiograph showed small bowel dilatation. Contrast-enhanced CT demonstrates small bowel faeces sign with mottled gas-patterned intra-luminal mass at the distal jejunum and small bowel obstruction. Patient underwent exploratory laparotomy. Postoperative diagnosis of impacted food bezoar within the jejunum was concluded. Histopathological examination confirmed the diagnosis of phytobezoar. Patient was discharged on day 11 postoperatively. Bezoar is a rare cause of small bowel obstruction which could mimic small bowel faeces sign on CT. Role of imaging is essential in the diagnosis of this case aiding in early treatment.

NEUROIMAGING MANIFESTATIONS OF WILSON'S DISEASE

Tew Hui Sin, Hazwan Amzar Khairul Annuar

Department of Biomedical Imaging, Faculty of Medicine, Universiti Malaya, 50603 Kuala Lumpur, Malaysia.

Keywords: *Wilson's Disease, Double Panda Sign, Kayser-Fleischer Rings, MRI*

A 19-year-old woman presented with progressive slurring of speech over three years, accompanied by sudden-onset unsteady gait for two weeks. Neurological examination revealed rigidity and ataxic gait. CT brain showed symmetrical hypodensities in bilateral thalami and midbrain. MRI revealed T2 hyperintensity involving both putamen, thalami, internal capsules, splenium of the corpus callosum, and brainstem. Notably, the "double panda sign" was evident, indicative of midbrain and pons involvement, alongside severe midbrain atrophy. Areas of restricted diffusion were seen at the splenium of the corpus callosum and both thalami. Further investigations revealed bilateral Kayser-Fleischer rings and reduced serum ceruloplasmin levels, confirming the diagnosis of Wilson's disease. Oral Penicillamine therapy was initiated. This case highlights the importance of recognizing diverse neurological manifestations of Wilson's disease for timely intervention and management.

The design of the cover page for the Malaysian Congress of Radiology 2024 feature elements such as exploring into the world of Natural Language Processing (NLP) and its potential to shake up how we do things in radiology. Together, let us embark on this enlightening journey to examine the vast potential of NLP and its direct relevance to our everyday clinical practices. Welcome to a congress that's all about embracing innovation and pushing the boundaries of what's possible in our field!

Foreword

We stand at the crossroads of medical progress, where the intricate tapestry of tradition intertwines seamlessly with the boundless realms of innovation. The Malaysian Congress of Radiology 2024, held from 26-28th July 2024 in the vibrant city of Kuala Lumpur, serves as a beacon for the convergence of foundational knowledge and cutting-edge advancements in the field of radiology.

Within the pages of this abstract book, we present the culmination of intellectual pursuit and scientific rigor, showcasing the abstracts carefully curated from a pool of brilliant minds. The theme of "Beyond The Report: Interplay of Language and Radiology" encapsulates the essence of this congress, as radiologists, radiology trainees, and allied health professionals come together to explore the harmonious interplay between time-honoured practices and pioneering technologies.

I commend the dedication and expertise of all those who have contributed to this abstract book. May it inspire fruitful discussions, ignite fresh insights, and foster collaborations that will shape the future of radiology, ensuring the highest standards of patient care and medical excellence.

Professor Dr Norlisah Mohd Ramli
President
College of Radiology, Academy of
Medicine of Malaysia 2022 – 2025
&
President
Malaysian Society of Radiologists
2023 – 2025

Professor Dr Kartini Rahmat
Organising Chair
Malaysian Congress of
Radiology 2024

Assoc Prof Dr Farhana Fadzli
Scientific Chair
Malaysian Congress of
Radiology 2024

JOURNAL OF HEALTH AND TRANSLATION MEDICINE

(formerly known as Journal of the University of Malaya Medical Centre)

JUMMEC

Contents

ORAL01: UNRAVELLING THE SECRETS OF OBESITY AND SARCOPENIA IN RELATION TO FALL AND FALL-RELATED OUTCOME IN OLDER PEOPLE (OSFOP): USE OF MAGNETIC RESONANCE IMAGING (MRI) OF BILATERAL THIGH .	8
ORAL02: AI-ENHANCED GADOLINIUM DOSING IN MRI: A PROMISING FUTURE	9
ORAL03: ROLE OF MAGNETIC RESONANCE PLANIMETRY AND MAGNETIC RESONANCE PARKINSONISM INDEX IN DISCRIMINATING PARKINSON'S DISEASE AND PROGRESSIVE SUPRANUCLEAR PALSY: A RETROSPECTIVE STUDY BASED ON 1.5 AND 3 T MRI.....	10
ORAL04: COMPOSITE SERUM PSA FACTOR IN THE PI-RADS CATEGORY IMPROVES THE DETECTION ACCURACY IN PATIENT WITH SUSPECTED PROSTATE CARCINOMA.....	11
ORAL05: ULTRASOUND MEASUREMENT OF QUADRICEPS MUSCLE AS AN ASSESSMENT TOOL FOR SARCOPENIA IN HOSPITALIZED OLDER PATIENTS	12
ORAL06: COMPUTED TOMOGRAPHY AND MAGNETIC RESONANCE IMAGING OF HYDATID CYSTS: A CASE SERIES IN AFGHANISTAN	13
ORAL07: INTERPRETATIVE PERFORMANCE OF OPPORTUNISTIC SCREENING DIGITAL BREAST TOMOSYNTHESIS IN A TERTIARY CARE HOSPITAL	14
ORAL08: MAMMOGRAPHIC SURVEILLANCE FOR BREAST CANCER SURVIVORS_A SYSTEMATIC REVIEW AND META-ANALYSIS	15
ORAL09: ACCURACY OF MRI IN DETECTING 1P/19Q CO-DELETION STATUS OF GLIOMAS: A SINGLE-CENTER RETROSPECTIVE STUDY.....	16
ORAL10: AI IN MAMMOGRAPHY IN AN OPPORTUNISTIC SCREENING AND DIAGNOSTIC CLINICAL SETTING.....	17
ORAL11: ACUTE ACL INJURY RELATIONSHIP WITH INCREASED VASTUS MEDIALIS TO SEMIMEMBRANOSUS CROSS-SECTIONAL RATIO AND ASSESSING OTHER CONCURRENT INJURIES USING WORMS SCORE AS A TOOL: A CASE CONTROL RETROSPECTIVE STUDY.....	18
ORAL12: BREAST MRI IMAGING FEATURES IN INVASIVE BREAST CANCER AND ITS RADIOMICS SIGNATURE AS AN IMAGING BIOMARKER	19
ORAL13: ESTABLISHING THE FIRST NEURORADIOLOGY SERVICES IN HERAT, AFGHANISTAN	20
ORAL14: RADIOLOGICAL AND CLINICAL PROGNOSTIC FACTORS IN ADULT INTRACRANIAL TUBERCULOSIS	21
ORAL15: SPIGELIAN HERNIA: A RARE CASE PRESENTATION AND REVIEW LITERATURE.....	22
POS01: IMAGING MANIFESTATIONS AND COMPLICATIONS OF ODONTOGENIC INFECTIONS: AN ILLUSTRATIVE REVIEW	23
POS02: ATYPICAL PRIMARY CNS LYMPHOMA, A GHOST TUMOUR	24

POS03: LEPTOMENINGEAL METASTASES IN NEURO-ONCOLOGY: IT'S ALL ABOUT TIMING	25
POS04: DIAGNOSTIC ACCURACY OF HYPERDENSE ARTERY SIGN IN EARLY DETECTION OF MIDDLE CEREBRAL ARTERY INFARCTION: A CROSS-SECTIONAL VALIDATION STUDY.....	26
POS05: ASSESSMENT PRECISION OF CT PERFUSION IMAGING IN THE DETECTION OF ACUTE ISCHEMIC STROKE: A SYSTEMATIC REVIEW AND META-ANALYSIS.....	27
POS06: UNVEILING THE NEUROVASCULAR ODYSSEY: A CASE OF PERSISTENT TRIGEMINAL ARTERY MIMICKING STROKE-LIKE SYMPTOMS IN A NEWLY DIAGNOSED HYPERTENSIVE PATIENT	28
POS07: PRIMARY RENAL SYNOVIAL SARCOMA PRESENTING AS COMPLEX RENAL CYST COMPLICATED WITH A LARGE PERINEPHRIC COLLECTION- A RARE CASE	29
POS08: CONTRAST-ENHANCED MAMMOGRAPHY AND MRI IN BREAST CANCER DIAGNOSIS AND EVALUATION	30
POS09: CHEST WALL DESMOID TYPE FIBROMATOSIS MIMICKING BREAST CARCINOMA - A CASE REPORT	31
POS10: A RARE CASE OF URACHAL MUCINOUS CYSTIC NEOPLASM	32
POS11: CANAL OF NUCK CYST: A RARE CAUSE OF INGUINAL SWELLING IN ADULT FEMALES.....	33
POS12: THE CT QUADRATE LOBE FOCAL HOT SPOT SIGN IN SUPERIOR VENA_CAVA OBSTRUCTION.....	34
POS13: GIANT PENILE ELEPHANTIASIS FOLLOWING MULTIPLE CIRCUMCISIONS: A RARE COSMETIC AND FUNCTIONAL COMPLICATION.....	35
POS14: ABDOMINAL PAIN WITH A TWIST: A RARE CASE OF OMENTAL TORSION	36
POS15: RARE CASE OF GIANT SIGMOID DIVERTICULUM.....	37
POS16: INTERNAL HERNIA THROUGH BROAD LIGAMENT DEFECT: A RARE CASE REPORT	38
POS17: DECIPHERING THE PUZZLE: CHALLENGES IN DIAGNOSING CAECAL BASCULE WITH SMALL BOWEL DILATATION.	39
POS18: SPONTANEOUS HEMORRHAGE OF LEIOMYOMA– A TALE OF RARE LEIOMYOMA COMPLICATION	40
POS19: INCIDENTAL FINDING OF LITHOPEDION IN A PATIENT WITH VAGUE PELVIC SYMPTOMS	41
POS20: COMPLIANCE OF THE USAGE OF WATER AS NEUTRAL ORAL CONTRAST IN CT ABDOMEN.	42
POS21: IMAGING FINDINGS OF PRIMARY PRIMITIVE NEUROECTODERMAL TUMOUR OF THE LIVER - A CASE REPORT	43
POS22: LIFE-THREATENING PULMONARY COMPLICATIONS FROM BREAST FILLER INJECTION	44
POS23: WUNDERLICH SYNDROME: A CASE REPORT	45
POS24: RENAL VASCULAR ABNORMALITIES IN A MISSED RENAL MASS.....	46
POS25: PLANTAR FASCIITIS TREATED WITH AUTOLOGOUS WHOLE BLOOD	47
POS26: MORPHOLOGY AND MORPHOMETRY EVALUATION OF ADULT COCCYX WITH MULTIDETECTOR COMPUTED TOMOGRAPHY IN SULTAN AHMAD SHAH MEDICAL CENTRE @IIUM	48
POS27: ASSOCIATION BETWEEN MEAN PLATELET VOLUME AND HEMORRHAGIC TRANSFORMATION AMONG PATIENTS WITH CEREBRAL INFARCTION IN DR. JOSE N. RODRIGUEZ MEMORIAL HOSPITAL AND SANITARIUM. 49	

POS28: DIAGNOSTIC EFFICACY OF DUAL ENERGY CT FOR DIFFERENTIATING INTRACEREBRAL HEMORRHAGE FROM IODINATED CONTRAST MATERIAL STAINING	50
POS29: LOEFFLER ENDOCARDITIS WITH VENTRICULAR LAMINAR THROMBUS	51
POS30: ATYPICAL PROSTATE METASTASIS: A CASE SERIES	52
POS31: BROAD LIGAMENT SOLITARY FIBROUS TUMOR MIMICKING HUGE OVARIAN NEOPLASM: A RADIOLOGICAL PERSPECTIVE	53
POS32: ATYPICAL MANIFESTATION OF ACUTE APPENDICITIS MASQUERADING AS MALIGNANT LESION ON CT IMAGING	54
POS33: GALLSTONE ILEUS WITH PROXIMAL SMALL BOWEL PERFORATION, A RARE COMPLICATION CARRYING SIGNIFICANT RISK OF INCREASED MORTALITY, NOT TO BE MISSED.	55
POS34: A RARE PRESENTATION: SIGMOID VOLVULUS AS THE CAUSE OF INTESTINAL OBSTRUCTION IN A YOUNG FEMALE	56
POS35: PRIMARY RENAL LYMPHOMA PRESENTING AS BILATERAL RENAL PELVIS SOFT TISSUE LESIONS- A RARE CASE	57
POS36: RUPTURED ABDOMINAL AORTIC ANEURYSM (AAA) AS A RARE CAUSE OF STROKE.....	58
POS37: COMPLICATION FROM CONSUMPTION OF ‘KING OF FRUIT’: A CASE REPORT OF SMALL BOWEL OBSTRUCTION DUE TO DURIAN SEED IMPACTION	59
POS38: UTILIZATION OF 3D MRI IN DIAGNOSING EARLY CAESAREAN SCAR ECTOPIC PREGNANCY: A CASE REPORT	60
POS39: BEYOND THE CONVENTIONAL: EXPLORING RADIOLOGICAL APPROACHES IN DIAGNOSING CERVICAL PREGNANCY	61
POS40: MISDIAGNOSED LEFT ADNEXAL MASS REVEALED AS <i>PERITONEAL</i> SPLENOSIS.....	62
POS41: PERITONEAL PARADOX: TUBERCULOSIS MASQUERADING AS ABDOMINAL MALIGNANCY	63
POS42: QUANTITATIVE MEASUREMENT OF MYELIN IN NEURODEGENERATIVE DISEASE	64
POS43: PYLEPHLEBITIS MIMICKING A MESENTERIC MASS: A RARE COMPLICATION OF PERFORATED APPENDICITIS WITH UNIQUE RADIOLOGICAL FINDINGS.....	65
POS44: PRIMARY NON-HODKIN’S LMYPHOMA MIMICKING CHOLANGIOCARCINOMA	66
POS45: HEPATIC ANGIOMYOLIPOMA MIMICKING HEPATOCELLULAR CARCINOMA.....	67
POS46: MESENTERIC FIBROMATOSIS: A LITTLE KNOWN AND RARE AGGRESSIVE BENIGN TUMOR	68
POS47: UTERINE DEHISCENCE: A RARE BUT RELEVANT POSTPARTUM COMPLICATION THAT DEMANDS ATTENTION.....	69
POS48: INCIDENCE OF RETROAORTIC RENAL VEIN IN PATIENTS WITH ACUTE FLANK PAIN	70
POS49: A RARE CASE OF METACHRONOUS SECOND PRIMARY PENILE MALIGNANCY IN A CONFIRMED PROSTATE CANCER.....	71
POS50: FREE SILICONE BREAST INJECTIONS: DIAGNOSTIC IMAGING CHALLENGES	72

POS51: ADVANCE MRI APPROACH TO DETECT RESIDUAL BREAST MALIGNANCY: A CASE REPORT.....	73
POS52: NAVIGATING THE NEXUS: PRIMARY ANGIOSARCOMA OF THE BREAST: IMAGING INSIGHTS AND HISTOPATHOLOGICAL CORRELATION	74
POS53: DIAGNOSIS CHALLENGE: SMALL BOWEL PERFORATION FROM FISH BONE INGESTION IDENTIFIED BY RADIOLOGICAL IMAGING.....	75
POS54: HISTOLOGICALLY PROVEN HIGH GRADE GLIOMA SHOWING HIGH SIGNAL ACTIVITY AMIDE PROTON TRANSFER WEIGHTED MRI: A CASE SERIES.	76
POS55: DEVELOPMENT OF VASOGENIC CEREBRAL EDEMA AFTER CT MYELOGRAM WITH NONIONIC CONTRAST	77
POS56: LYMPHOMATOSIS CEREBRI: A DIAGNOSTIC DILEMMA.....	78
POS57: DIABETIC FIBROUS MASTOPATHY MASQUERADING AS BREAST MALIGNANCY	79
POS58: LYRE SIGN – WHERE SCHWANNOMA MIMICS A CAROTID BODY TUMOUR.	80
POS59: TUBERCULOMA – A MIMICKER OF POSTERIOR FOSSA MASS IN YOUNG ADULT	81
POS60: ARTERY OF PERCHERON INFARCTION: A CASE REPORT	82
POS61: OMENTAL TORSION, AN UNACCUSTOMED MIMICKER OF ACUTE APPENDICITIS	83
POS62: THE MISSING PIECE OF A BLEEDING PUZZLE	84
POS63: UNLOCKING SOLUTIONS: THE CRUCIAL ROLE OF EMBOLIZATION IN MANAGING BLEEDING COMPLICATIONS IN AML WITH ACUTE PANMYELOSIS AND MYELOFIBROSIS.....	85
POS64: PERCUTANEOUS BIOPSY OF RETROPHARYNGEAL LESION; APPROACH AND STRUCTURES TO AVOID	86
POS65: TWO BECOME ONE: A DILEMMA BETWEEN SOFT TISSUE SARCOMA AND MALIGNANT PHYLLODES TUMOR	87
POS66: NAVIGATING THE CURVE: TORTUOUS VERTEBRAL ARTERY INDUCING NEURAL FORAMINA NARROWING CAUSING CERVICAL RADICULOPATHY.....	88
POS67: A RARE CASE OF DIEULAFOY LESION IN A MIDDLE AGED WOMAN.....	89
POS68: ISOLATED SINONASAL CRANIOPHARYNGIOMA PRESENTED AS LEFT NASAL CAVITY MIXED CALCIFIED AND CYSTIC LESIONS WITH NO SUPRASELLAR COMPONENT - A RARE CASE.	90
POS69: A CASE REPORT OF INTERVENTRICULAR MEMBRANOUS SEPTAL ANEURYSM WITH SUPRAVENTRICULAR TACHYCARDIA: CLINICAL COURSE AND CT FINDINGS.....	91
POS70: VEIN OF GALEN ANEURYSMAL MALFORMATION: A RARE CONGENITAL MALFORMATION OF CEREBRAL VASCULATURE	92
POS71: SPONTANEOUS TEMPORAL LOBE HERNIATION INTO TRANSVERSE SINUS MIMICKING VENOUS SINUS THROMBOSIS.	93
POS72: A RARE PRESENTATION OF GASTROINTESTINAL CARCINOID TUMOUR OF THE COLON	94
POS73: MORPHOLOGICAL ANALYSIS OF SUBAXIAL CERVICAL PEDICLE IN A MALAYSIA POPULATION BY USING COMPUTED TOMOGRAPHY SCAN.....	95

POS74: HEART-BREAKING EXODUS: A RARE CASE OF PERICARDIAL ABCESS BY DELAYED TUNNELLED CATHETER MIGRATION	96
POS75: 3T MRI FINDINGS OF POST TRAUMATIC ANOSMIA: A CASE REPORT	97
POS76: THE IMPACT OF THE AWARENESS CAMPAIGN ON THE FISTULOPLASTY REFERRAL AND SUCCESS RATE OF FISTULOPLASTY IN HOSPITAL USM.....	98
POS77: ATYPICAL CASE OF RUPTURED INTRACRANIAL DERMOID CYST	99
POS78: SPONTANEOUS RECOVERY OF BILATERAL OVARIAN VEINS RUPTURE FOLLOWING A MOTOR VEHICLE ACCIDENT IN A NON-PREGNANT WOMAN.....	100
POS79: GIANT ADENOMATOID ODONTOGENIC TUMOR OF MAXILLA: RADIOGRAPHIC AND PATHOLOGIC FINDING	101
POS80: REVIEW OF BREAST CANCER IMAGING CHARACTERISTICS: CORRELATION WITH CLINICOPATHOLOGICAL FEATURES AND TUMOUR MICROENVIRONMENT.....	102
POS81: UNRAVELLING THE MYSTERY: NAVIGATING AN UNUSUAL CASE OF ACUTE ABDOMEN	103
POS82: ATYPICAL PRESENTATION OF LOWER LIMB WEAKNESS AND PAIN WITH PARAVERTEBRAL SOFT TISSUE MASSES IN ACUTE LYMPHOBLASTIC LEUKAEMIA: A RARE CASE REPORT	104
POS83: ABSENT MECKEL'S CAVE AS A CAUSE OF TRIGEMINAL NEURALGIA	105
POS84: CASE OF AN UNFORESEEN CAUSE OF SMALL BOWEL OBSTRUCTION – SMALL BOWEL BEZOAR	106
POS85: NEUROIMAGING MANIFESTATIONS OF WILSON'S DISEASE.....	107

UNRAVELLING THE SECRETS OF OBESITY AND SARCOPENIA IN RELATION TO FALL AND FALL-RELATED OUTCOME IN OLDER PEOPLE (OSFOP): USE OF MAGNETIC RESONANCE IMAGING (MRI) OF BILATERAL THIGH

Vijeya PS1, Fadhli MS2, Ng KH3

Biomedical Imaging, University Malaya, Jalan Professor Ungku Aziz, Kuala Lumpur, Malaysia,

Keywords: *Obesity, Sarcopenia, Fall*

Background

The study investigates the relationship between increased thigh fat and muscle loss and the incidence of falls in elderly individuals.

Methodology

This single-center, prospective case-control study at University Malaya Medical Centre involved 76 randomly selected volunteers aged 60-80 who had MRI scans of their thighs, and 26 also had DXA scans. Data were analyzed using SPSS.

Results

Of the 76 participants, 57.9% were female, and 64.5% had experienced falls. The median age was 68, and the average BMI was 25.2. A strong correlation ($r>0.8$) was found between thigh adiposity and muscle mass in MRI and DXA scans. Overweight and obese elderly participants had significantly lower muscle mass in both cross-sectional area at 50% femur length (CSAF) ($\ln=1.82$, $p=0.031$) and mean volume of the mid-thigh (VMTT) ($\ln=6.40$, $p=0.023$) compared to non-fallers. No significant relationship was found between thigh adiposity and falls.

Conclusion

MRI of the CSA at 50% femur length correlates well with DXA for muscle mass and fat, making it effective for assessing sarcopenia. Elderly fallers with $\text{BMI} \geq 25 \text{ kg/m}^2$ had lower muscle mass, but no significant link between thigh adiposity and falls was found.

AI-ENHANCED GADOLINIUM DOSING IN MRI: A PROMISING FUTURE

Prof. Charbel Saade

University of College Cork, Ireland

Keywords: *Artificial Intelligence, Gadolinium, Dose*

Background

Artificial intelligence (AI) is revolutionizing medical imaging, and one area where it shows great promise is in optimizing gadolinium dosing during magnetic resonance imaging (MRI). Gadolinium-based contrast agents enhance MRI images, providing crucial diagnostic information.

Methods

Recent studies have revealed trace amounts of gadolinium remaining in patients' bodies after contrast-enhanced MRI exams. The implications of this deposition are not fully understood, prompting researchers to explore ways to reduce gadolinium exposure while maintaining diagnostic quality.

Results

Researchers at Stanford University have turned to deep learning - a sophisticated AI technique - to address this challenge. By training a deep learning algorithm on pre-contrast scans (zero-dose), low-dose scans (10% of standard gadolinium dose), and full-dose scans (100% dose), they achieved remarkable results. The algorithm learned to approximate full-dose images from lower-dose data, demonstrating that AI could potentially create equivalent contrast-enhanced images without any contrast agent use. Importantly, image quality remained comparable between low-dose AI-enhanced images and full-dose contrast-enhanced images.

Conclusion

This breakthrough suggests that AI has the potential to dramatically reduce gadolinium dose while preserving diagnostic accuracy. As further advancements occur, AI-driven gadolinium dosing may become a standard practice, enhancing patient safety and clinical outcomes in MRI examinations. While AI holds great promise, ongoing research and clinical validation are essential to fully realize its benefits in medical imaging. The future of dosing lies at the intersection of AI and patient care.

ROLE OF MAGNETIC RESONANCE PLANIMETRY AND MAGNETIC RESONANCE PARKINSONISM INDEX IN DISCRIMINATING PARKINSON'S DISEASE AND PROGRESSIVE SUPRANUCLEAR PALSY: A RETROSPECTIVE STUDY BASED ON 1.5 AND 3 T MRI

Fatima Mubarak

Radiology Department, Aga Khan University Hospital, Karachi. Pakistan

Keywords: *Magnetic Resonance Imaging, Parkinsonism, Parkinsons Disease, Progressive Supranuclear Palsy*

Background

Magnetic resonance imaging (MRI) has a substantial role in the diagnosis of various movement disorders. The aim of study was to evaluate the diagnostic accuracy of MRPI measured by quantitative MRI analysis and to propose MRI-based criteria to help the clinician to recognize these parkinsonian syndromes.

Methodology

After ethical approval was obtained, analysis of 34 consecutive patients with PSP, 34 patients with PD and 34 healthy controls (HCs) was performed from retrospective data from the past 10 years. The measurements of pons area–midbrain area ratio (P/M) and MCP width–superior cerebellar peduncle (SCP) width ratio (MCP/SCP) were used, and MRPI was calculated by the formula $([P/M] \times [MCP/SCP])$.

Results

Midbrain area and SCP width in patients with PSP (19 males, 15 females; mean age =66.7 years) were significantly ($P < 0.001$) smaller than in patients with PD (20 males, 14 females; mean age =66.7 years) and control participants (17 males, 17 females; mean age =66.1 years). MRPI value was significantly higher in patients with PSP (mean 21.00) than in patients with PD (mean 9.50; $P < 0.001$) and control participants (mean 9.6; $P < 0.001$), without any overlap of values among groups. No patient with PSP received a misdiagnosis when the index was used (sensitivity and specificity, 100%)

Conclusion

MRPI should be made an essential part of all MRI brain reporting whenever differentiation between PD and PSP is sought for.

COMPOSITE SERUM PSA FACTOR IN THE PI-RADS CATEGORY IMPROVES THE DETECTION ACCURACY IN PATIENT WITH SUSPECTED PROSTATE CARCINOMA

Yogambigai B¹, Hazeman Z², Idris I³, Fathinul FAS⁴

1,3 Radiology Department, Hospital Sultan Abdul Aziz Shah UPM, Persiaran Mardi UPM, Serdang, Selangor, 2, 3 Centre for Diagnostic Nuclear Imaging, Universiti Putra Malaysia, 43400 Serdang, Selangor

Keywords: *Prostate Carcinoma, Multiparametric MRI, PI-RADS*

Background

Prostate Imaging Reporting and Data System (PI-RADS) standardise the evaluation and reporting system for multiparametric MRI prostate (mpMRI) which has been used for prostate carcinoma diagnosis. However, equivocal PIRADS 3 lesions with malignant changes pose uncertainty to true positive findings. This study aimed to determine diagnostic accuracy of a composite PI-RADS (V2.1) and serum prostate specific antigen (PSA) in detecting prostate carcinoma.

Methodology

A cross-sectional retrospective study was done on 36 patients (median age 67) who underwent multiparametric-MRI (mp-MRI) prostate. PI-RADS scoring was evaluated based on the PIRADS (V2.1) categories and combined with the serum PSA. The patients were dichotomized into the PIRADS-only (PIRADS >3 versus PIRADS >4) and the composite PIRADS-serum PSA for the category of PIRADS >3 for high susceptibility of malignancy.

Results

The median PSA level was 10.5 ng/ml. Thirty-four patients (94.0%) had lesions with PIRADS 3 above in the mp-MRI. The biopsy results were positive for prostate carcinoma in 14 patients (39.0%). For the PIRADS-only category, the sensitivity and specificity of PIRADS >4 and PIRADS >3 were 78.6% and 81.8% and 100% and 9.1% respectively. For the PIRADS-PSA category, utilizing the PSA of 10 ng/ml as cut off, the PIRADS>3 revealed the sensitivity and specificity of 85.7% and 61.5%.

Conclusion

The PIRADS V2.1 category 4-5 is highly accurate in detecting prostate carcinoma with improved accuracy of the category 3-5 when the serum PSA is used as an integral factor for the composite PIRADS category.

ULTRASOUND MEASUREMENT OF QUADRICEPS MUSCLE AS AN ASSESSMENT TOOL FOR SARCOPENIA IN HOSPITALIZED OLDER PATIENTS

Muhammad Nizamuddin Bin Othman¹, Mohammad Nazri Bin MD Shah², Terence Ong³

^{1, 2} Department of Biomedical imaging, Faculty of Medicine, University Malaya,

³ Department of Medicine, Faculty of Medicine, University Malaya

Keywords: Sarcopenia, SARC-F, SARC-CalF, Calf Circumference, Ultrasound Quadriceps

Background

Sarcopenia is defined as 'age-related loss of muscle mass, reduced muscle strength, and/or diminished physical performance'. Ultrasound can be used to assess muscle mass, specifically the quadriceps femoris. This study aimed to examine the relationship between the risk of sarcopenia among hospitalized older patients and quadriceps muscle using ultrasound.

Methodology

A single-centre prospective study involving 40 participants aged ≥ 65 who were admitted to the medical ward between June 2021 and July 2022. Ultrasound measurements of quadriceps muscle were taken, including quadriceps muscle layer thickness (QMLT), rectus femoris cross-sectional area (RFCSA), pennation angle (PA), and fascicle length (FL). Participants were assessed for sarcopenia risk using SARC-F (score ≥ 4) and SARC-calF (≥ 11).

Results

The mean age was 75.9 (± 7.0) years, 25(62.5%) were female, and majority being Malay (17,42.5%). Mean duration of scan was 1.5 days from admission with mean time was 8.6 minutes. SARC-F identified 21(52.5%) at risk, SARC-calF 22(55.0%), and calf circumference 25(62.5%). No difference in age, gender, ethnicity (except Malay, p-value:0.021) and body mass index (except SARC-calF, p-value:0.016) between those at risk and not at risk. Statistically significant relationship between SARC-calF and QMLT (No risk: mean (SD): 2.55 ± 0.66 , at risk: 1.99 ± 0.54 , 95% CI: 0.559, p-value: 0.005), RFCSA (No risk: 3.37 ± 1.10 , at risk: 2.49 ± 1.18 , 0.887, 0.02), and PA (No risk: mean (SD): 13.56 ± 3.25 , at risk: 10.34 ± 2.65 , 3.222, 0.002). No significant associations were observed with SARC-F.

Conclusion

Ultrasound quadriceps muscles provides a possible method to identify older hospitalised patients at risk of sarcopenia.

COMPUTED TOMOGRAPHY AND MAGNETIC RESONANCE IMAGING OF HYDATID CYSTS: A CASE SERIES IN AFGHANISTAN

Abdul Qadir, QADER

1. Radiology Department of Herat Medical Faculty, Herat University, Herat, Afghanistan. 2. Section Global Health, University Hospital Bonn, Venusberg Campus 1, 53127 Bonn, Germany

Keywords: *Hydatid Cysts, Case Series*

Abstract

Hydatid cysts, caused by the parasitic tapeworm *Echinococcus*, can manifest in various organs. Different sizes and shapes of hydatid cysts may create diagnostic challenges. Although ultrasound imaging with high resolution is the first choice for diagnosis, it rarely leads to a definite diagnosis. We describe the varying imaging findings seen in 10 cases of hydatid cysts on computed tomography (CT) and magnetic resonance imaging (MRI) encountered in Afghanistan from 2021 to 2024. In our cases, hydatid cysts were found in the liver, brain, orbit, chest, spleen, kidney, spine and muscle. CT is particularly valuable for osseous organ involvements and best shows cyst wall calcification. MRI can differentiate HD from neoplasms and is preferable in biliary or neural involvements. Familiarity with typical clinical presentation, CT scan and MR imaging findings of hydatid cysts in these sites facilitate the radiologic diagnosis and guiding timely intervention.

INTERPRETATIVE PERFORMANCE OF OPPORTUNISTIC SCREENING DIGITAL BREAST TOMOSYNTHESIS IN A TERTIARY CARE HOSPITAL

Dr Lim Shu Syi¹, Prof Dr Kartini R¹, Dr Leong Wai Ling¹
Biomedical Imaging Pusat Perubatan Universiti Malaya

Keywords: Breast cancer, Digital breast tomosynthesis, Full film digital mammogram, screening

Background

In Malaysia, breast carcinoma contributes to 8418 (32.9%) of all newly diagnosed cancers among women in the year 2020. Screening mammography has 30 – 40% relative reduction in breast cancer mortality. Unfortunately, sensitivity of mammography decreases 30 - 48% in women with dense breasts. Digital breast tomosynthesis (DBT) is an advanced imaging technique used for diagnosing and screening breast lesions, particularly in dense breasts. Therefore, this study aims to assess the diagnostic accuracy of DBT in combination with full film digital mammogram (FFDM).

Methodology

Retrospective study which recruits women underwent DBT at the Department of Biomedical Imaging, University of Malaya Medical Centre (UMMC) in year 2019. These include opportunistic screening, targeted screening and diagnostic mammograms. Histological diagnosis was obtained from BIRADS 4 and 5 lesions and analysis was done. Cancer detection rate (CDR), biopsy rate (percentage of biopsies performed) and positive predictive value (PPV) for biopsy (number of malignancies from histopathology test) were calculated.

Results

A total of 1064 patients were included, ranging from 30 to 98 years old. Of these, 869 women were screening (82.65%), 108 targeted screening (10.1%) and 87 diagnostic (8.2%) examinations. Biopsies for suspicious lesions were carried out for 43(5%)in opportunistic screening, 17(15.8%) in targeted screening and 50 (57.5%)in diagnostic group. The PPV for biopsies was 39.5 % in the opportunistic screening group, 29.4% in targeted screening group and 44% in diagnostic group respectively. 434 (40.7%) of the patients were in BIRADS density C and D category. 141 (13.1%) and 489 (45.9%) patients were in BIRADS density A and B respectively. 19 out of 44 (43%) cancer detected in dense breast (BIRADS density C and D).

Conclusion

DBT improves the diagnostic accuracy of mammography compared to FFDM as evidenced by higher CDR and PPV for biopsy.

MAMMOGRAPHIC SURVEILLANCE FOR BREAST CANCER SURVIVORS: A SYSTEMATIC REVIEW AND META-ANALYSIS

Ajeng VI1-3, Lina C1, Afdina MGF4, Afina ALK4, Dhite BN2,5

1Department of Radiology, Faculty of Medicine, Public Health and Nursing, Universitas Gadjah Mada, Yogyakarta, Indonesia

2Clinical Epidemiology and Biostatistic Unit (CEBU), Faculty of Medicine, Public Health and Nursing, Universitas Gadjah Mada, Yogyakarta, Indonesia

3Department of Health Sciences, University of Groningen, University Medical Center Groningen, Groningen, the Netherlands

4Faculty of Medicine, Public Health, and Nursing, Universitas Gadjah Mada, Indonesia

5Department of Internal Medicine, Faculty of Medicine, Public Health and Nursing, Universitas Gadjah Mada, Yogyakarta, Indonesia

Keywords: *Mammography, Breast Cancer, Mortality, Surveillance, Cancer Survivors*

Background

The number of breast cancer survivors has significantly increased due to the success of treatment, which has improved the clinical outcomes for patients. Despite recommendations for annual mammograms among survivors, few studies have explored into whether mammography lowers the risk of death in the post-treatment years. This review aimed to investigate the efficacy of mammographic surveillance in reducing mortality among breast cancer survivors.

Methodology

We conducted a systematic search at the Cochrane Central Register of Controlled Trials, Medline, and Scopus. Two reviewers screened the titles and abstracts of all identified articles and then selected relevant studies through full-text reviews. Studies on mortality outcomes associated with mammographic surveillance in breast cancer survivors were included. Data were extracted, and a meta-analysis was performed using the statistical software R. The risk of bias was evaluated using New-castle Ottawa Scale.

Result

From a total of 1,643 studies, we identified six eligible studies. Five studies exhibited a low risk of bias, while one showed a moderate risk. Five studies were finally included in the meta-analysis (N=2,514) and revealed that mammography surveillance reduced the odds of mortality by 50% (OR 0.50; 95% CI 0.27, 0.92) compared to cases without surveillance. There was high heterogeneity in the meta-analysis ($I^2=92\%$), possibly due to variations in intervention delivery (e.g. frequency, intensity) and outcome measures (e.g. breast cancer mortality, all-cause mortality).

Conclusion

Mammographic surveillance significantly reduced the mortality for breast cancer survivors, making post-treatment follow-up essential in their care.

ACCURACY OF MRI IN DETECTING 1P/19Q CO-DELETION STATUS OF GLIOMAS: A SINGLE-CENTER RETROSPECTIVE STUDY

Fatima Mubarak

Radiology Department, Aga Khan University Hospital, Karachi. Pakistan

Keywords: *Magnetic Resonance Imaging, 1p19q Co-Deletion, Gliomas*

Background

Oligodendrogliomas, in the frontal lobe's white matter, are reshaped by molecular markers like isocitrate dehydrogenase mutations and 1p/19q co-deletion, influencing outcomes. Despite initial indolence, these tumors pose a significant risk, with median survival of 10-12 years. Non-invasive alternatives, such as magnetic resonance imaging (MRI) for assessing T2-fluid-attenuated inversion recovery (FLAIR) mismatch and calcifications, provide insights into molecular subtypes and aid prognosis. Our study explored these features to predict the oligodendroglioma status and refine patient management to improve outcomes.

Methodology

In this retrospective study, patient undergoing MRI, revealing low-grade gliomas. Surgical biopsy and 1p/19q fluorescence in situ hybridization confirmed the co-deletion status. MRI was used to assess various morphological features. Statistical analyses included x2 tests, Fisher's exact tests, Kruskal-Wallis tests, and binary logistic regression models, with significance set at $p < 0.05$.

Results

Seventy-three patients (median age, 37 years) were stratified according to 1p/19q co-deletion. Most (61.6%) 18-40 years old and mostly male (67.1%). Co-deletion cases, primarily frontal lobe lesions (67.6%), unilateral (88.2%), 55.9% non-circumscribed margins and 58.8% ill-defined contours. Smooth contrast enhancement and no necrosis were observed in 48.1% of 1p/19q co-deletion cases. Logistic regression analysis showed a significant association between ill-defined/irregular contours and 1p/19q co-deletion. Fisher's exact test confirmed this but raised concerns about the small sample size influencing the conclusions.

Conclusion

This study established significant link between glioma tumor contour characteristics, particularly irregular and ill-defined contours, and likelihood of 1p/19q co-deletion. Our findings underscore the clinical relevance of using tumor contours in treatment decisions and prognosis assessments.

AI IN MAMMOGRAPHY IN AN OPPORTUNISTIC SCREENING AND DIAGNOSTIC CLINICAL SETTING

Nazimah AM¹, Marlina Tanty RH¹, Shamsiah AH¹, Kartini R²

1 Department of Radiology, Faculty of Medicine, Universiti Teknologi MARA, Jalan Hospital, 47000, Sungai Buloh, Selangor

2 Department of Biomedical Imaging, Faculty of Medicine, Lembah Pantai, 50920, Kuala Lumpur

Keywords: *Mammography; Breast; Neoplasm; Artificial Intelligence*

Background

Artificial intelligence (AI) has the potential to revolutionize breast cancer screening and diagnosis by compensating the limitations of mammography. This study assesses the efficacy of AI in mammography for combined screening and diagnosis in a clinical context.

Methodology

A retrospective analysis was conducted on 543 mammograms. Three breast radiologists independently interpreted the mammograms in two sessions: one without AI support and one with AI assistance. Assessment criteria included breast density, BI-RADS categories, and diagnostic parameters such as accuracy, sensitivity, specificity, positive predictive value (PPV), negative predictive value (NPV), and the rate of unnecessary biopsies.

Results

Among the 543 mammograms, 69.2% revealed detected lesions, leading to biopsies in 25% (n=136), resulting in 48.5% benign and 51.5% malignant cases. There was substantial agreement between radiologists and AI in assessing breast density ($\kappa = 0.606$, $p < 0.001$) and BI-RADS categories ($\kappa = 0.74$, $p < 0.001$). Sensitivity, specificity, PPV, and NPV for radiologists alone, radiologists with AI, and AI alone were 81.9%, 90.4%, 56.0%, and 97.1%; 81.0%, 93.1%, 55.5%, and 97.0%; and 90.0%, 76.5%, 36.2%, and 98.1%, respectively. The AI reduced unnecessary biopsies, particularly in BI-RADS 4 lesions. The rate of unnecessary biopsies decreased from 16.5% (n=22/136) without AI to 12.5% (n=17/136) with AI for BI-RADS 4a and from 2.9% (n=4/136) without AI to 2.2% (n=3/136) with AI for BI-RADS 4b, indicating reductions of 4.0% and 0.7%, respectively.

Conclusion

AI software demonstrates potential in enhancing the accuracy of breast lesion diagnosis, thereby improving diagnostic performance in opportunistic screening and diagnostic examinations.

ACUTE ACL INJURY RELATIONSHIP WITH INCREASED VASTUS MEDIALIS TO SEMIMEMBRANOSUS CROSS-SECTIONAL RATIO AND ASSESSING OTHER CONCURRENT INJURIES USING WORMS SCORE AS A TOOL: A CASE CONTROL RETROSPECTIVE STUDY

Shaukani, M.A.; Rozalli, F. I.; Rahmat, K.; Fadzli, F.

Bio-medical Imaging, University Malaya, Jalan Prof Diraja Ungku Aziz, Kuala Lumpur, Malaysia.

BACKGROUND

This study aims to evaluate the vastus medialis (VM) with semimembranosus muscle (SM) cross-sectional area (CSA) ratio in cases of ACL tear with control group, and secondary degenerative changes using WORMS score.

METHODOLOGY

This is a single-centred retrospective cross-sectional study of 50 patients with ACL tears and another group of 50 control patients in the University Malaya Medical Centre (UMMC) from the 1st of June 2021 to the 31st of October 2022. The VM and SM CSA ratio were measured in both case and control groups, and WORMS score was used to assess degenerative changes and concurrent knee injuries.

RESULTS

This study reveals that there is no statistically significant difference in the VM: SM CSA ratio between the case and control group ($p=0.596$), contradicts the findings of a study conducted by Weischhoff et al. However, a significant number of ACL tear patients demonstrate degenerative and other concurrent intra-articular injuries such as in menisci (78%), ligaments (60%), and synovitis (70%). In addition, there were degenerative alterations including cartilage abnormalities (44%), bone lesions (48%), bone attrition (36%), and osteophytes (36%). The majority of the changes occurred at the medial femoral-tibial joint (56%), followed by the lateral (56%) and patellofemoral (52%) joints.

CONCLUSION

In summary, while the study did not establish a statistical significance in the VM:SM CSA ratio or its correlation with ACL tears, it reveals important insights into the concurrent injuries that can occur with ACL tear and degenerative changes, within the intra-articular knee structures.

BREAST MRI IMAGING FEATURES IN INVASIVE BREAST CANCER AND ITS RADIOMICS SIGNATURE AS AN IMAGING BIOMARKER

Nazimah Ab Mumin¹, Chuin-Hen Liew², Song-Quan Ong³, Marlina Ramli Tanty Hamid¹, Hsiu Ding Wong⁴, Kartini Rahmat⁴, Kwan Hoong Ng⁴

1. Department of Radiology, Faculty of Medicine, Universiti Teknologi MARA, Malaysia

2. Hospital Tuanku Ampuan Najihah, Negeri Sembilan, Malaysia

3. Institute For Tropical Biology and Conservation, University Malaysia Sabah, Kota Kinabalu, Sabah, Malaysia

4. Department of Biomedical Imaging, Faculty of Medicine, Universiti Malaya, Malaysia

Objectives

Accurate subtyping of breast cancer is essential. This study investigated visual analysis and machine learning of MRI breast features with the breast cancer molecular subtype.

Methods

This retrospective study included MRI images of treatment-naive patients with invasive breast carcinoma. Four MRI sequences were analysed: T1-weighted, T2-weighted, STIR/TIRM, and T1-weighted post-contrast. Breast MRI features were recorded based on ACR-BIRADS criteria. Associations between MRI features were analysed in relation to breast cancer subtypes, determined via immunohistochemistry (IHC). Texture features were extracted and trained with a classifier algorithm to identify the best predictors for each subtype.

Results

The study included 194 patients: 41.8% Chinese, 40.7% Malay, and 17.5% Indian, with subtypes including 71.6% luminal-like, 12.9% HER-2 enriched, and 15.5% Triple-negative breast cancer (TNBC). TNBC was associated with rim enhancement ($p=0.002$) and peritumoral oedema ($p=0.004$). HER-2 tumours were associated with larger size ($p=0.041$). Luminal-like cancer was associated with irregular shape ($p=0.005$) and circumscribed margins ($p=0.003$). For machine learning, 162 cases were analysed. The texture feature included 303 variables, and feature selection used a hybrid Random Forest (RF) and Recursive Feature Elimination (RFE) algorithm. Using 5-fold cross-validation, the top 10 features for each subtype were selected to maximize AUROC. Redundant features were removed, resulting in 5 predictive variables for luminal-like, 5 for HER-2, and 4 for TNBC. The AUROC was 0.770 for luminal, 0.650 for HER-2, and 0.747 for TNBC when combining radiologists' assessments and texture features.

Conclusion

Specific MRI features from visual assessment and radiomics were identified to differentiate breast cancer molecular subtypes.

ESTABLISHING THE FIRST NEURORADIOLOGY SERVICES IN HERAT, AFGHANISTAN

Abdul Qadir, QADER

1. Radiology Department of Herat Medical Faculty, Herat University, Herat, Afghanistan.

2. Section Global Health, University Hospital Bonn, Venusberg Campus 1, 53127 Bonn, Germany

Keywords: *Neuroradiology, Low-Income Country, Afghanistan*

Background

Radiology is one of the underdeveloped medical fields within the healthcare landscape in Afghanistan. The diagnostic imaging services in local hospitals are limited to basic modalities. In 2022, the first state-of-the-art diagnostic and medical imaging centre was established in Herat, Afghanistan by a radiologist upon returning from Malaysia for his specialization in Radiology.

Methodology

Neuroradiology service is one of the first services to be provided by the imaging centre due to a severely unmet need within the region. We present the detailed establishment process from the conceptualization to the actualization phases. The neuroradiology cases are reported by a resident radiologist and a radiologist working off-site via telemedicine and interventional cases performed with cooperation of neurosurgeons.

Results

MRI, CT, CTA of the brain, spine, head and neck, and cerebral angiograms are some of the neuroradiology services currently available. To date, the average number of neuroradiology imaging performed daily and monthly are 15 and 360 cases respectively. The center also works closely with the Faculty of Medicine, Herat University to provide training sessions to students in various disciplines.

Conclusion

The first neuroradiology service was successfully established in Herat, Afghanistan in 2022 after overcoming challenges in terms of lack of funding, qualified healthcare workers and technical support. Continuous collaboration with local and international organizations are required to ensure the provision of a sustainable neuroradiology service and to fulfil our aspiration to provide interventional neuroradiology services to the local community.

RADIOLOGICAL AND CLINICAL PROGNOSTIC FACTORS IN ADULT INTRACRANIAL TUBERCULOSIS

Andrew Leslie Lee¹, N Ariana Azlee¹, Jeannie Hsiu Ding Wong², Nur Safira Abd Isa², Norlisah Ramli²

¹Faculty of Medicine, University of Malaya, Kuala Lumpur, Malaysia, ²Department of Biomedical Imaging, University of Malaya Medical Centre, Kuala Lumpur, Malaysia

Keywords: Intracranial Tuberculosis, Imaging, Prognostic Factors

Background

Intracranial tuberculosis (TB) is the most severe form of extra-pulmonary TB, carrying significant morbidity and mortality. Our study examined factors influencing outcomes in these patients.

Methodology

This retrospective study included all patients diagnosed with intracranial TB at University Malaya Medical Centre (2010-2020) using the Lancet consensus criteria. Clinical, laboratory and radiological (CXR/CT/MRI) findings on admission were identified. On brain imaging, presence of tuberculomas, enhancement pattern, hydrocephalus and infarction were assessed. Findings were compared according to functional outcome on the modified Rankin scale (mRS) at 90 days (good: mRS 0-2, poor: mRS 3-6), using the Fisher's exact test and Mann-Whitney test (p values < 0.05 considered significant). Correlation with functional outcomes was done using logistic regression. Cases without imaging were excluded.

Results

This study included 31 adults diagnosed with intracranial TB (median age: 37 years, range: 18-67 years). Poor functional outcomes were observed in 51.61% patients and were independently associated with lack of BCG inoculation (adjusted odds ratio (aOR) 8.170, 95% CI 1.130-59.064) and abnormal CXR (aOR 7.619, 95% CI 1.129-51.41). We found significant differences between good and poor outcomes in patients with cerebrospinal fluid (CSF) lymphocytes (median: 91.5% vs median: 38%), CSF polymorphs (median: 8.5% vs median: 52%) and cerebral infarction (0% vs. 100%).

Conclusion

Poor functional outcomes in adults with intracranial TB were associated with lack of BCG inoculation and an abnormal CXR. Cerebral infarction was significantly higher in patients with poor outcomes. These findings may guide treatment optimisation.

SPIGELIAN HERNIA: A RARE CASE PRESENTATION AND REVIEW LITERATURE

Ramanathan SRM

Department of Radiology, KPJ Damansara, Petaling Jaya, Selangor, Malaysia

Keywords: *Acute abdomen, Hernia, Spigelian Hernia*

Spigelian hernia is an uncommon variety of abdominal wall hernia which has a probability of 0.1-2% of occurrence. 172-year-old female patient with no known medical history complained of extreme abdomen pain since the day before the diagnosis. The pain was at the lower side of the abdominal . She was admitted when there was no cessation of the pain. An abdominal CT scan was done and showed Spigelian hernia. Given her age and fragility of the situation, the patient was suggested laparoscopic repair of Spigelian hernia. Spigelian hernia occurs in the abdomen and is the rarest form of all abdominal hernias. Clinically detecting hernia is not an easy task and imaging is helpful.

IMAGING MANIFESTATIONS AND COMPLICATIONS OF ODONTOGENIC INFECTIONS: AN ILLUSTRATIVE REVIEW

Alice Kwok Yan LI¹, Elva On Wa NG¹, Kenneth Hoi Ming KWOK¹

¹Department of Radiology, Kowloon West Cluster Hospitals, Hong Kong

Keywords: *Odontogenic Infection, Head And Neck Infection, Complications*

Abstract

Odontogenic infections are common conditions that harbour potential risk of significant morbidity if left untreated. Imaging plays a crucial role in the evaluation and management of these infections by facilitating the identification of infection source, allowing prompt detection of associated complications and determining the extent of involvement. Through illustrative cases, we will discuss the characteristic imaging features of complications such as cellulitis, abscess formation, Ludwig's angina, airway obstruction and necrotizing fasciitis. Furthermore, we will explore and elucidate the routes in which infection can extend from the oral cavity to the paranasal sinuses, orbits, intracranial and deep neck spaces, as well as down to the mediastinum. By familiarizing clinicians and radiologists to the imaging manifestations of odontogenic infections and emphasizing the anticipation in pathway of spread, we aim to enhance early recognition and enable timely intervention to prevent development of life-threatening complications.

ATYPICAL PRIMARY CNS LYMPHOMA, A GHOST TUMOUR

Muhammad Aminuddin, A¹; Asiah ZA²; Izzat Arslan CR¹; Shahizon Azura MM¹

¹Radiology Department, Hospital Canselor Tuanku Muhriz, Jalan Yaacob Latiff, Bandar Tun Razak, 56000, Kuala Lumpur, Malaysia, ²Radiology Department, Hospital Putrajaya, Presint 7, 62250 Putrajaya, Malaysia.

Keywords: *Atypical Primary CNS Lymphoma, MRI, Oncology*

Abstract

Atypical imaging characteristic of lymphoma often leads to delay in diagnosis and treatment initiation. Non enhancing CNS lymphoma is the most rarely reported, occurring at an incidence of 1%. We report a case of elderly woman, presented with forgetfulness without other significant clinical neurological. MRI brain revealed diffuse white matter changes in both hemisphere without any focal area of enhancement. This is highlighting that PCNSL should be considered even when non-enhancing, diffuse white matter lesions are seen on MRI.

LEPTOMENINGEAL METASTASES IN NEURO-ONCOLOGY: IT'S ALL ABOUT TIMING

Charbel Saade

University of College Cork, Ireland

Keywords: *Magnetic Resonance Imaging, Leptomeningeal Metastases, Gadolinium*

Background

Knowledge of the patterns and mechanisms of gadolinium enhancement facilitate radiologic differential diagnosis especially when understanding the mechanism of blood-brain barrier.

Methods

Brain enhancement is related to both intravascular and extravascular gadolinium enhancement. Leptomeningeal (pia-arachnoid) enhancement is present in meningitis and meningoencephalitis. Superficial gyral enhancement is seen after reperfusion in cerebral ischemia, during the healing phase of cerebral infarction, and with encephalitis. Nodular subcortical lesions are typical for hematogenous dissemination and may be neoplastic (metastases) or infectious (septic emboli).

Results

Postcontrast FLAIR MRI sequences have been shown to be valuable in the detection and evaluation of different leptomeningeal diseases, including subarachnoid hemorrhage, meningitis, and infectious meningitis. The nulling of the CSF signal due to the inversion time facilitates an optimized delineation of hyperintense pathology adjacent to the CSF in the sulcal and leptomeningeal space while the T1 shortening in FLAIR sequences is responsible for the highly sensitive delineation of pathologic contrast enhancement following application of gadolinium.

Conclusion

Understanding the classic patterns of lesion enhancement - and the radiologic-pathologic mechanisms that produce them—can improve image assessment and differential diagnosis.

DIAGNOSTIC ACCURACY OF HYPERDENSE ARTERY SIGN IN EARLY DETECTION OF MIDDLE CEREBRAL ARTERY INFARCTION: A CROSS-SECTIONAL VALIDATION STUDY

Fatima Mubarak

Radiology Department, Aga Khan University Hospital, Karachi. Pakistan

Keywords: *Hyperdense Artery, Middle Cerebral Artery Infarction, Diagnostic Accuracy*

Background

Hyperdense middle cerebral artery sign (HMCAS) on a non-enhanced multidetector computed tomography (MDCT) scan is considered an important radiological marker in detecting acute arterial thrombotic occlusion, and it is one of the earliest signs of ischemic cerebrovascular accident (CVA). This finding has been observed within 90 min of symptom onset. Modern approaches to patients with cerebral infarction emphasize early diagnosis and management.

Methodology

A total of 140 patients aged 35–70 years, referred to the radiology department of Aga Khan University Hospital with clinical suspicion of acute cerebral infarction, were included. After clinical suspicion of acute infarction, the patient underwent an initial complete MDCT scan of the brain, which was performed using Aquilion ONE 640 slice MDCT (Toshiba Medical Systems, Japan). Consultant radiologists, with a minimum of 5 years of experience in MDCT brain imaging, interpreted the images. Follow-up examination with MRA within 24 h was performed to confirm the diagnosis of MCA infarction.

Results

Overall sensitivity, specificity, positive predictive value, negative predictive value, and diagnostic accuracy of HMCAS in the early detection of MCA infarction on non-contrast-enhanced MDCT scan using MRA as the gold standard for definitive diagnosis was 96.20%, 93.44%, 95.0%, 95.0%, and 95.0%, respectively.

Conclusion

This study concluded that the diagnostic accuracy of hyperdense artery signs in the early detection of MCA infarction on non-contrast-enhanced MDCT scans is very high.

ASSESSMENT PRECISION OF CT PERFUSION IMAGING IN THE DETECTION OF ACUTE ISCHEMIC STROKE: A SYSTEMATIC REVIEW AND META-ANALYSIS

Fatima Mubarak

Radiology Department, Aga Khan University Hospital, Karachi. Pakistan

Keywords: *Ischemia, CT Perfusion, Metaanalysis*

Background

Stroke, a prevalent medical emergency, comprises ischemic and hemorrhagic subtypes, with acute ischemic stroke (AIS) being predominant type. The application of computed tomography perfusion (CTP) imaging has gained prominence due to its rapidity and accessibility in stroke evaluation.

Methodology

This study systematically reviews and conducts a meta-analysis of existing literature to assess the diagnostic accuracy of CTP in detecting AIS and predicting hemorrhagic transformation (HT). Employing Preferred Reporting Items for Systematic Reviews and Meta-Analyses (PRISMA) guidelines, an extensive search was conducted across electronic databases and relevant radiology journals. Studies conducted between 2007 and 2023 that fulfilled predetermined inclusion criteria underwent quality assessment using the Quality Assessment of Diagnostic Accuracy Studies 2 (QUADAS 2) tool. Cochrane diagnostic accuracy tools were used for data extraction. Thirteen studies involving a total of 1014 patients were included in the analysis.

Results

The diagnostic performance of CTP in predicting HT demonstrated high sensitivity (86.7%) and moderate specificity (77.8%), resulting in an overall accuracy of 79.1%. The negative predictive value (NPV) (92.9%). The positive predictive value (PPV) was (60.3%), highlighting the need for clinical context when making thrombolysis decisions. The false positive rate was 16.2%, while the false negative rate was minimal (9.8%).

Conclusion

The findings of this study emphasize the promising diagnostic accuracy of CTP imaging in predicting HT subsequent to AIS.

**UNVEILING THE NEUROVASCULAR ODYSSEY: A CASE OF PERSISTENT TRIGEMINAL ARTERY MIMICKING
STROKE-LIKE SYMPTOMS IN A NEWLY DIAGNOSED HYPERTENSIVE PATIENT**

Nurain M1, Nurhayati M2, Naveen R3, Thajunnisa H4

KPJ Damansara Specialist Hospital

Keywords: *Persistent Trigeminal Artery*

Persistent Primitive Trigeminal Artery (PPTA) is a rare vascular anomaly found in a small percentage of individuals, connecting the carotid and vertebrobasilar arteries. Originating during fetal development, this anomaly can persist into adulthood, deviating from the normal regression of fetal vessels. It often follows an atypical course, running along the trigeminal nerve or passing through specific anatomical structures. Associated with hypoplasia in nearby arteries, it can impact cerebral blood flow dynamics, potentially leading to complications like inadequate perfusion and thrombosis. In a recent case study of a 58-year-old male with left-sided body numbness, advanced imaging revealed a PPTA. This emphasizes the importance of understanding such anomalies, especially in cases with unusual neurological symptoms, as they may contribute to conditions like vertebrobasilar insufficiency. Recognizing the role of PPTAs in neurological presentations is crucial for accurate diagnosis and management, particularly in patients with vascular risk factors like hypertension and dyslipidemia.

PRIMARY RENAL SYNOVIAL SARCOMA PRESENTING AS COMPLEX RENAL CYST COMPLICATED WITH A LARGE PERINEPHRIC COLLECTION- A RARE CASE

Muhamad Asyraf Jamaluddin^{1,4}, Iqbal Hussain Rizuana^{1,4}, Marhani Yati Marmono², Noraini Mohd Dusa³

1 Department of Radiology, Faculty of Medicine, Universiti Kebangsaan Malaysia

2 Department of Radiology, Hospital Kuala Lumpur

3 Department of Pathology, Hospital Kuala Lumpur

4 Hospital Canselor Tuanku Muhriz

Keywords: *Renal Synovial Sarcoma; Monophasic Synovial Sarcoma, Perinephric Collection; Complex Renal Cyst; Computed Tomography Imaging.*

INTRODUCTION: Primary renal synovial sarcoma (PRSS) is an aggressive tumor with incidence less than one percent of all adult malignancies. Very few reports have tackled this tumor. REPORT: 36-year-old female, presented with left sided abdominal pain and palpable mass. Initial multiphase Computed Tomography (CT) of kidney showed complex left lower pole renal cyst, with new large complex non-enhancing subcapsular collection in the subsequent CT, which were persistent despite drainage and antibiotic. Fluid cytology revealed no malignancy. Patient underwent left radical nephrectomy in view of persistent subcapsular collection despite drainage and antibiotic, and tissue biopsy showed unexpected diagnosis of monophasic SS. Ifosfamide- and doxorubicin-based chemotherapy regimens was commenced. Surveillance CT showed no recurrence or metastasis. CONCLUSION: PRSS, although uncommon, should be considered, especially in young adults who present with complex cystic renal lesion or persistent perinephric collection. Surgical extirpation followed by ifosfamide- and doxorubicin-based chemotherapy regimens are the treatment of choice.

CONTRAST-ENHANCED MAMMOGRAPHY AND MRI IN BREAST CANCER DIAGNOSIS AND EVALUATION

Kartini Rahmat¹, Thum WQ¹, Farhana Fadzli¹, Wong Yee Voon¹, Lee Sui Cheng¹, Nazimah AB Mumin², Marlina Ramli¹, Anushya V¹, Leong Wai Ling¹

¹*Biomedical Imaging, Faculty of Medicine, Universiti Malaya, Malaysia*

²*Dept of Radiology, Universiti Teknologi MARA, Malaysia*

Background

To review the application and demonstration of preoperative evaluation breast cancer using contrast-enhanced mammography (CEDM) and breast MRI. CEDM has been shown to be non inferior to breast MRI in detecting breast lesions (diagnostic accuracy of 97% and 96%, respectively). This pictorial assay seeks to elucidate its role in diagnostic performance guiding treatment planning and ultimately improving patient outcomes in the management of breast cancer.

Learning Objective(s)

1. Understand the principles and technical aspects of CEDM versus breast MRI in the diagnosis of breast cancer.
2. Recognize the role of CEDM versus breast MRI in evaluating tumour size, extent, and multifocality/multicentricity in breast cancer staging.
3. Evaluate the potential impact of incorporating CEDM as an emerging modality into clinical practice on patient outcomes and treatment strategies.

Imaging Findings or Procedural Techniques

CEDM provides morphological and functional information of malignant lesions similar to breast MRI. Cancer and malignant tumour demonstrate rapid and disorganized growth, which results in increased angiogenesis and permeability.

The leaky vasculature in tumours can be highlighted in CEDM. In CEDM, iodine-based contrast material is injected intravenously two minutes before image acquisition. Subsequently, a pair of low energy (28– 32 kVp) and high energy (45kVp) images are acquired in quick succession while the breast remains compressed. Post-processing of the two images produces the recombined image where glandular tissue is suppressed and contrast uptake in breast lesion is highlighted.

Conclusion

CEDM is useful additional tool to allow improved assessment of Digital Mammography in selected cases. It is comparable to MRI in its ability to detect small lesions often obscured by conventional breast imaging. Further studies are required in the Asian population to further cement its place in the ever growing list of imaging modalities for women.

CHEST WALL DESMOID TYPE FIBROMATOSIS MIMICKING BREAST CARCINOMA - A CASE REPORT

W.A. Firdaus¹, Raihanah Haroon¹, Azaliana Bt Abdul Fuaat²

¹Department of Radiology, Sultan Ahmad Shah Medical Centre (SASMEC @IIUM) Kuantan, Pahang

²Department of Pathology, Sultan Ahmad Shah Medical Centre (SASMEC @IIUM) Kuantan, Pahang

Keywords: *Breast Imaging*

Fibromatoses, also referred to as desmoid tumors; are uncommon soft tissue tumors, which accounts for only 0.2% of breast neoplasms. We report a case of 47-years-old-lady presented with 2-months history of enlarging right breast lump. Mammogram revealed a high-density lesion only seen in MLO view. Ultrasound shows ill-defined lesion at 7-9 o'clock in position.. BIRADs category 4c was given. CT scan and MRI breast showed an irregular lobulated mass that arises from the right pectoralis muscle at the right upper quadrant of the chest wall with area diminished fat plane between the mass with the soft tissue. No enhancement in CT scan, however heterogeneously enhanced in MRI post contrast. In MRI dynamic post contrast curve shows Type 3 curve. Right breast mastectomy was performed due to its local aggressiveness and high rate of recurrence. Imaging is crucial for planning of treatment to delineating the lesion prior to surgical treatment.

A RARE CASE OF URACHAL MUCINOUS CYSTIC NEOPLASM

Ng WL1,3; A. Karim NK1,2

1 Department of Radiology, School of Medical Sciences, Health Campus, Universiti Sains Malaysia

2 Imaging Unit, Advanced Medical and Dental Institute, Universiti Sains Malaysia

3 Department of Radiology, Hospital Raja Permaisuri Bainun

Keywords: *Congenital Urachal Remnant, Urachal Cystic Neoplasm, Midline Abdominal Mass*

Congenital urachal remnant, which results from incomplete involution, predisposes to malignant transformation, predominantly adenocarcinoma. In contrast to adenocarcinoma, mucinous neoplasm of the urachus had a better prognosis if resected completely. Imaging features may overlap with other differential diagnoses and hence affect the management. An ultrasound examination was performed for a 50-year-old gentleman who presented with a lower abdominal mass which revealed a multicystic suprapubic mass with minimal curvilinear wall calcification and no solid component. No solid component nor Doppler signal demonstrated. Subsequent CT as a scan confirmed these findings which further delineated the relation of the mass with the umbilicus as well as the urinary bladder. Laparotomy and tumor excision was performed, confirming the attachment of the mass with the urinary bladder dome as well as extraperitoneal extension via paraumbilical defect. Histopathological examination (HPE) revealed a urachal mucinous cystic neoplasm of low malignant potential. The patient was well post surgery with no history of recurrence.

CANAL OF NUCK CYST: A RARE CAUSE OF INGUINAL SWELLING IN ADULT FEMALES

Nurul Amira, M1, Bushra J2; Nazimah AM3, Yahya MA4

1Department of Radiology, Faculty of Medicine, Universiti Teknologi MARA, Puncak Alam, Selangor, Malaysia,

2Department of Surgery, Faculty of Medicine, Universiti Teknologi MARA, Puncak Alam, Selangor, Country.

Keywords: *Canal Of Nuck, Cyst, Ultrasound, CT*

Introduction

Canal of Nuck cyst is seldom diagnosed in adult females, especially in Malaysia, with limited local literature on the topic. This case report aims to discuss the computed tomography (CT) features of Canal of Nuck cyst where MRI is unavailable and explore differential diagnoses for inguinal swelling in adult females [1].

Case Report

We present a 41-year-old woman with left inguinal discomfort and swelling. Ultrasound revealed a cystic lesion (**Figure A**), and CT confirmed a well-defined cyst anteromedial to the left femoral vessels (**Figure B**). Surgical exploration revealed a multiloculated cystic mass extending from the internal inguinal ring, confirming the diagnosis of Canal of Nuck cyst.

Conclusion

Although rare in females, cyst of the canal of Nuck should be considered in cases of groin swelling. While ultrasonography and MRI are preferred for evaluation, CT can provide valuable insights, especially when MRI is not accessible, aiding in accurate evaluation and management.

Reference

1. Brainwood, M., Beirne, G., & Fenech, M. (2020). Persistence of the processus vaginalis and its related disorders. *Australasian journal of ultrasound in medicine*, 23(1), 22–29.

THE CT QUADRATE LOBE FOCAL HOT SPOT SIGN IN SUPERIOR VENA CAVA OBSTRUCTION.

Nabila FM; Mohd Radhwan A

*Department of Radiology, Sultan Ahmad Shah Medical Centre (SASMEC) at IIUM,
Jalan Sultan Ahmad Shah, 25200 Kuantan, Pahang.*

Keywords: *Quadrature Lobe Focal Hot Spot Sign; CT scan; Superior Vena Cava, Obstruction*

“Quadrature lobe focal hot spot sign” refers to a radiological finding seen on contrast-enhanced computed tomography (CT) scans of the liver. Quadrature lobe is the medial segment of left hepatic lobe (segment IV). It was initially observed on ^{99m}Tc sulphur colloid scan of liver as focal area of increased radiopharmaceutical uptake and was diagnostic of superior vena cava (SVC) syndrome. In CT, this sign is characterized by contrast accumulation in segment IV of liver during arterial or early portal venous phases. Contrast enhancement during the arterial phase is often related to increased blood flow and vascularization in certain liver lesions, which can make them stand out and appear as ‘hot spot’ on imaging. Presented herein is our diagnostic experience of an incidental CT ‘Quadrature lobe focal hot spot sign’ in a case of SVC obstruction in an ESRF patient and to discuss the physiological cause and importance of this sign.

GIANT PENILE ELEPHANTIASIS FOLLOWING MULTIPLE CIRCUMCISIONS: A RARE COSMETIC AND FUNCTIONAL COMPLICATION

Muhammad Azri Silmi, A^{1,2}, Noor Diyana, O³, Nor Syahida, Mr²

¹*Department Of Radiology, School Of Medical Sciences, Health Campus, Universiti Sains Malaysia, 16150 Kubang Kerian, Kelantan, Malaysia.*

²*Department Of Radiology, Hospital Sultanah Bahiyah, 05460 Alor Setar, Kedah, Malaysia.*

³*Department Of Biomedical Imaging, Advanced Medical And Dental Institute, Universiti Sains Malaysia, Bertam, 13200 Kepala Batas, Pulau Pinang, Malaysia.*

Keywords: *Giant Penile Elephantiasis, Penile Lymphoedema, Circumcision, Complication*

Lymphoedema of external genitalia can be caused by infection, neoplasm, chronic inflammation or rarely congenital. This report describes a rare case of giant penile elephantiasis in a 50-year-old male who had a history of circumcision twice previously due to phimosis. Ten years after the second circumcision, he presented with progressive penile and scrotal swelling, along with an abnormally-shaped penis likely related to the prior surgical procedures. Magnetic resonance imaging (MRI) was performed to better understand the structural anatomy revealed extensive soft tissue thickening and loss of fascial planes throughout the glans and shaft of the penis, with the glans buried within the thickened tissue. Additionally, similar findings were identified in the scrotal region. This case highlights the potential for rare complication following circumcision, and the importance of considering past surgical history when evaluating patients with penile abnormalities.

ABDOMINAL PAIN WITH A TWIST: A RARE CASE OF OMENTAL TORSION

Dr Nur 'Adlena BA1, Dr Noorasikin BAH2, Dr Siti Aspalekha J3

1Department of Radiology, Kajang Hospital, Selangor, Malaysia, 2Department of Radiology, Kajang Hospital, Selangor, Malaysia, 3Department of Radiology, Kajang Hospital, Selangor, Malaysia

Keywords: *Omental torsion, omental infarction, CT scan, acute abdomen*

A 44-year-old male presented to the emergency department complaining of right upper quadrant pain and was initially diagnosed with perforated gastric ulcer (PGU). Abdominal computed tomography showed a whirling pattern of fatty streaks and vessels within the greater omentum, and surgery confirmed infarction of the omentum secondary to torsion. Because of its rarity and nonspecific clinical features, the diagnosis is seldom made preoperatively. We describe a patient with characteristic CT findings of omental torsion. Preoperative diagnosis is important since conservative management has been suggested and it was confirmed on computed tomography (CT) inferring that imaging plays an important role in identification and management of the disease due to mimic of clinical pictures of acute abdomen which can mislead the diagnosis.

RARE CASE OF GIANT SIGMOID DIVERTICULUM

Low JJ¹, Vithiya S², Siti AH³

¹Radiology Department, Hospital Sultan Ismail, Johor Bahru, Malaysia

Keywords: *Giant Sigmoid Diverticulum*

Colonic diverticulosis is a fairly common disease in elderly patients. However, a solitary giant colonic diverticulum is relatively rare. Herein, we are presenting this case of a 74 years old man who presented with abdominal pain and loose stool for 4 days. His abdominal radiograph showed a central large round air-filled structure in the pelvis. Colonic malignancy with bowel obstruction was suspected. Cross-sectional imaging showed a large air-filled saccular outpouching arising from the sigmoid colon confirming the diagnosis of giant sigmoid diverticulum. No signs of inflammation or perforation seen. Patient was managed conservatively. We are presenting this case for its unique radiological features and as it is the first of its kind in our center.

INTERNAL HERNIA THROUGH BROAD LIGAMENT DEFECT: A RARE CASE REPORT

Livania C¹, Nur Alfalailah MA¹, Fadzrie Azim FD¹

¹*Department of Radiology, Hospital Melaka, Melaka, Malaysia.*

Keywords: *Internal Hernia, Broad Ligament, Intestinal Obstruction*

Broad ligament herniation is rarely reported and constitutes only 4% of all internal hernias. Most internal herniation complicated with strangulation resulting in acute small bowel obstruction. A 45-year-old female, no previous surgical history, presented with intense colicky left iliac fossa (LIF) pain. Upon examination revealed tenderness over the LIF and suprapubic region. Blood test showed leucocytosis. Normal abdominal radiograph. Ultrasound showed ascites with stagnant bowel loops. Subsequently CECT Abdomen showed abnormal cluster of small bowel loops within pouch of Douglas with evidence of obstructed internal hernia and impending ischemia. An emergency laparotomy was performed. Intraoperative findings revealed defect in left broad ligament causing strangulation of small bowel. Bowel resection and left broad ligament hernia repair done. Post operatively patient recovered well. Patients with broad ligament hernia can present with wide spectrum of symptoms, ranging from none to acute bowel obstruction. The diagnosis is challenging with nonspecific clinical and radiographic findings.

References

1. L.C. Martin, E.M. Merkle, W.M. Thompson. Review of internal hernias: radiographic and clinical findings. *AJR Am. J. Roentgenol.*, 186 (2006), pp. 703-717.
2. Abin Sajan, MD, Hazim Hakmi, MD, Daniel W. Griep, BE, Amir H. Sohail, MD, Helen Liu, DO, and David Halpern, MD. Herniation Through Defects in the Broad Ligament. *JSLs*. 2021 Apr-Jun; 25(2): e2020.00112.

DECIPHERING THE PUZZLE: CHALLENGES IN DIAGNOSING CAECAL BASCULE WITH SMALL BOWEL DILATATION.

Jennyfer JL¹, Alex LTL¹

¹*Radiology Department of Hospital Sultan Ismail, Johor Bahru, Malaysia*

Keywords: *Caecal Bascule, Caecal Volvulus, Dilated Caecum, Intestinal Obstruction*

Caecal bascule, a rare subtype of caecal volvulus, involves the anterior folding of the caecum over the ascending colon at a horizontal axis. This condition can lead to complications namely small bowel obstruction (SBO) due to mechanical effects on neighbouring structures or incompetent ileo-caecal valve. Clinical manifestations, including abdominal pain, distension, vomiting, and constipation, closely resemble those of primary SBO. Prompt diagnosis and management are crucial to prevent complications like bowel ischemia or perforation. We present the case of a 65-year-old woman admitted for femur fracture, who developed abdominal distension during her hospital stay, plain radiograph revealed a markedly dilated caecum with dilated small bowels. Subsequent CT confirmed caecal bascule with SBO. She underwent an emergency laparotomy, which confirmed the diagnosis of caecal bascule with small bowel dilation. She subsequently underwent bowel decompression and caecopexy. Recognising this entity in acute abdominal presentations facilitates timely intervention and improved patient outcomes.

SPONTANEOUS HEMORRHAGE OF LEIOMYOMA– A TALE OF RARE LEIOMYOMA COMPLICATION

Nabilah K¹, Fazliza H¹

¹Department of Radiology, Hospital Sultanah Aminah, Johor Bahru, Malaysia

Keywords: *Bleeding, Leiomyoma*

Uterine fibroids are common benign tumors in women. Clinical manifestations are well known. Acute complications necessitating emergent surgical intervention are rare. We hereby report a case of 40-year-old female presented with an acute abdomen. CECT Abdomen revealed huge abdominopelvic mass with area of increasing hyperdensities at the lateral aspect of the mass with hemoperitoneum. During emergency exploratory laparotomy, the subserosal vein overlying a uterine fibroid was identified as the source of bleeding. Hemostasis secured by myomectomy. Spontaneous hemorrhage from uterine leiomyoma is extremely rare, but may lead to life-threatening conditions. Therefore, high index of suspicion should be considered in female patients with acute abdominal pain with underlying uterine fibroid to ensure early diagnosis and prompt treatment.

INCIDENTAL FINDING OF LITHOPEDION IN A PATIENT WITH VAGUE PELVIC SYMPTOMS

Muhammad FF¹, Zarifa Z²

Radiology Department, Hospital Tengku Ampuan Afzan, Jalan Tanah Putih, Kuantan, Malaysia

Keywords: *Mummified, Lithopedion, Ectopic Pregnancy.*

Abstract

A lithopedion is a rare phenomenon that results from a missed ectopic pregnancy. This condition is a rare occurrence of only 0.0054% in all gestations. In most cases, these are found incidentally during investigation for abdominal complaints. A 49 year old woman with three previous pregnancies presented with symptoms of abnormal vaginal bleed and abdominal pain. Her last child birth was more than 30 years ago. An ultrasound done by the gynaecology team showed a large calcified mass with hypoechogenicity within. A scheduled Pelvic CT later revealed a bulky uterus and a well-formed extrauterine mummified fetus within the pelvic cavity with no surrounding fat streakiness to suggest acute or chronic infection at the time. This case can serve as a contribution to further understanding this condition and has shown that a mummified fetus can be considered as a differential diagnosis in cases of calcified pelvic lesions among women.

COMPLIANCE OF THE USAGE OF WATER AS NEUTRAL ORAL CONTRAST IN CT ABDOMEN.

Liyana MZ; Mohd Nazlin K; Huzairah AP; Nurul Shamira MA

Department of Radiology, Hospital Sungai Buloh.

Keywords: Water, CT Abdomen, Neutral contrast

Background

Computed Tomography (CT) Abdomen is one of the most frequently done CT scan in our department apart from CT Thorax and CT Pelvis as they reveal many important findings especially in post trauma patient. Prior to CT scan, patient will be given intravenous, oral and rectal contrast according to the indication of examination. Oral administration of positive contrast agents containing Barium Sulphate or Iodine has become a standard practise in abdominal CT. However, many studies have shown that use of water as oral contrast give equivalent delineation of the bowel and similar detection rate for intestinal pathologies as positive contrast agent. Benefits such as water is tasteless and odourless while gastrograffin has unpleasant taste. Water is easily available too. The aim of this study is to achieve >95% usage of water as oral contrast in CT abdomen and the objective is to improve compliance to use water as oral contrast in CT Abdomen instead of positive contrast.

Methodology

The study is done retrospectively using random sampling of 150 patients during pre-intervention, 120 patients for first cycle and 100 patients for second cycle. Exclusion criterias are perforation, fistula and anastomotic leak cases.

Results

Results for pre-intervention only 28% used water, 1st cycle improves to 89% while 2nd cycle 99% used water as oral contrast. The outcome has led to patient and staff satisfactions also cost saving.

Conclusion

There is increase compliance to usage of water as neutral oral contrast compared to first cycle.

IMAGING FINDINGS OF PRIMARY PRIMITIVE NEUROECTODERMAL TUMOUR OF THE LIVER - A CASE REPORT

Philip TWI1, Ng WL2

Radiology Department, University Malaya Medical Centre, Lembah Pantai, 59100. Kuala Lumpur, Malaysia.

Keywords: *Primitive Neuroectodermal Tumor, Extraskkeletal Ewing Sarcoma, Focal Hepatic Lesion.*

Primitive neuroectodermal tumor (PNET) is a member of the Ewing's sarcoma family that is a highly aggressive tumour with poor prognosis. Although PNETs can occur in numerous solid organs especially from the musculoskeletal system, a primary hepatic PNET is extremely rare. We have a 77-year-old female, whose initial CT liver 5 phase showed an arterially enhancing segment 4 mass that was treated as hepatocellular carcinoma. Patient underwent selective internal radiation therapy (SIRT). First CT follow-up post-SIRT showed favourable response from the tumour. 6 months later, the patient presented with worsening abdominal pain. A repeat CT liver 5 phase showed a new large segment 6 liver lesion. Biopsy was performed for both the segment 4 and 6 liver lesions and histological diagnosis of primitive neuroectodermal tumour of the liver was made. In this case report, we discuss the serial imaging findings of PNET of the liver.

LIFE-THREATENING PULMONARY COMPLICATIONS FROM BREAST FILLER INJECTION

Noor Shahida MP, Jolene LAH, Quah SY

Department of Radiology, Hospital Pulau Pinang, Malaysia.

Keywords: *Hyaluronic Acid, Injectable Filler, Diffuse Alveolar Haemorrhage*

Breast augmentation is a common aesthetic procedure with various techniques have been described, including injectable filler such as hyaluronic acid(HA). However, life-threatening pulmonary complications from HA injection is not well known. We hereby report a case of a young patient who developed diffuse alveolar haemorrhage after receiving unlicensed HA filler injection. She presented to us with acute breathlessness. On questioning, she disclosed prior history of breast filler injections, with the last injection done on day of presentation. CT scan prior to ICU admission showed bilateral multifocal consolidations with surrounding ground glass opacities, predominantly in peripheral location. Bronchoscopy showed minimal hemorrhages at both lower lobes. She was treated symptomatically and responded well to steroid treatment. Interval CT at 2 months showed complete resolution of lung changes. This case report is to create awareness among medical practitioners regarding this possible complication, given the rising popularity of breast augmentation procedures among the public.

WUNDERLICH SYNDROME: A CASE REPORT

Retriani S¹, Sri I²

1 Radiology Department, Pelita Harapan University, Karawaci, Tangerang, Indonesia, 2Radiology Department, Medistra Hospital, Gatot Subroto, Jakarta, Indonesia.

Keywords: *Wunderlich Syndrome, Angiomyolipoma, Flank Pain*

Wunderlich syndrome is a rare condition that is potentially life-threatening spontaneous renal hemorrhage into subcapsular and perirenal spaces. A 39-year-old woman presented with sudden severe colic flank pain. Abdominal ultrasound revealed a heterogeneous echogenicity mass occupying the left kidney's superior pole, suspected to be an Angiomyolipoma. Contrast-enhanced CT scan showed a mixed density mass (solid, fat, and blood components) in the superior pole, measuring approximately 111 mm x 86 mm, with perirenal blood collection suggesting a partial rupture of an Angiomyolipoma. Surgery and histopathology confirmed our suspected diagnosis of a spontaneous rupture of Angiomyolipoma. Wunderlich syndrome typically presents with sudden severe abdominal pain due to the spontaneous rupture of Angiomyolipoma and bleeding into the subcapsular and/or perirenal space. Diagnosis usually involves imaging studies like ultrasound, CT, or MRI. In this case, immediate medical attention and imaging confirmed the diagnosis, underscoring the importance of prompt intervention for successful management.

RENAL VASCULAR ABNORMALITIES IN A MISSED RENAL MASS

Tan GX¹, Soon YY²

*Radiology Department, Hospital Sultan Idris Shah Serdang,
Selangor, Malaysia*

Keywords: *Arteriovenous Malformation, Renal Cell Carcinoma*

Introduction

Differentiating between renal arteriovenous malformations (AVM) from malignancy may be challenging due to similar clinical and imaging findings.

Abstract

We report a case of a 55 years old female presented with painless hematuria. Ultrasound showed hypoechoic left kidney mass with dilated, tortuous vessels and increased colour Doppler. Multiphase CT revealed multiple tortuous vessels in arterial phase in a background of relatively hypoenhancing renal parenchyma with early drainage into the IVC. Initially reported as renal AVM but upon multidisciplinary discussion concluded the hypoenhancing areas as a renal mass. Left radical nephrectomy shows a very vascular mass and HPE confirmed clear cell carcinoma tumour with renal sinus invasion, distant metastasis to left adrenal and distal pancreas, with left renal vein thrombus.

Conclusion

These conditions are great mimickers of each other and can coexist together. Detailed image interpretation and a high index of suspicion is needed to ensure accurately monitoring with proper treatment.

PLANTAR FASCIITIS TREATED WITH AUTOLOGOUS WHOLE BLOOD

KENNETH SHEAH

Musculoskeletal Radiology And Intervention, Imaging Consulting, Singapore

Keywords: *Autologous Whole-Blood; Corticosteroid; Methylprednisolone; Placebo; Plantar Fasciitis*

Interest in biological treatment in plantar fasciitis and plantar fascial tears has increased in recent years. This is a case report of a 30 year old footballer with plantar facial partial rupture treated with autologous whole blood injection, and managed weight bearing. Imaging eight weeks after initial treatment reveals bridging of tear gap, with corresponding improvement clinically. This is a significant finding, as autologous whole blood injection is cheaper than the more popular platelet rich plasma, and can be used as an alternative in selected patients.

MORPHOLOGY AND MORPHOMETRY EVALUATION OF ADULT COCCYX WITH MULTIDETECTOR COMPUTED TOMOGRAPHY IN SULTAN AHMAD SHAH MEDICAL CENTRE @IIUM

Nur AS¹, Ahmad RMR¹, Karimah HAA²

¹Department of Radiology, Sultan Ahmad Shah Medical Centre (SASMEC) @International Islamic University Malaysia (IIUM), ²Kuliyah of Medicine, IIUM, Jalan Sultan Ahmad Shah, Kuantan, Malaysia.

Keywords: *Coccyx (Cy), Morphology, Morphometry, Multidetector Computed Tomography (MDCT)*

Background

The coccyx is often considered functionally insignificant, resulting in a lack of data on its normal morphology and morphometry in vivo. This study aims to assess the morphology and morphometry of the coccyx among Malaysian adults who underwent MDCT at SASMEC @IIUM.

Methodology

A cross-sectional study was conducted on 300 adult CT images from November 2021 to November 2022. The morphology of the coccyx (vertebral count, segmental number, intercoccygeal joint fusion, and coccyx type) and morphometric measurements (sacrococcygeal angle, intercoccygeal angle, curved index of coccyx, and sacrum) were evaluated.

Results

The most common coccyx vertebral count was four with average number of coccygeal segments was three, with intercoccygeal fusion predominantly at the last intercoccygeal joint, mainly at the Cy3/Cy4 level. The most prevalent coccyx type was II. In terms of coccyx morphometry, the curved index of the coccyx and sacrum as well as mean sacrococcygeal angle and intercoccygeal angle reveals straighter and shorter coccyx in females compared to males. Significant gender differences were observed in the coccygeal vertebral count, number of coccygeal segments, curved index of the coccyx, sacrococcygeal angle, and intercoccygeal angle. However, no significant gender disparity was found across coccyx types or curved index of the sacrum.

Conclusion

Our study reveals common anatomical variations in coccyx morphology and morphometry within the Malaysian population which has comparable prevalence with other studies. These findings are essential for recognizing and understanding anatomical variations in sacrococcygeal anatomy among different ethnicities, which can further facilitate the diagnosis and identification of risk factors associated with coccydynia.

ASSOCIATION BETWEEN MEAN PLATELET VOLUME AND HEMORRHAGIC TRANSFORMATION AMONG PATIENTS WITH CEREBRAL INFARCTION IN DR. JOSE N. RODRIGUEZ MEMORIAL HOSPITAL AND SANITARIUM

Regina Joyce, JOAQUIN P.

Department of Radiology, Dr. Jose N. Rodriguez Memorial Hospital and Sanitarium, Saint Joseph Avenue, Tala, Caloocan City 1427, Philippines

Keywords: *Ischemic Stroke, Hemorrhagic Transformation, Mean Platelet Volume, Prognostic Marker, Retrospective Study*

Background

Ischemic stroke remains a significant cause of morbidity and mortality worldwide, with hemorrhagic transformation representing a common complication. Platelet function plays a crucial role in the pathogenesis of ischemic stroke, with mean platelet volume (MPV) emerging as a potential marker of platelet reactivity.

Methodology

Data were collected from medical records of patients diagnosed with cerebral infarction between January 2022 and January 2023. MPV measurements were obtained from complete blood count tests, while cranial CT scans were reviewed to identify hemorrhagic transformation. Statistical analyses, including the Kruskal-Wallis test, were employed to assess the association between MPV and hemorrhagic transformation.

Results

Descriptive analyses revealed a significant correlation between elevated MPV levels and the presence of hemorrhagic transformation ($p < 0.05$). Patients with hemorrhagic transformation exhibited higher MPV values compared to those without (mean MPV: 11.5 fL vs. 10.2 fL, respectively). Subtypes of hemorrhagic transformation, including petechial hemorrhage and parenchymal hematoma, were observed, contributing to the overall burden of hemorrhagic transformation.

Conclusion

This study provides compelling evidence of a significant association between elevated MPV levels and hemorrhagic transformation among patients with acute cerebral infarction. MPV may serve as a valuable predictive biomarker for identifying patients at higher risk of hemorrhagic transformation and adverse outcomes in ischemic stroke. Integration of MPV measurements into routine clinical assessment may facilitate risk stratification and personalized management strategies for ischemic stroke patients. Further prospective studies are warranted to validate these findings and explore the therapeutic implications of modulating platelet function in ischemic stroke management.

DIAGNOSTIC EFFICACY OF DUAL ENERGY CT FOR DIFFERENTIATING INTRACEREBRAL HEMORRHAGE FROM IODINATED CONTRAST MATERIAL STAINING

Authors: *Shadab Kanwal, Misbah Durrani, Zainab Nasir, Ummarah Kamran*

Keywords: *Dual Energy Ct, Cerebral Haemorrhage, Contrast Staining*

Purpose: To evaluate the efficacy of dual energy CT in early differentiation of intracerebral hemorrhage from iodinated contrast material staining.

Background:

Iodine staining and intracerebral bleed is a common phenomenon after Mechanical thrombectomy. Differentiating them is important so that appropriate antiplatelet therapy can be initiated.

Methodology:

Patients with acute stroke who had undergone mechanical thrombectomy were evaluated post procedural on dual energy CT to differentiate contrast material staining from haemorrhage. Follow up imaging after 24 and 48 hours on conventional CT were used as the standard of reference.

Inclusion criteria: All post MT patients of any age, male or female, with or without co morbidities, will be included in the study

Sample size: 50

Results:

Mixed images obtained with Dual energy CT showed intra-parenchymal hyperattenuation in 46/50 patients. Out of these 46 hyperattenuations, 31 were classified as iodine staining, 7 were classified as hemorrhage and 8 were classified as a mixture of hemorrhage and contrast material. The sensitivity, specificity, and accuracy of DECT in the identifying hemorrhage was calculated as 100% ,93% and 95% respectively. The only cases where DECT failed to correctly identify the hyperattenuation was in the presence of parenchymal calcification and metallic streak artifact.

Conclusion:

DECT allows an early and accurate differentiation between cerebral hemorrhage and iodine staining after Stroke intervention

LOEFFLER ENDOCARDITIS WITH VENTRICULAR LAMINAR THROMBUS

Fakhriah MB¹, Mubarak MY²

¹ Department of Radiology, SASMEC @IIUM Jalan Sultan Ahmad Shah, 25200, Kuantan, Pahang, Malaysia.

² Department of Radiology, Hospital Tengku Ampuan Afzan, Kuantan, Pahang, Malaysia.

Keywords: *Loeffler's Endocarditis, Hypereosinophilic Syndrome, Eosinophilic Endocarditis*

Eosinophilic endocarditis or Loeffler's endocarditis, is an uncommon restrictive cardiomyopathy associated with eosinophilia and endomyocardial fibrosis. Loeffler's endocarditis can lead to serious complications, such as progressive heart failure, systemic thromboembolic event or arrhythmia. We reported case of a 37-years-old gentleman, unknown medical illness, presented with heart failure symptoms. A full blood count showed bicytopenia with leukocytosis and marked eosinophilia. Echocardiography revealed masses within the ventricles and minimal global pericardial effusion. MRI cardiac imaging showed biventricular thrombi in the absence of regional wall motion abnormalities, mesocardial and subendocardial late gadolinium enhancement (LGE) involving the right and left ventricles. This patient was treated with intravenous methylprednisolone, Warfarin and Imatinib. The subsequent cardiac MRI demonstrated resolved thrombi in the biventricular regions. Hence, we emphasize the utility of cardiac magnetic resonance imaging in providing accurate diagnostic information and detecting early changes.

ATYPICAL PROSTATE METASTASIS: A CASE SERIES

Muhammad Syazwan Mohd Zain^{1,2}, Iqbal Hussain Rizuana^{1,2}

¹Department of Radiology, Faculty of Medicine, Universiti Kebangsaan Malaysia,

²Hospital Canselor Tuanku Muhriz, Jalan Yaacob Latif, Bandar Tun Razak, Kuala Lumpur.

Keywords: *Lytic Bone Metastasis, Prostate Carcinoma, Prostate Metastasis, Osteoblastic Prostate Metastasis*

Prostate cancer can metastasize to several organs, most commonly to bone, distance lymph node, liver and thorax. Osseous metastasis of can manifest as osteolytic, osteoblastic or mixed of both. Case report 1: 65-year-old male who with initial presentation discomfort in the left hip and buttock region following a minor fall. Investigations revealed right anterior third rib and costochondral junction, left iliac bone and acetabulum expansile lytic lesion, associated with soft tissue components. Case report 2: 54-year-old male patient who with underlying acinar adenocarcinoma of the prostate, presented with left hip and inguinal pain. Investigations show lytic and sclerotic bone lesions of the left hip with large surrounding soft tissue mass. These case series emphasises the significance of identifying osteolytic metastatic osseous prostate cancer, despite the higher incidence of the osteoblastic form. It is important for radiologist to recognise that metastatic prostate cancer can manifest as lytic or sclerotic bone lesions.

BROAD LIGAMENT SOLITARY FIBROUS TUMOR MIMICKING HUGE OVARIAN NEOPLASM: A RADIOLOGICAL PERSPECTIVE

Suraini, MS, Siti Nabilah MM, Norafida, B

Department Radiology, Faculty Medicine and Health Sciences, Universiti Putra Malaysia, Selangor Darul Ehsan, Malaysia

Keywords: *Solitary Fibrous Tumor, Ovarian Neoplasm, Pelvic Mass, Broad Ligament*

Solitary fibrous tumors (SFT) arise from mesenchymal tissue, and are typically rare, with pelvic occurrences being particularly uncommon. Therefore, pelvic solitary fibrous tumors may be misinterpreted as ovarian neoplasm in women. The features of SFT in images obtained from CT or MRI scans are not distinctive, thus necessitating the need for further investigation. The diagnosis is confirmed by characteristic positive immunohistochemical staining for CD34 and STAT6, and negative staining for S-100 (Ginat et al, 2011). This case report underscores the significance of considering this diagnosis when encountering a woman with a solid pelvic mass, normal tumor markers, and an absence of ascites.

ATYPICAL MANIFESTATION OF ACUTE APPENDICITIS MASQUERADING AS MALIGNANT LESION ON CT IMAGING

Nurizdiha Shukor^{1,2}, Rafidah Zainon³, Fajariah Beevi²

1 Department of Radiology, School of Medical Sciences, Health Campus, Universiti Sains Malaysia, 16150 Kubang Kerian, Kelantan, Malaysia.

2 Department of Radiology, Hospital Sultan Abdul Halim, 225, Jalan Lencongan Timur, Bandar Amanjaya, 08000, Sungai Petani, Kedah

3 Department of Biomedical Imaging, Advanced Medical and Dental Institute, Universiti Sains Malaysia, Bertam, 13200 Kepala Batas, Pulau Pinang, Malaysia.

Keywords: *Appendix, Acute Appendicitis, Malignant, Abdominal Mass, CT Abdomen Pelvis*

Acute appendicitis is a common surgical emergency typically presenting with classic clinical features and imaging findings. Circumstances in which radiologically revealed features are consistent with neoplasm but post-operative pathology finds no evidence of neoplastic is rare. We describe a case of 23-year-old woman who presented with unusual presentation of acute appendicitis characterized by computed tomography (CT) findings mimicking malignancy. The patient presented with vague abdominal pain and abdominal mass. Patient has no typical symptoms and signs of acute appendicitis. CT findings revealed suspicious mass-like lesion in right lower quadrant, raising concerns for malignancy. The intra-operative findings and post surgical histopathological diagnosis did not concur with the radiological diagnosis and instead demonstrated findings compatible with acute appendicitis without neoplastic change. This case highlights the importance of considering atypical presentations of appendicitis, particularly when imaging findings mimic malignancy. Prompt recognition and surgical intervention are crucial to prevent complications and improve patient outcomes.

GALLSTONE ILEUS WITH PROXIMAL SMALL BOWEL PERFORATION, A RARE COMPLICATION CARRYING SIGNIFICANT RISK OF INCREASED MORTALITY, NOT TO BE MISSED.

Cheng CW¹, Izzat H¹, Nor Azalina MS¹

¹Radiology Department of Sultan Ismail Hospital, Johor Bahru, Malaysia.

Keywords: *Gallstone ileus, Duodenal perforation*

Presentation of gallstone ileus accounts for 0.5% of all gallstone disease, carrying significant average mortality of 18%. Mechanical obstruction is the prominent presentation with rare cases having distal bowel perforation, compounding the risk of mortality. Proximal small bowel perforation, however, is exceedingly rare with only a handful of reported cases in literature. We are presenting a case of a 74-year-old gentleman with history of Hartman's procedure of perforated sigmoid diverticulum coming in with 2-day history of acute intestinal obstructive symptoms associated with vague abdominal pain. Initial suspicions pointed to adhesions being the aetiology however subsequent Computed Tomography (CT) scan demonstrates findings of a cholecystoenteric fistula communicating with the D1 segment with mid ileal obstructing Gallstone complicated with large perforation at distal D2 with retroperitoneal collection. Midline laparotomy was performed confirming findings consistent with the CT images.

A RARE PRESENTATION: SIGMOID VOLVULUS AS THE CAUSE OF INTESTINAL OBSTRUCTION IN A YOUNG FEMALE

Nurizdiha Shukor^{1,2}, Rafidah Zainon³, Nur Ahida Md Ahir² Lim Yi Wei²

1 Department of Radiology, School of Medical Sciences, Health Campus, Universiti Sains Malaysia, 16150 Kubang Kerian, Kelantan, Malaysia.

2 Department of Radiology, Hospital Sultan Abdul Halim, 225, Jalan Lencongan Timur, Bandar Amanjaya, 08000, Sungai Petani, Kedah

3 Department of Biomedical Imaging, Advanced Medical and Dental Institute, Universiti Sains Malaysia, Bertam, 13200 Kepala Batas, Pulau Pinang, Malaysia.

Keywords: *Sigmoid Volvulus, Intestinal Obstruction, Colonoscopy, Bowel Decompression*

A sigmoid volvulus occurs when part of the colon segment twists upon its mesentery. It is associated with old age, multiple co-morbidities, and male sex. It is an uncommon problem in young age population, and is rarely considered a diagnosis in this group. We present a rare case of sigmoid volvulus that occurred in a healthy young female. A 22 year old female presented with a sudden onset of left hypochondriac pain and no bowel output for 2 days and associated with multiple episodes of vomiting. Physical examination revealed a distended abdomen. Plain abdominal radiograph and Computed tomography (CT) of the abdomen was consistent with sigmoid volvulus. Successful colonoscopic decompression was performed with flatus tube inserted. This case report emphasizes the importance of clinicians maintaining a sigmoid volvulus as a rare, yet important differential when approaching abdominal pain in young patient.

PRIMARY RENAL LYMPHOMA PRESENTING AS BILATERAL RENAL PELVIS SOFT TISSUE LESIONS- A RARE CASE

Nor Azlan Mohd Zin^{1,2}, Erica Yee Hing^{1,2}

1 Department of Radiology, Faculty of Medicine, University Kebangsaan Malaysia

2 Hospital Canselor Tuanku Muhriz, Jalan Yaacob Latif, Bandar Tun Razak, Kuala Lumpur, Malaysia

Keyword: Renal Pelvis Tumor; Primary Renal Lymphoma; Obstructive Uropathy; Synchronized Upper Renal Tract Tumor; Positron Emission Tomography Imaging.

Introduction

Primary renal pelvis lymphoma is uncommon with few cases reported.

Report:

A 65 years-old, investigated for bilateral obstructive uropathy detected on Ultrasonography (USG). Computed tomography (CT) shows bilateral renal pelvis enhancing soft tissue lesions with no enlarged lymph nodes. Retrograde Intrarenal Surgery (RIRS) and Uteroscopy (URS) does not shows any lesion within the urinary tract while cytology was negative for malignancy. Repeated CT shows increasing in size of bilateral renal pelvis lesions with encasement of the renal hilar vessels and collecting system. Positron Emission Tomography Scan (PET) shows high metabolic uptake within this soft tissue lesions. Biopsy of the right renal pelvis lesion revealed marginal zone lymphoma. Bone Marrow Aspiration Terphine Biopsy (BMAT) shows no lymphomatous infiltration. Patient was started on chemotherapy and surveillance PET CT shows good treatment response.

Conclusion:

Although uncommon, the diagnosis of lymphoma should be considered in the case of renal pelvis soft tissue lesion.

RUPTURED ABDOMINAL AORTIC ANEURYSM (AAA) AS A RARE CAUSE OF STROKE

Yun Hui, Ng¹, I. B. A. Bakar²; Y. Yaacob³

1 Imaging Centre, Institut Jantung Negara, Jalan Tun Razak, Kuala Lumpur, Malaysia

2 Radiology Department, International Islamic University Malaysia, Kuantan, Pahang, Malaysia

3 Radiology Department, Hospital Canselor Tuanku Muhriz UKM, Cheras, Kuala Lumpur, Malaysia

Keywords: *Abdominal Aortic Aneurysm Rupture; Altered Mental Status; Cerebrovascular Attack; Ischemic Stroke*

Introduction

Ruptured abdominal aortic aneurysm is a life-threatening surgical emergency.

Report:

69 year old man came with acute stroke as the first presentation of rupture abdominal aortic aneurysm (AAA). Patient presented with fall with altered mental status, aphasia, generalised bilateral weakness and hypotension. CT Brain plain showed hypodensity in the left frontal region with loss of normal grey white matter differentiation, feature suspicious of an acute left MCA infarct. Bedside ultrasound reviewed AAA. CTA Aorta showed ruptured infrarenal abdominal aortic aneurysm with large left retroperitoneal hematoma. No evidence of active bleeding. Blood transfusion was given. Family opted conservative management in view of mortality rate is high. DIL/NAR issued. Patient died.

Conclusion:

AAA rupture are clinically indistinguishable especially when it comes with non-specific symptoms and signs that often leads to misdiagnosis. Having a wide differential diagnosis in terms of acute stroke is vital to ensure prompt diagnosis and effective management.

COMPLICATION FROM CONSUMPTION OF 'KING OF FRUIT': A CASE REPORT OF SMALL BOWEL OBSTRUCTION DUE TO DURIAN SEED IMPACTION

Lim G1, Azham A2

1 Radiology Department, Hospital Sultanah Nora Ismail, Batu Pahat 83000 Johor, Malaysia.

2 Radiology Department, Hospital Putrajaya, Wilayah Persekutuan Putrajaya 62250, Malaysia.

Keywords: *Ingestion, Impaction, Durian, Seed, Bezoars, Ileum, Small Bowel Obstruction*

Introduction:

Acute mechanical intestinal obstruction (AMIO) occurs when intestinal contents are blocked, requiring emergency surgical intervention. AMIO accounts for about 20% of emergency surgical procedures.

Case Presentation:

61-year-old man presented with abdominal distention, no flatus or bowel output for 4 days, and 1 day of abdominal pain and vomiting. Examination showed a soft, distended abdomen with sluggish bowel sounds. Abdominal radiograph indicated small bowel obstruction. CT scan revealed an intraluminal oval hyperdense mass (1.9x1.8x3.7 cm) in the mid ileum. Exploratory laparotomy identified and removed a durian seed causing the obstruction, 70 cm from the ileo-caecal junction, followed by bowel repair. The patient had consumed durian a week earlier.

Conclusion:

Foreign bodies rarely cause small bowel obstruction without prior abdominal surgery or adhesions. Typically, they pass through the small bowel without issue. Durian seeds and laminated gallstones may appear similar on CT. Recent ingestion history aids diagnosis but not always available.

UTILIZATION OF 3D MRI IN DIAGNOSING EARLY CAESAREAN SCAR ECTOPIC PREGNANCY: A CASE REPORT

Tan HL^{1,2}, Roudhotul Nadiah MH², Nasuha MK², Ch'ng LS^{1,2}

¹*Department of Radiology, Faculty of Medicine, Universiti Teknologi MARA, Sungai Buloh, Selangor, Malaysia.*

²*Department of Radiology, Hospital Al-Sultan Abdullah, Universiti Teknologi MARA Puncak Alam, Selangor, Malaysia.*

Keywords: *Pregnancy, Scar Ectopic, 3D MRI*

Caesarean scar ectopic pregnancy, a rare occurrence, involves the implantation of a pregnancy within the scar tissue from a previous cesarean section. This condition can pose significant risks to maternal health, including uterine rupture, severe bleeding, and potential mortality. Diagnosis often relies on sonography, with Magnetic Resonance Imaging (MRI) serving as a crucial tool, particularly when sonographic findings are inconclusive, as it is a potentially life-threatening condition that requires prompt and appropriate management. However, in early pregnancy stages, especially when the fetal pole is minimally developed, identifying ectopic pregnancies on 2D MRI can pose challenges. Herein, we present a case of an early caesarean scar ectopic pregnancy, where sonographic findings were equivocal, and MRI, particularly 3D MRI, played a pivotal role in facilitating diagnosis.

BEYOND THE CONVENTIONAL: EXPLORING RADIOLOGICAL APPROACHES IN DIAGNOSING CERVICAL PREGNANCY

Devina Y¹, Irwan TR², Vincent L^{1,3}, Sariningsih H^{4,5}, Ratri W⁵, Zannuba AN², Lina C^{1,3}

¹*Department of Radiology, Faculty of Medicine, Public Health, and Nursing, Universitas Gadjah Mada, Yogyakarta, Indonesia*

²*Department of Obstetrics and Gynecology, Faculty of Medicine, Public Health, and Nursing, Universitas Gadjah Mada, Yogyakarta, Indonesia*

³*Radiology Research and Training Office, Universitas Gadjah Mada, Yogyakarta, Indonesia*

⁴*Dharmais Cancer Hospital, Jakarta, Indonesia*

⁵*Doctoral Program, Faculty of Medicine, Public Health, and Nursing, Universitas Gadjah Mada, Yogyakarta, Indonesia*

Keywords: *Cervical Pregnancy, Ectopic Pregnancy, Magnetic Resonance Imaging, Transvaginal Ultrasound*

Cervical pregnancy, a rare ectopic pregnancy in the cervical canal, requires prompt diagnosis to prevent severe complications. We present a case of a 32-year-old woman with a positive pregnancy test four months earlier and was diagnosed with a blighted ovum, leading to curettage. Persistent vaginal bleeding occurred post-curettage, causing severe anemia with a hemoglobin of 4 g/dL. Transvaginal ultrasound (TVUS) showed no intrauterine gestational sac but detected a mass suspected as cervical leiomyoma. Upon referral to our hospital, β -HCG was 935 mIU/mL. Magnetic resonance imaging (MRI) revealed a heterogeneous cervical lesion with no viable fetus and no trophoblastic invasion, suggesting retained product of conception from cervical ectopy pregnancy. Patients received methotrexate and β -HCG level steadily dropped to 14 mIU/mL. This case highlights that TVUS can misinterpret cervical lesions, necessitating advanced imaging modalities. MRI provides detailed anatomical views, enabling early diagnosis and proper treatment for ectopic pregnancy.

MISDIAGNOSED LEFT ADNEXAL MASS REVEALED AS *PERITONEAL SPLENOSIS*

Jeyaraaj J

Department of Radiology, University Malaya Medical Centre, Kuala Lumpur, Malaysia.

Keywords: *Splenosis, Adnexal Mass*

We present a compelling case in a 46-year-old nulliparous female with a history of splenectomy following a motor vehicle accident (MVA) presenting with suprapubic discomfort. Physical examination revealed a palpable lower abdominal mass. Blood investigations yielded normal results, indicating no acute systemic complications. CT abdomen-pelvis exhibited an enhancing left adnexal mass closely associated with the uterus, raising concerns of gynaecological pathology. No splenic tissue was visualized in the left hypochondrium, consistent with the patient's history of splenectomy. Diagnostic laparoscopy revealed a left adnexal mass likely of gynaecological origin, prompting a biopsy. Histopathological examination of the left adnexal mass revealed benign splenic tissue consistent with the diagnosis of splenosis. This case emphasizes the importance of considering peritoneal splenosis in the differential diagnosis of adnexal masses despite a history of splenectomy. Our report contributes to the expanding knowledge base surrounding this rare entity, emphasizing the significance of meticulous diagnostic evaluation to avoid misinterpretation and facilitate appropriate patient management.

PERITONEAL PARADOX: TUBERCULOSIS MASQUERADING AS ABDOMINAL MALIGNANCY

Ramanathan SRM

Department of Radiology, KPJ Damansara, Petaling Jaya, Selangor, Malaysia

Keywords: *Abdominal Tuberculosis*

22-year-old male smoker presented with abdominal pain, weight loss, and diarrhoea. He denied chronic cough or contact with tuberculosis-infected individuals. Clinical examination revealed tenderness and guarding in the right iliac fossa, while lung examination was unremarkable. Laboratory findings showed elevated neutrophils and C-reactive protein (CRP) levels. Initial management presumed peritonitis with suspicion of underlying malignancy, prompting a CT abdomen, which revealed diffuse thickening of the peritoneum with moderate ascites. Concurrently, a chest radiograph showed left upper lobe pneumonia, raising the possibility of pulmonary tuberculosis. A laparoscopic biopsy of the thickened omentum revealed peritoneal tuberculosis. This journey highlighted the difficulty in distinguishing it from abdominal malignancies due to similar symptoms. This case underscores the diagnostic complexities and stressing the need for vigilant diagnosis and balanced treatment approaches.

QUANTITATIVE MEASUREMENT OF MYELIN IN NEURODEGENERATIVE DISEASE

Nadiyah M¹, Norafida B²

¹Department of Radiology, Hospital Sultan Idris Shah, Serdang, Selangor, Malaysia,

²Department of Radiology, Hospital Sultan Abdul Aziz Shah, Serdang, Selangor, Malaysia.

Keywords: Myelin Correlated Volume, Neurodegenerative Disease, MRI, MDME

Background

Neurodegenerative disease is an umbrella term for adult-onset extensive variety of diseases which typically progresses slowly and is accompanied by variable gradual neurological deterioration. Few common neurodegenerative diseases include Alzheimer's and Parkinson's diseases. Often imaging findings of neurodegenerative disease are subtle and equivocal. Currently, with the emerging new techniques of myelin detection and quantification using MRI, several studies have shown that these techniques are beneficial in the diagnosis of neurodegenerative diseases. Thus, the purpose of this study is to obtain the quantitative measurement and analysis of myelin in neurodegenerative disease such as Alzheimer's and Parkinson's diseases.

Methodology

This is a retrospective study of patients that underwent MRI Brain neurodegenerative protocol with MDME included as one of the sequences. Quantitative analysis will automatically be done using the Synthetic MRI application where the myelin correlated volume among other datasets will be obtained and analyzed. These sets of data will then be plotted in graphs in comparison to a normal population database readily available within the application.

Results

In this small sample pilot study, we have found that lower myelin correlated volume is seen in the clinical and/or radiological suspected or confirmed cases of neurodegenerative disease patients.

Conclusion

Although the limitations of this study include a small sample size, the quantitative measurement and analysis have shown evidence of lower myelin correlated volume in neurodegenerative disease, thus should encourage more substantial and elaborated studies in future.

**PYLEPHLEBITIS MIMICKING A MESENTERIC MASS: A RARE COMPLICATION OF PERFORATED APPENDICITIS
WITH UNIQUE RADIOLOGICAL FINDINGS**

Low JJ¹, Vithiya S², Siti AH³

¹Radiology Department, Hospital Sultan Ismail, Johor Bahru, Malaysia

Keywords: *Pylephlebitis, Appendicitis*

Pylephlebitis is a rare complication of intra abdominal infection most commonly seen secondary to diverticulitis, appendicitis and necrotising pancreatitis. It typically appears as a filling defect within the mesenteric veins leading to abscess formation or bowel ischemia. We present this case of a 47 years old man with fever and abdominal pain 1 month post open appendicectomy for perforated appendicitis. He was in sepsis and the abdomen was soft but tender at the epigastric region. Infective markers were markedly raised. Cross sectional imaging performed showed a large mesenteric mass following the distribution of the superior mesenteric and portal veins with thrombosis of these vessels. Based on imaging a differential diagnosis of pylephlebitis or mesentery mass was given. Biopsy of this mass returned as inflammatory tissue confirming the diagnosis of pylephlebitis. Patient was treated conservatively. We are presenting this case for its unique radiological findings.

PRIMARY NON-HODKIN'S LYMPHOMA MIMICKING CHOLANGIOCARCINOMA

MOHD AS, Anushya V.

Bio-Medical Imaging Department, University Malaya Medical Centre, Jalan Prof Diraja Ungku Aziz, Kuala Lumpur, Malaysia.

Keywords: *Cholangiocarcinoma, Liver Lymphoma, CT Liver*

Primary hepatic lymphoma (PHL) is an uncommon variant of non-Hodgkin lymphoma originating primarily within the liver. A 60-year-old gentleman presented with jaundice for one month with severe headache and diplopia. On examination, he is deep jaundice, with complex ophthalmoplegia over the right eye with impaired third, fourth and sixth nerves. Per abdomen, noted hepatomegaly. The liver function test was deranged. CT brain shows asymmetry thickening of the cavernous sinus and subsequent MRI revealed cavernous sinus thrombosis. CT liver demonstrates numerous ill-defined hypodense lesions in liver with intrahepatic duct dilatation, suspicious of cholangiocarcinoma. Percutaneous trans biliary drainage was done. HPE showed high-grade non-Hodgkin B cell lymphoma. The patient was started on dexamethasone and hydrocortisone and planned for chemotherapy, however deteriorated in ward and expired. Although PHL is a rare diagnosis, it should be considered when there are solitary or multiple liver lesions in a middle-aged patient with normal tumor marker.

HEPATIC ANGIOMYOLIPOMA MIMICKING HEPATOCELLULAR CARCINOMA

Vrshni Menaka RSN¹, Lau CC¹, Nik Shah Hizan²

- 1. Department of Radiology, Hospital Universiti Sains Malaysia, 15100 Kubang Kerian, Kelantan, Malaysia*
- 2. Department of Radiology, Hospital Raja Perempuan Zainab II, 15000 Kota Bharu, Kelantan, Malaysia*

Keywords: *hepatic angiomyolipoma, hepatocellular carcinoma, computed tomography*

Hepatic angiomyolipoma is infrequently encountered as compared to renal angiomyolipoma. Furthermore, it is difficult to distinguish a hyper vascular hepatic angiomyolipoma from hepatocellular carcinoma from imaging, hence it poses a challenge for radiologists in providing the provisional diagnosis. We present a case of an asymptomatic patient incidentally found to have liver lesion during a routine follow-up ultrasound which subsequently led to a multiphase liver computed tomography (CT). The initial preoperative CT scan concluded the liver lesion as hepatocellular carcinoma whereby the patient underwent surgical resection and the biopsy yielded angiomyolipoma. In conclusion, it is important to differentiate between hepatic angiomyolipoma and hepatocellular carcinoma as the treatment that follows for both these diagnoses vary greatly whereby angiomyolipoma can be managed conservatively and conversely for hepatocellular carcinoma it is dealt by surgical resection or chemotherapy. Contrast magnetic resonance imaging (MRI) in a noncirrhotic liver may misdiagnose angiomyolipoma as hepatocellular carcinoma.

MESENTERIC FIBROMATOSIS: A LITTLE KNOWN AND RARE AGGRESSIVE BENIGN TUMOR

Nur Syafiqah MR 1, Mohd Hazeman Z 1

1Department of Radiology, Hospital Sultan Abdul Aziz Shah, UPM, Serdang, Malaysia.

Keywords: *Mesenteric Fibromatosis; Desmoid Tumor; Peritonism*

Mesenteric fibromatosis or desmoid tumor, is a rare benign tumor originating from fibrous tissue proliferation, commonly affecting young adults. Clinical presentations vary widely, often manifesting with abdominal symptoms. Here, we describe a 34-year-old man presenting with peritonism symptoms, incidentally, discovered to have a mesenteric mass on contrasted CT Abdomen. Surgical exploration unveiled extensive involvement, posing a risk of bowel ischemia, prompting biopsy for confirmation. Subsequent CT scans revealed postoperative complications, including a necrotic ruptured mass and intraabdominal collections, managed with drainage and antibiotics. Despite risks, surgical resection remained the primary treatment, albeit with potential complications due to the mass's proximity to the Superior Mesenteric Artery. Radiotherapy or chemotherapy were not suitable due to slow tumor growth. While mesenteric angiography with angioembolization was offered as an alternative, the patient opted for surveillance through repeated imaging. This case highlights the diverse clinical features, its potential complications and available management options.

UTERINE DEHISCENCE: A RARE BUT RELEVANT POSTPARTUM COMPLICATION THAT DEMANDS ATTENTION

Nurizdiha Shukor^{1,2}, Rafidah Zainon³, Tan Cheng Chong², Nurhasyida Mohd Rashid²

1 Department of Radiology, School of Medical Sciences, Health Campus, Universiti Sains Malaysia, 16150 Kubang Kerian, Kelantan, Malaysia.

2 Department of Radiology, Hospital Sultan Abdul Halim, 225, Jalan Lencongan Timur, Bandar Amanjaya, 08000, Sungai Petani, Kedah

3 Department of Biomedical Imaging, Advanced Medical and Dental Institute, Universiti Sains Malaysia, Bertam, 13200 Kepala Batas, Pulau Pinang, Malaysia.

Keywords: *Uterine Dehiscence, Postpartum, Caesarean Section, Computed Tomography*

Uterine dehiscence, although rare, presents a critical postpartum concern necessitating heightened clinical awareness. Uterine dehiscence in the postnatal period still remains elusive due to its vague presentation. An incorrect diagnosis or a delay in diagnosis can lead to unnecessary interventions or delay the management of patient symptoms. It possess substantial maternal morbidity and mortality risks. This particular case demonstrate a 32 year old woman underwent emergency lower segment caesarean section for fetal distress. On the 7th postpartum day, she developed heavy amount of foul smelling greyish watery vaginal discharge. Computed tomography revealed pelvic collection with suspicious of dehiscence at lower segment caesarean section incision site. Emergency laparotomy revealed a dehiscence of the lower uterine segment incision. The incision was repaired and the postoperative course was uneventful. Despite its infrequency, uterine dehiscence warrants meticulous consideration within obstetric practice to mitigate its potentially catastrophic consequences.

INCIDENCE OF RETROAORTIC RENAL VEIN IN PATIENTS WITH ACUTE FLANK PAIN

Abdulla Aljehani Aa1, Hamed Alharbi Ha1, Bander Alshomarani Ba1, Refah Alqahtani Ra1, Rogya Bamoharram Rb1

1radiology, Ministry Of Health – Jeddah First Health Cluster – King Abdulaziz Hospital, Almahjar Street, Jeddah, Saudi Arabia

Keywords: *Posterior Nutcracker Syndrome, Retroaortic Renal Vein, Renal Colic*

Background

The left retroaortic renal vein is a rare anatomical variation where the left renal vein takes a posterior course behind the abdominal aorta before joining the inferior vena cava. Unlike the typical anterior course of the left renal vein, the retroaortic course may lead to venous congestion, hinder renal blood flow, and potentially cause symptoms like flank pain, hematuria or varicocele.

Methodology

For the patient who present to the emergency department complaining of flank pain. We retrospectively evaluated plain KUB CT scans done in our radiology department at King Abdulaziz General Hospital between January 2016 and December 2022. Exclusion criteria include, recent history of trauma, known of renal stones or known for UTI infection/inflammatory process. CT scan performed in two scanners (GE128 slice slice scanner and Siemens Somatom 64 slice thickness). The images are obtained at 2.5 mm slice thickness with sagittal and coronal reformats. Positive cases are considered in patient with left-sided retroaortic renal vein with absent of renal stone. The CT scans studies were reviewed and interpreted by three radiologists.

Results

Among a total of 1592 patients, 62.2% were male, with an average age of 47.86 ± 16.78 years. Within this population, 6.34% exhibited a positive retroaortic left renal vein, while 42.39% were diagnosed with urinary tract stones. Furthermore, 2.7% of the patients had both urinary system stones and retroaortic renal vein.

Conclusion

Identifying left-sided retroaortic renal vein in patients experiencing flank pain or renal colic, can assist physicians in achieving precise diagnoses.

A RARE CASE OF METACHRONOUS SECOND PRIMARY PENILE MALIGNANCY IN A CONFIRMED PROSTATE CANCER

Nur Marini Zainal^{1,2}, Iqbal Hussain Rizuana^{1,2}, Basri Johan Jeet Abdullah³, Xeng Inn Fam^{4,2}.

¹Department of Radiology, Faculty of Medicine, Universiti Kebangsaan Malaysia,

²Hospital Canselor Tuanku Muhriz, Jalan Yaacob Latif, Bandar Tun Razak, Kuala Lumpur.

³Department of Radiology, Assunta Hospital, Jalan Templer, Petaling Jaya, Selangor, Malaysia.

⁴Department of Urology, Faculty of Medicine, Universiti Kebangsaan Malaysia, Kuala Lumpur, 56000, Malaysia.

Keywords: Penile Cancer; Prostate Cancer; Radiology; Cancer Of Penis; Metastatic Prostate Cancer.

Second primary malignancy (SPM) in prostate cancer patients are rare. SPM was more commonly involving lung and bronchus (24.90%). We described a case of a 73-year-old gentleman smoker presented with lower urinary tract symptoms. Initial computed tomography urography, showed prostatomegaly with penile urethra calcifications. Histopathological examination from the prostate biopsy revealed poorly differentiated adenocarcinoma with differentials of prostatic ductal adenocarcinoma or urothelial carcinoma. CT staging showed prostate malignancy with seminal vesicle, urinary bladder, right distal ureter, lower rectal infiltration with a few right lung nodules, suspicious of lung metastases. After 2 years of treatment with hormonal therapy, patient developed new symptoms of ulcerative penile swelling. CT shows features of penile malignancy, as well as mediastinal lymphadenopathies and lung nodules. HPE showed squamous cell carcinoma of the penis. To the best of our knowledge, this is the first reported case of secondary primary malignancy in prostate cancer in Malaysia.

FREE SILICONE BREAST INJECTIONS: DIAGNOSTIC IMAGING CHALLENGES

Nur Sakinah Abd Rasad¹, Cheah Sin Dee², Bashiron Binti Jamaludin¹, Wong Yi-Li (Grace)¹

¹ Radiology Department, Hospital Pulau Pinang, Jalan Resideni, 10990 George Town, Pulau Pinang

² Surgery Department, Hospital Pulau Pinang, Jalan Resideni, 10990 George Town, Pulau Pinang

Keywords: *Free Silicone Injections, Breast Imaging, Breast MRI, Mammogram, Breast Ultrasound*

Due to adverse effects, free silicon breast injections have been banned in most countries. However, it is still illegally performed by non-certified personnel due to low cost. The occasional patient may present weeks to decades from the time of injections with complications which range from mild to moderate. A 56-year-old lady with history of breast fillers 10 years ago presented with a right breast lump for a year. Free silicone injections stimulate foreign body reactions, leading to granulomatous formations i.e. siliconomas. Siliconomas appear as high-density lesions on MMG and cystic globules surrounded by echogenicities with posterior shadowing (“snowstorm” appearance) on ultrasound, mimicking or obscuring true lesions. The ACR BI-RADS recommends contrast-enhanced MRI as both a screening and diagnostic tool. The objective of this case study is to compare the appearance of siliconomas on different imaging modalities and illustrate differentiation between true breast lesions from siliconomas on MRI.

ADVANCE MRI APPROACH TO DETECT RESIDUAL BREAST MALIGNANCY: A CASE REPORT

Rifki B¹, Siti D¹, Devina Y¹, Lina C¹

¹Department of Radiology, Faculty of Medicine, Public Health and Nursing, Universitas Gadjah Mada, Yogyakarta, Indonesia.

Keywords: *DWI, MRI, DCE, Breast, Oncology*

Residual breast malignancy lesions present a challenge for radiologists to evaluate using conventional MRI sequences due to their small size. Advanced MRI techniques, such as dynamic contrast enhancement and both conventional and synthetic diffusion-weighted imaging with high b values, have shown significant clinical value. In this case report, we present the case of a 36-year-old female who underwent a follow-up MRI examination after breast-conserving surgery for invasive ductal carcinoma. The initial MRI showed a suspicious small lesion with intermediate restriction that was not clearly visible. However, the synthetic DWI with high b values demonstrated clear visibility of the lesion. Additionally, the DCE sequence revealed a plateau kinetic curve indicative of malignancy. Combining these advanced MR techniques might provide valuable information to evaluate residual breast malignancy.

NAVIGATING THE NEXUS: PRIMARY ANGIOSARCOMA OF THE BREAST: IMAGING INSIGHTS AND HISTOPATHOLOGICAL CORRELATION

Muhammad Nabil MK¹, Khoo SZ¹, Khatrulnada MS¹, Ahmad Fazlin N², Che Jamal Abdillah CA³

1 Department of Radiology, Hospital Sultan Haji Ahmad Shah, Temerloh, Pahang, Malaysia.

2 Department of Pathology, Hospital Sultan Haji Ahmad Shah, Temerloh, Pahang, Malaysia.

3 Department of Surgery, Hospital Sultan Haji Ahmad Shah, Temerloh, Pahang, Malaysia.

Keywords: *Angiosarcoma, high density lesion, heterogenous hypoechoic mass*

Angiosarcoma, a rare aggressive tumour arises from endothelial cells lining vascular channels, poses diagnostic challenges especially when arising in the breast as primary angiosarcoma. We present a case of a patient with left breast swelling for 7 years, progressively worsening in the last 6 months, associated with distended veins and hyperpigmented skin. Initial mammogram unveiled a large lobulated high-density mass within the left breast with mild architectural distortion, nipple retraction and skin thickening. Complementary ultrasound reveals a large lobulated heterogenous hypoechoic mass with minimal vascularity on colour doppler signal - prompting a BIRADS 5 highly suspicious mass. Subsequent CT demonstrates a heterogeneously enhancing mass occupying the entire left breast with no calcification or fat component within. Due to its similar course of presentation with other primary breast tumour, this case underscores the importance of multimodal imaging as well as histopathological correlation to disentangle the diagnostic conundrum and expedite appropriate management.

DIAGNOSIS CHALLENGE: SMALL BOWEL PERFORATION FROM FISH BONE INGESTION IDENTIFIED BY RADIOLOGICAL IMAGING

Cheng Cw¹, Vithiya S¹, Siti Ah¹

¹Radiology Department Of Sultan Ismail Hospital, Johor Bahru, Malaysia.

Keywords: *Fish Bone Ingestion, Small Bowel Perforation*

Fish bone is one of the most commonly ingested foreign bodies. While most instances pass spontaneously, complications such as perforation of the gastrointestinal tract can occur. The occurrence however is rare and accounts for < 1 % of cases, at which it poses a significant challenge in diagnosis as the clinical manifestations are non-specific and are subjected to the site of perforation. Cross sectional imaging plays a significant role in helping with the diagnosis. We are presenting a case of a 46-year-old immunocompromised woman with non-specific right iliac fossa pain and tenderness which started at the epigastric region. Initial clinical suspicions pointed to acute appendicitis and diverticulitis being the aetiologies. Cross sectional imaging however showed an intraluminal linear hyperdense object piercing through a markedly thickened small bowel loop with adjacent pneumoperitoneum suggestive of small bowel perforation secondary to foreign body ingestion. Emergency laparotomy performed confirmed the diagnosis.

**HISTOLOGICALLY PROVEN HIGH GRADE GLIOMA SHOWING HIGH SIGNAL ACTIVITY AMIDE PROTON
TRANSFER WEIGHTED MRI: A CASE SERIES.**

Norfatin S1, Nur A1,2, Anani A3.

1Department of Radiology, School of Medical Sciences, Universiti Sains Malaysia, 16150 Kubang Kerian, Kelantan, Malaysia.

2Hospital Universiti Sains Malaysia, Universiti Sains Malaysia, Health Campus, Jalan Raja Perempuan Zainab 2, 16150 Kubang Kerian, Kelantan, Malaysia.

3Department of Pathology, School of Medical Science, Health Campus, Universiti Sains Malaysia, 16150 Kubang Kerian, Kelantan, Malaysia.

Keywords: *Magnetic Resonance Imaging, Amide Proton Transfer (APT) Weighted, High Grade Glioma*

Gliomas are the most common primary tumors of the central nervous system in adult. Current gold standard for gliomas' diagnosis and therapeutic decision relies on the histopathology. However, the heterogeneous characteristics of gliomas and their capacity for diffuse infiltration causing difficulty in sampling the highest-grade portion of tumor accurately. There have been limited case series reported on histologically proven high grade gliomas showing high APT signal activity. We present three patients with high APT signal activity and histologically proven to be high grade gliomas. Case 1 proven as glioblastoma multiforme, case 2 is proven to be anaplastic ependymoma and case 3 is proven as anaplastic astrocytoma. APT imaging is a novel non-invasive MRI technique which provides molecular information predominantly based on the amide protons in cellular proteins and peptides in the intracellular and extracellular spaces. Higher peptide and protein concentrations usually result from higher cell density in high grade gliomas.

DEVELOPMENT OF VASOGENIC CEREBRAL EDEMA AFTER CT MYELOGRAM WITH NONIONIC CONTRAST

Fatima Mubarak

Radiology Department, Aga Khan University Hospital, Karachi, Pakistan

Keywords: *Vasogenic Edema, CT, Myelogram, Non-Ionic Contrast*

Vasogenic edema is a very rare complication of CT myelogram. A 42-year-old female known case of diabetes, hypertension, focal segmental necrotizing glomerulonephritis, and permanent pacemaker in situ for ASD secundum underwent myelogram. Within less than twelve hours she developed altered sensorium and decreased consciousness. Contrast-enhanced CT brain was performed which showed diffuse effacement of cortical sulci with poor gray-white matter differentiation. There was crowding at the foramen magnum with evidence of tonsillar herniation. Diagnosis of CT myelogram-induced cerebral edema was made. The patient received mannitol along with steroid pulse therapy. There was interval resolution of cerebral edema and tonsillar herniation on follow up CT brain. Five doses of pulse therapy were given, and after a five-day admission and observation the patient was discharged in stable condition. We are reporting this case so that clinicians are familiar with this uncommon complication of CT myelogram to start early management for better patient outcome.

LYMPHOMATOSIS CEREBRI: A DIAGNOSTIC DILEMMA

Fatima Mubarak

Radiology Department, Aga Khan University Hospital, Karachi. Pakistan

Keywords: *Lymphomatosis, Cerebri, Dilemma*

Background

Lymphomatosis cerebri (LC) is a rare manifestation of primary central nervous system lymphoma (PCNSL) with only a few cases reported in the literature, appearing as diffuse infiltrating process rather than a solitary mass. It is a non-Hodgkin's type of lymphoma and is usually of the B-cell type origin. We intend to report this unique case of LC which came across as a diagnostic challenge.

Methodology

A 53-year-old gentleman presented with complaints of two episodes of seizures 24 h apart followed by postictal confusion for 10–15 min. He underwent multiple MRI scans and underwent a biopsy of the lesion which reported infection, but he did not benefit from the treatment.

Result

The imaging was reviewed, suspicion of LC was raised and a review of histopathology was requested which later confirmed primary CNS lymphoma.

Conclusion

LC is a rare but established manifestation of PCNSL which mimics multiple other conditions. Understanding of the imaging pattern is important in making the diagnosis and differentiating it from other mimic conditions.

DIABETIC FIBROUS MASTOPATHY MASQUERADING AS BREAST MALIGNANCY

See ST¹, Laili Suriani AL¹

¹Radiology Department, Hospital Pakar Sultanah Fatimah Muar, Jalan Salleh, Muar, Malaysia DFM

Keywords: *Diabetic Fibrous Mastopathy, Breast Cancer*

Diabetic fibrous mastopathy (DFM) is a rare benign entity in patients with longstanding diabetes mellitus. Its clinical presentation as a painless breast lump and imaging findings may mimic malignancy. Thus, histopathology examination (HPE) is required to confirm the diagnosis. This case reports a 42 years old diabetic female, who presented with painless left breast lump for 1 month. She has no axillary lymphadenopathy or constitutional symptoms. Her cousin has breast cancer and the patient had history of taking oral contraceptive pill for 6 months. Mammogram showed left periareolar focal asymmetry, no associated architectural distortion or calcifications. Her breast ultrasound revealed a suspicious irregular, wider-than-tall mass with posterior shadowing at the corresponding region. Ultrasound guided biopsy was performed and HPE showed features of diabetic mastopathy with no evidence of malignancy. This report highlights DFM as a benign breast condition, which is usually non-specific on mammogram, suspicious on ultrasound and requires pathological diagnosis.

LYRE SIGN – WHERE SCHWANNOMA MIMICS A CAROTID BODY TUMOUR.

Fatin NJS¹, Hilwati H¹, Norliana DMA¹, Masaany M², Wong PY³

1/ Radiology Department, Hospital Al-Sultan Abdullah, Universiti Teknologi MARA, Malaysia,

2/Otorhinolaryngology Department, Hospital Al-Sultan Abdullah, Universiti Teknologi MARA, Malaysia

3/ Pathology Department, Hospital Canselor Tuanku Muhriz, Universiti Kebangsaan Malaysia, Malaysia

Keywords: *Lyre Sign, Splaying Of Carotid Bifurcation, Schwannoma, Carotid Body Tumour*

Neural crest cell tumours are rare and diverse. They include schwannomas, benign nerve sheath tumours derived from Schwann cells, as well as paragangliomas or carotid body tumours, neuroendocrine tumours derived from the neural crest cells of the autonomic nervous system. We describe a parapharyngeal neck schwannoma mimicking a carotid body tumour in terms of characteristic vascular displacement. Carotid body tumours cause splaying of internal and external carotid arteries resulting in the classic appearance of Lyre sign on imaging. However, postoperative histologic examination confirmed a schwannoma and ruled out a carotid body tumour. This case highlights another cause of splaying of the carotid bifurcation other than carotid body tumours. It also discusses the relationship between parapharyngeal neck schwannomas and carotid body tumours to carotid bifurcation on imaging.

TUBERCULOMA – A MIMICKER OF POSTERIOR FOSSA MASS IN YOUNG ADULT

Mohd As, Nadia F.

Bio-Medical Imaging Department, University Malaya Medical Centre, Jalan Prof Diraja Ungku Aziz, Kuala Lumpur, Malaysia.

Keywords: *Tuberculoma, Posterior Fossa Mass, Children.*

Tuberculomas are uncommon intracranial manifestations of tuberculosis, typically presenting as space-occupying lesions. A 20-year-old woman with a history of pulmonary tuberculosis (completed anti-TB treatment) presented with a four-month history of headaches and double vision for one month. MRI showed multiple thick-walled rim-enhancing cystic lesions at the left cerebellum with hypointense signals on T1W, T2W and FLAIR sequences with no restricted diffusion or blooming artefacts. A diagnosis of left cerebellar tuberculoma was reported. Intra-operative findings demonstrated a thick fibrous intra-axial lesion over the left cerebellum. Samples were sent for histopathological examination, consistent with tuberculoma. Direct culture grew acid-fast bacilli (*Mycobacterium tuberculosis* complex). The patient was then started on anti-tuberculous medications for 12 months and was subsequently followed-up in clinic. In conclusion, T2W hypointense signal is useful for diagnosing a focal brain parenchymal mass as a tuberculoma. This pathology must be considered when treating patients in high endemic TB areas.

ARTERY OF PERCHERON INFARCTION: A CASE REPORT

Yogambigai B¹, Anas T²

*1, 2 Radiology Department, Hospital Sultan Abdul Aziz Shah UPM,
Persiaran Mardi UPM, Serdang, Selangor*

Keywords: *Artery Of Percheron, Infarct, Bilateral Thalami Infarction*

Artery of Percheron (AOP) is a rare anatomical variant which arises from the posterior cerebral artery (PCA). AOP infarction is uncommon and with various clinical presentation, the diagnosis relies on imaging findings. We present a rare case of AOP infarct in our centre, in which a 68 year old gentleman with underlying multiple comorbid presented with unresponsiveness. Non-contrast CT brain done in a private institution revealed no abnormalities. Urgent MRI Brain was then performed in our centre which showed areas of restricted diffusion at bilateral thalami, suggestive of acute infarct. The contrasted BB sequence showed stagnant sign at branch of right PCA with corresponding faintly opacified vessel on MRA sequence, likely to be AOP. The variable clinical manifestation and negative findings in standard imaging of CT poses limitation in early diagnosis of AOP infarct. Hence early MRI is vital to identify AOP infarct, particularly in patients with reduced consciousness state.

OMENTAL TORSION, AN UNACCUSTOMED MIMICKER OF ACUTE APPENDICITIS

Sarah J, Faizah M

Affiliations: Department of Radiology, Hospital Tuanku Jaafar Seremban, Negeri Sembilan, Malaysia

Keywords: *Omental Torsion, Inguinoscrotal Hernia*

Omental torsion is one of the rare causes of acute abdominal pain with an incidence of 0.0016 – 0.37% with 4 out of 1000 in patients admitted as appendicitis. The causes can be primary or secondary. In primary omental torsion, it occurs in the absence of any associated or secondary intra-abdominal pathology. Secondary omental torsion, on the other hand is associated with conditions such as tumours, cysts, internal or external herniation, foci of intra-abdominal inflammation and postsurgical wound. Clinical presentation is resemblant to acute appendicitis. Reported cases describe the classical signs as concentric linear strands in the omentum representing the “whirl” sign. However, surgical exploration remains the definitive gold standard for intraoperative diagnosis and therapeutic management.

THE MISSING PIECE OF A BLEEDING PUZZLE

May Foo Tse Ling^{1,2}, Noor Khairiah A. Karim³, Jeyaletchumy A/P Annamalai²

1 Department of Radiology, School of Medical Sciences, Health Campus, Universiti Sains Malaysia, 16150 Kubang Kerian, Kelantan, Malaysia.

2 Department of Radiology, Hospital Raja Permaisuri Bainun, 30450 Ipoh, Perak, Malaysia.

3 Department of Biomedical Imaging, Advanced Medical and Dental Institute, Universiti Sains Malaysia, Bertam, 13200 Kepala Batas, Pulau Pinang, Malaysia.

Keywords: *Obscure Gastrointestinal Bleeding, Small Bowel, Jejunal Ulcer, CT Enterography.*

Overt obscure gastrointestinal (GI) bleeding refers to visible bleeding from source not identifiable on endoscopy. A previously well 42-year-old lady initially presented with fluid overload symptoms secondary to end stage kidney disease. She subsequently developed haematemesis and fresh melaena requiring several blood transfusions. Multiple endoscopy and mesenteric computed tomography (CT) angiography were performed but failed to locate the bleeding source despite on-going GI bleed. She developed haemorrhagic shock requiring intensive care. A multiphase CT enterography was later performed demonstrating contrast extravasation and pooling in the proximal jejunum. She underwent emergency laparotomy surgery. Intraoperatively, she was found to have a jejunal ulcer, and histopathological examination confirmed to be ulceration with granulation tissue. She recovered fully with no further GI bleed. Primary jejunal ulcer is a rare cause of lower GI bleeding and remains a diagnostic challenge. CT enterography is helpful in facilitating accurate diagnosis, thus enabling prompt surgical intervention.

UNLOCKING SOLUTIONS: THE CRUCIAL ROLE OF EMBOLIZATION IN MANAGING BLEEDING COMPLICATIONS IN AML WITH ACUTE PANMYELOSIS AND MYELOFIBROSIS

Suaydiy,O¹, Bayhaqi,NA²

¹Resident of Radiology Specialist Study Program, Brawijaya University – Saiful Anwar Hospital. Malang, Indonesia

²Radiology Department, Brawijaya University– Saiful Anwar Hospital, Malang, Indonesia

Keywords: *Trans Arterial Embolization, Acute Panmyelosis with Myelofibrosis, Uterine Bleeding*

Introduction

Acute Panmyelosis with Myelofibrosis (APMF) is a rare-aggressive form of AML, with bleeding manifestations ranging from petechiae to life-threatening haemorrhages. Interventional radiology has emerged as important adjunctive approach that facilitates targeted vascular occlusion with minimal morbidity.

Report

27 year-old woman with AML and APMF presented recurrent and intractable menometrorrhagia for more than 6 months needing multiple blood transfusion. CT Scan revealed dilatation and tortuous bilateral uterine artery, possibly as the culprit of bleeding. Pre embolization DSA confirmed dilatation of bilateral uterine artery, subsequently embolized using 500-700 micron PVA leading to blushing reduction by 90%. On day 4 of follow-up shows uterine bleeding cessation. However, Patient had episode of melena and was resolved with medical treatment at day 5. Patient was discharged on day 15 after embolization.

Conclusion

Interventional radiology plays an important role in managing recurrent uterine bleeding manifestations of APMF, offering minimal invasive techniques and improving patient outcomes.

PERCUTANEOUS BIOPSY OF RETROPHARYNGEAL LESION; APPROACH AND STRUCTURES TO AVOID

Nasibah MOHAMAD NM1,2, Gayathri LETCHUMANAN GL1,2, Mohd Shafie ABDULLAH MSA1,2, Norhafiza LAZIM NL3

1Department of Radiology, School of Medical Sciences, Universiti Sains Malaysia;

2Department of Radiology, Hospital Universiti Sains Malaysia, Kubang Kerian, Kelantan;

3Department of Otorhinolaryngology-HNS, Universiti Sains Malaysia.

Keywords: *Biopsy, Ct-Guidance, Head And Neck*

Introduction

Retropharyngeal space is a potential space posterior to pharyngeal mucosal and anterior to prevertebral space, from the skull base to the T4 level. The deep head and neck spaces are tricky for biopsy, given the delicate anatomy of the region, including nerves, vessels and salivary glands. We would like to report a percutaneous retropharyngeal mass biopsy case and the available approaches and essential structures to avoid during puncture.

Case report

A 25-year-old male presented with difficulty in swallowing. Oral examination revealed medialisation of the right tonsil. Contrast-enhanced computed tomography (CECT) of the neck showed a right retropharyngeal mass. We proceeded with a CT-guided percutaneous biopsy using a paramaxillary approach. The histopathological examination came back as lymphoid hyperplasia.

Conclusion

CT-guided percutaneous deep neck space biopsy is considered safe and effective. Prerequisite knowledge of anatomy and suitable approaches are mandatory to ensure patient safety and avoid complications.

TWO BECOME ONE: A DILEMMA BETWEEN SOFT TISSUE SARCOMA AND MALIGNANT PHYLLODES TUMOR

Regina Joyce, JOAQUIN P.

Department of Radiology, Dr. Jose N. Rodriguez Memorial Hospital and Sanitarium, Saint Joseph Avenue, Tala, Caloocan City 1427, Philippines

Keywords: *CT: Computed Tomography; MRI: Magnetic Resonance Imaging; NCCN: National Comprehensive Cancer Network; PT: Phyllodes Tumor*

This case report presents a diagnostic challenge between soft tissue sarcoma and malignant phyllodes tumor in a 41-year-old female with a large anterior chest wall mass. Biopsy revealed spindle cell neoplasm, with considerations include high-grade phyllodes tumor and soft tissue sarcoma. The CT imaging findings are large, multilobulated, complex mass with heterogenous enhancement and intrinsic coarse calcifications. There is associated sclerotic and erosive changes of the sternum. Multiple bilateral pulmonary, subpleural and fissural nodules are likewise seen which are likely metastasis. Aforementioned findings cannot differentiate between soft tissue sarcoma and malignant phyllodes tumor. Treatment typically involves surgical excision with wide margins, but chemotherapy may be necessary for metastatic disease. Due to the rarity of both conditions, limited data and imaging constraints pose challenges. Ultimately, despite imaging and histopathologic findings, a definitive diagnosis remained elusive, highlighting the complexities of managing such case.

**NAVIGATING THE CURVE: TORTUOUS VERTEBRAL ARTERY INDUCING NEURAL FORAMINA NARROWING
CAUSING CERVICAL RADICULOPATHY.**

Jennyfer JL¹, Alex LTL¹

¹Radiology Department of Hospital Sultan Ismail, Johor Bahru, Malaysia

Keywords: *Vertebral Artery, Cervical Radiculopathy, Neural Foramina Narrowing*

Cervical radiculopathy is common amongst the world's population, giving rise to symptoms ranging from mild to debilitating caused by compression in the spinal cord or neural foramina through various aetiologies. Therefore, the treatment differs in each patient depending on the cause. We present a case of a 41-year-old lady, suffering from left upper limb numbness since childhood and recent upper back pain, who was managed conservatively. Subsequent cervical spine MRI showed no evidence of significant disc prolapse but on careful scrutinisation, it revealed a tortuous left vertebral artery causing narrowing of C4/C5 neural foramina, abutting the left C5 nerve root. Such cause for radiculopathy is uncommon, as a result, these findings are often unnoticed and may go unreported. This signifies the importance of including vascular abnormalities as differentials in patients with radiculopathies as it bears significant implications in the patient's management.

A RARE CASE OF DIEULAFOY LESION IN A MIDDLE AGED WOMAN.

THEEBASHINII TT1 / SITI ASPALEKHA SA2

1department Of Radiology, Kajang Hospital, Jalan Semenyih, Kajang, Selangor 2department Of Radiology, Kajang Hospital, Jalan Semenyih, Kajang, Selangor

Keywords: *Gastrointestinal, Bleeding, Hematochezia, Dieulafoy, Small Bowel, Vascular.*

Dieulafoy lesion was described by French surgeon in 1898 as a series of arterial based lesions. Its a rare congenital cause of non-variceal upper gastrointestinal haemorrhage. They are most commonly found in the stomach (70%). We present a 26 year old lady with sudden onset of hematochezia, anemic symptoms, hypotensive and tachycardia with Hb of 6.8. Urgent OGDS was inconclusive. CT Angiography Abdomen noted focal contrast extravasation at ileum in the left hypochondrium consistent with acute haemorrhagic event. Urgent laparotomy found a polypoidal lesion within the small bowel which was bleeding and hence wedge resection was done. Histopathological examination revealed a polypoid lesion measuring 4 x 3 x 3mm arising from the mucosa which was consistent with enlarged submucosal blood vessel consistent with Dieulafoy lesion. Although rare, Dieulafoy lesion should be considered in middle aged population presenting with lower gastrointestinal bleeding. It can be life threatening without prompt intervention.

ISOLATED SINONASAL CRANIOPHARYNGIOMA PRESENTED AS LEFT NASAL CAVITY MIXED CALCIFIED AND CYSTIC LESIONS WITH NO SUPRASellar COMPONENT - A RARE CASE.

Nor Azlan Mohd Zin^{1,3}, Amali Ahmad¹, Erica Yee Hing^{2,3}

1 Department of Radiology, Hospital Kuala Lumpur

2 Department of Radiology, Faculty of Medicine, University Kebangsaan Malaysia

3 Hospital Canselor Tuanku Muhriz, Jalan Yaacob Latif, Bandar Tun Razak, Kuala Lumpur, Malaysia

Keyword: *Infrasellar Craniopharyngioma; Sinonasal Tumor; Adamantinomatous Craniopharyngioma; Motor Oil Cyst.*

Introduction:

Isolated sinonasal craniopharyngioma is a very rare benign tumour which less than 30 cases reported.

Report:

18 year-old, female presented with 1 year history of worsening left nasal blockage, epistaxis and left periorbital swelling. Nasal scope shows left nasal fungating mass with easily bleed. Computed Tomography (CT) shows left nasal cavity heterogenous enhancing calcified soft tissue lesion with ethmoidal sinuses erosion. On Magnetic Resonance Images (MRI), it shows mixed signal intensity represent calcified component and microcystic 'motor oil cyst' with no orbit, sella or suprasellar involvement. Patient undergo endoscopic tumour excision which histopathology shows Adamantinomatous type craniopharyngioma. Post-surgery surveillance MRI shows no evidence of tumour recurrence.

Conclusion:

Sinonasal Adamantinomatous type craniopharyngioma although is very rare, in the young adult who presented with unresolved nasal blockage, this disease has to be considered. Surgical resection is the solely treatment with close follow up needed due to high possible of tumour recurrence.

A CASE REPORT OF INTERVENTRICULAR MEMBRANOUS SEPTAL ANEURYSM WITH SUPRAVENTRICULAR TACHYCARDIA: CLINICAL COURSE AND CT FINDINGS.

Nur Syafiqah MR¹, Nurashikin Jamaluddin², Nurul Ain Mat Idris³.

1Department of Radiology, Hospital Sultan Idris Shah, Serdang, Malaysia, 2Department of Radiology, Hospital Raja Perempuan Zainab II, Kota Bharu, Kelantan Malaysia.

Keyword: *Interventricular Membranous Septal; Supraventricular Tachycardia; Computed Tomographic Angiography.*

Interventricular membranous septal (IVMS) aneurysm is an uncommon condition with no accurate incidence. Typically asymptomatic, it can, however, lead to complications such as AV incompetence, conduction defects, and right ventricular obstruction. Here, we present a case of a 49-year-old woman with a history of supraventricular tachycardia (SVT) in 2013, characterized by frequent episodes of palpitations, which were successfully reverted with verapamil. Successful ablation procedures were conducted in 2015, resulting in improved symptoms. Echocardiography incidentally revealed an aneurysmal sinus of Valsalva, while subsequent CT angiography identified an aneurysm originating from the membranous portion of the interventricular septum, measuring 1.1 × 1.5 × 1.8 cm (AP × W × CC). This aneurysm extends into the right ventricle without any outflow tract obstruction. Currently, the patient remains well and asymptomatic, treated conservatively with annual follow-up appointments. This case highlights the significance of recognizing IVMS aneurysms and their management.

VEIN OF GALEN ANEURYSMAL MALFORMATION: A RARE CONGENITAL MALFORMATION OF CEREBRAL VASCULATURE

Chomala R1, Tan TK2, Noor Diyana O3

1Department of Radiology, Hospital University Sains Malaysia, Jalan Raja Perempuan Zainab II, 16152 Kubang Kerian, Kelantan, Malaysia.

2Department of Radiology, Hospital Sultan Abdul Halim, 225, Bandar Amanjaya, 08000 Sungai Petani, Kedah, Malaysia.

3Department of Biomedical Imaging, Advanced Medical & Dental Institute, University Sains Malaysia, 13200, Kepala Batas, Penang

Keywords: *Vein Of Galen Aneurysmal Malformation, Congenital Vascular Malformation, Median Proencephalic Arteriovenous Fistulas*

Vein of Galen aneurysmal malformation (VGAM) is an uncommon congenital malformation of the cerebral vasculature, associated with severe morbidity and mortality, found in neonates, infants and older children. The clinical presentation differs depending on the population of age related to the severity of malformation in which early detection is crucial to ensure a good outcome. Due to its rare entity, we would like to discuss the clinical and radiological features. We report a case of a 1 year old infant, postnatally diagnosed VGAM with non-communicating hydrocephalus and history of PDA and PFO. We would like to highlight the common manifestation as early diagnosis with appropriate imaging modality is required to prevent as an untreatable condition has high mortality rate. Therefore, this case would be to familiarize us with the common manifestation of the disease. A review of literature on clinical findings, diagnosis including radiological findings are herein.

SPONTANEOUS TEMPORAL LOBE HERNIATION INTO TRANSVERSE SINUS MIMICKING VENOUS SINUS THROMBOSIS.

Noor Shahida MP, Jolene LAH, Najwa AK.

Department of Radiology, Hospital Pulau Pinang, Malaysia.

Keywords: *Venous Sinus Thrombosis, Transverse Sinus, Temporal Lobe Herniation*

Herniation of brain parenchymal into dural venous sinus is often an incidental finding and rarely reported. Imaging features include filling defect in the dural venous sinus, hence simulating a thrombosis. We present a case of incidental finding of temporal lobe herniation into transverse sinus through arachnoid granulation. A 59 years old lady with underlying breast carcinoma, post mastectomy and chemoradiotherapy presented with lower back pain. MRI brain and spine was done to look for metastases. Her scan was initially reported as filling defect within left transverse sinus, suggestive of thrombosis and she was treated with anticoagulant. Surveillance MRI done post anticoagulant treatment showed persistent filling defect in the left transverse sinus, which now raises possibility of an alternative diagnosis. This case report is to discuss MRI imaging features of temporal lobe herniation into transverse sinus and other key features to differentiate this condition from other differential diagnoses.

A RARE PRESENTATION OF GASTROINTESTINAL CARCINOID TUMOUR OF THE COLON

Nur Nadia Sabrina AR¹, Patmapriya R¹

1 Radiology Department, Hospital Tengku Ampuan Afzan, Pahang, Malaysia.

Keywords: *Desmoplastic Reaction, Carcinoid, Gastrointestinal*

Introduction

Desmoplastic reaction of tumour denotes the growth of fibrous connective tissue around tumour cells, and has been recognized as a potential prognostic marker for colorectal cancer.

Case Description

60-year-old, Malay lady, with underlying hypertension and morbid obesity, presented with left sided colicky abdominal pain and three days history of no bowel movement or passing flatus, rectal bleed or mucoid stool. Abdominal examination shows tenderness over the left lumbar and iliac fossa region, but no mass palpable. A computed tomography scan done, revealed lobulated enhancing mass adjacent to sigmoid colon with calcification within and desmoplastic reaction of the surrounding tissues.

Conclusion

Carcinoid tumours are a type of neuroendocrine tumour that can occur throughout the gastrointestinal tract. Colon perforation is a rare complication and it's presentation characteristics differ based on the perforation site. In this case, perforation occurred in the cancer site and walled off with the tumoral desmoplastic reaction.

MORPHOLOGICAL ANALYSIS OF SUBAXIAL CERVICAL PEDICLE IN A MALAYSIA POPULATION BY USING COMPUTED TOMOGRAPHY SCAN

Han Liang T1, Shahizon Azura MM2, Kamalnizat I3

1Radiology Department, Hospital Kuala Lumpur, Jalan Pahang, Kuala Lumpur, Malaysia, 2Radiology

Department, Hospital Canselor Tuanku Muhriz UKM, Jalan Yaacob Latif, Cheras, Malaysia.

3Orthopaedic Department, Hospital Canselor Tuanku Muhriz UKM, Jalan Yaacob Latif, Cheras, Malaysia.

Keywords: *Cervical Spine, Morphology, Pedicle, Computed Tomography, Malaysia*

Background

Differences exist in cervical spine morphometric values across different study populations. Malaysia's population is multiracial with a possible variation in the cervical pedicle dimension. An analysis of the cervical pedicle morphology in different ethnicity in our population is crucial in determining any discrepancy if exist that may guide the surgeon to a safer and successful cervical pedicle screw insertion.

Methodology

Subaxial cervical pedicles of 224 subjects were evaluated retrospectively by using computed tomography (CT). Measured pedicle dimensions were outer pedicle width (OPW), inner pedicle width (IPW), outer pedicle height (OPH), inner pedicle height (IPH), and pedicle transverse angle (PTA). Results were compared among sides, genders and ethnics.

Results

The smallest mean OPW and IPW were both at C3 in males (5.36mm and 3.04mm) and females (4.45mm and 2.21mm). The smallest mean OPH was both at C3 in males (8.02mm) and females (6.85mm). The smallest mean IPH was both at C5 in males (3.97mm) and females (3.00mm). The smallest mean PTA was at C7 (40.38°) and the largest mean PTA was at C5 (44.08°). Statistically significant differences of OPW, IPW, OPH, and IPH values were seen in most subaxial cervical level among male gender. Pedicle size was generally larger in Chinese, followed by Malay and Indian.

Conclusion

There is a disparity observed among our study and previous studies from other populations. Familiarity with race-specific data in our population can provide a better guide to our local surgeon in choosing and handling cervical pedicle screw insertion.

HEART-BREAKING EXODUS: A RARE CASE OF PERICARDIAL ABCESS BY DELAYED TUNNELLED CATHETER MIGRATION

Fatin Nadzirah AR¹, Khairina Adliah KA¹, Khatrulnada MS¹, Low JM², Nur Ayub MA³

1 Department of Radiology, Hospital Sultan Haji Ahmad Shah, Temerloh, Pahang, Malaysia.

2 Department of Internal Medicine, Hospital Sultan Haji Ahmad Shah, Temerloh, Pahang, Malaysia.

3 Cardiothoracic Unit Department of General Surgery Hospital Canselor Tuanku Muhriz, PPUKM, Cheras, Wilayah Persekutuan Kuala Lumpur, Malaysia.

Keywords: *Delayed Tunnelled Catheter Migration, Cardiac Perforation, Pericardial Abscess*

Tunnelled haemodialysis catheters via internal jugular vein (IJV) are commonly used to perform haemodialysis in end-stage renal failure patients. Due to its increasing use, the complication rates have also escalated. Rare complications of these catheter insertions include heart perforations (incidence of 0.25-1.4%). We present a case of late migration of right IJV tunnelled haemodialysis catheter causing right atrial perforation 2 months post insertion with initial presentation of purulent fluid on aspiration before dialysis. Chest X-ray revealed deep-seated catheter tip, raising suspicion of malposition. Multiphasic CT unveiled right atrial perforation by the catheter tip with pericardial collection. Subsequently, exploratory sternotomy and atrial wall repair performed. Intraoperatively, it was confirmed that the catheter tip had eroded and perforated at cavo-atrial junction. She was fully recovered from the operation. Migration and perforation of a tunnelled haemodialysis catheter can occur late after implantation and is life-threatening thus requiring immediate diagnostic imaging upon clinical suspicion.

3T MRI FINDINGS OF POST TRAUMATIC ANOSMIA: A CASE REPORT

Geetha Rakwan¹, Muhammad Zakwan Bin Yahya¹

¹Department of Radiology, SASMEC@IIUM Jalan Sultan Ahmad Shah, 25200 Kuantan, Pahang, Malaysia

Keywords: *Anosmia, Olfactory Dysfunction, Traumatic Brain Injury*

Olfactory dysfunction can be caused by various aetiologies including traumatic brain injury, which has a reported incidence of 19%. We report a case of traumatic brain injury causing anosmia in a 36-year-old lady with no previous medical illness. She presented with loss of sense of smell for the duration of a year, which began after an episode of fall. CT Paranasal Sinuses was performed to rule out cribriform plate fracture, which revealed normal findings. Subsequently, MRI Brain was performed to assess the olfactory bulb and frontal lobes, which revealed characteristic atrophy of the right olfactory bulb with encephalomalacia changes of the bilateral gyrus rectus, and medial orbital gyrus consistent with the sequela of traumatic brain injury. Olfactory dysfunction has a significant impact on quality of life. MRI is a valuable objective investigative tool for assessing the olfactory pathway, identifying the cause of olfactory dysfunction, and for proper prognostications.

THE IMPACT OF THE AWARENESS CAMPAIGN ON THE FISTULOPLASTY REFERRAL AND SUCCESS RATE OF FISTULOPLASTY IN HOSPITAL USM

Nik Mohamed Firdaus NMK¹, Nasibah M¹

1Department of Radiology, Hospital Universiti Sains Malaysia

Keywords: *Meccdas, Fistuloplasty*

Background

The Malaysian East Coast Dialysis Access Symposium (MECDAS), initiated in 2017 by the Chronic Kidney Disease (CKD) unit and the East Coast Neuroradiology and Interventional Radiology (ECSNIR), is an awareness program designed to promote available services at the intervention unit and raise awareness about fistula failure. This study aims to evaluate the effectiveness of the MECDAS campaign as an intervention strategy in influencing fistuloplasty referral rates and procedures at Hospital Universiti Sains Malaysia (Hospital USM).

Methodology

This single-center retrospective cross-sectional study evaluated fistuloplasty procedures performed on end-stage renal failure patients with failed fistulas. The study aimed to determine the referral rates for fistuloplasty before and after the campaign by analyzing the number of referrals over a 10-years period. Additionally, the association between the timing of referrals (pre- or post-campaign) and the outcomes of fistuloplasty procedures was assessed using the Chi-Square Test.

Results

The analysis revealed a notable increase in the number of cases during the post-campaign period. However, the referral rates for fistuloplasty, categorized as early or late referrals, did not show a statistically significant difference between the pre- and post-campaign periods. Nonetheless, according to the Pearson's chi-square test, there was a significant association between early referral rates and successful outcomes for fistuloplasty procedures.

Conclusion

The study found a significant association between early referral and higher success rates of fistuloplasty procedures in end-stage renal disease patients. However, the timing of referrals did not significantly differ between the pre- and post-campaign periods. Further investigations incorporating other potential contributing factors and alternative assessment methods are warranted to enhance the outcomes of fistuloplasty interventions.

ATYPICAL CASE OF RUPTURED INTRACRANIAL DERMOID CYST

Nadiyah M¹, Norafida B², Ruwaida AR¹, Mohamad Syafeeq Faez MN², Ezamin AR²

¹Department of Radiology, Hospital Sultan Idris Shah, Serdang, Selangor, Malaysia,

²Department of Radiology, Hospital Sultan Abdul Aziz Shah, Serdang, Selangor, Malaysia.

Keywords: *intracranial dermoid cyst, ruptured, altered behaviour, middle cranial fossa*

An adult female with underlying Major Depressive Disorder presented with recurrent depressive episodes and altered behaviour. Plain CT and MRI showed right middle cranial fossa lesion with a typical CT and MRI features of ruptured dermoid cyst. Intracranial dermoid cysts are uncommon lesions with characteristic imaging appearances. They are rare, benign, congenital, slow-growing cystic lesions. On imaging, they are usually well-defined lobulated, midline masses that have fat density on CT and high signal intensity on T1- with variable signal on T2-weighted MR images, unlike intracranial lipomas, which follow fat density on all sequences. Rupture of intracranial dermoid cysts is a relatively uncommon phenomenon and characteristically associated with fat density material in the subarachnoid spaces, such as intraventricular fat-fluid levels or fat globules in the sulci. It can cause serious complications such as chemical meningitis, vasospasm, and cerebral infarction. MRI is a modality of choice to assess the extension of complications.

SPONTANEOUS RECOVERY OF BILATERAL OVARIAN VEINS RUPTURE FOLLOWING A MOTOR VEHICLE ACCIDENT IN A NON-PREGNANT WOMAN

Tan GX¹, Jessica Hwang Zhen Shan²

^{1,2} Radiology Department, Hospital Sultan Idris Shah Serdang, Selangor, Malaysia

Keywords: *Varicose ovarian veins, Ovarian veins rupture, Retroperitoneal hematoma*

Introduction:

Ovarian vein rupture is rare with only a few cases reported in international literature. We report a very rare case of retroperitoneal hematoma caused by rupture of the varicose veins of bilateral ovaries.

Report:

A 62-year-old lady who presented with vague lower abdominal pain after alleged hit by a motorcycle whilst walking. Post trauma, she was able to self ambulate to the hospital for treatment. Her admission contrasted computed tomography revealed bilateral retroperitoneal hematomas originated from rupture of the abnormally dilated bilateral ovarian veins which was confirmed on subsequent portovenous and delayed scans. No active arterial hemorrhage demonstrable. No nutcracker syndrome. She was hemodynamically stable hence treated conservatively in the ward. She was discharged home subsequently in few days time.

Conclusion:

In a case of a traumatic event with acute abdomen in a female patient demonstrating retroperitoneal hematoma, the possibility of ovarian veins hemorrhage should be kept in mind.

GIANT ADENOMATOID ODONTOGENIC TUMOR OF MAXILLA: RADIOGRAPHIC AND PATHOLOGIC FINDING

Humairah¹, Rafikah, R², Sri, A², Nur, AB², dr. Dario, N²

¹Radiology Resident, Radiology Department, Faculty of Medicine, Hasanuddin University, Makassar, Indonesia

²Radiology Consultant, Radiology Department of DR Wahidin Sudirohusodo Hospital, Faculty of Medicine, Hasanuddin University, Makassar, Indonesia²

Keywords: *Adenomatoid Odontogenic Tumor, Maxilla, Radiologic Finding*

Adenomatoid odontogenic tumors (AOTs) are rare benign locally aggressive epithelial tumors, comprising 3% of all odontogenic tumors. Often misdiagnosed as odontogenic cysts (OC), both presents as painless lesions. We present a 18 - y.o female presented with lump on left maxilla. Non-Enhanced Brain CT-Scan revealed a well-defined expansile dominant cystic lesion (3-28 HU) containing tooth measuring 6.4 x 4.7 x 5.7 cm expanding into the left maxillary sinus, alveolar process, inferior orbital wall, and left nasal cavity causing septum deviation. Both AOT and OC showing unilateral radiolucent lesion with clear boundaries. However, regular lesion morphology shows that CT were consistent with AOT and confirmed with pathology examinations which revealed thick fibrous connective tissue with foci of bone trabeculae in the wall and nodular tumor nests of proliferating odontogenic epithelial cells inside the cyst. In summary, AOTs are rare odontogenic tumors and should be included in the differential diagnosis of cystic maxillary lesions.

REVIEW OF BREAST CANCER IMAGING CHARACTERISTICS: CORRELATION WITH CLINICOPATHOLOGICAL FEATURES AND TUMOUR MICROENVIRONMENT

Raihanah H¹, Noor Khairiah K¹, Fakhriah Aiman MB¹, Norazilla MA¹, Siti Kamariah CM¹, Radhiana H¹, Azian AA¹, Mohd Radhwan A¹, Nor Ain R¹, Khairunisa AA²

¹Department of Radiology, Kulliyah of Medicine, International Islamic University of Malaysia, Kuantan, Malaysia

²Department of Pathology and Laboratory Medicine, International Islamic University of Malaysia, Kuantan, Malaysia

Keywords: Breast Cancer, Ultrasound, Mammography, Molecular Subtypes, Histopathology, Tumour-Infiltrating Lymphocytes, Lymphocyte-Predominant Breast Cancer

Background

Breast carcinoma (BC) is a highly heterogeneous disease with multiple laboratory-based facets critical for treatment planning, prediction of treatment response, and long-term survival rate. Of late, tumour-infiltrating lymphocytes (TILs) have also emerged to influence patient prognosis. Understanding how these relate with sonographic and mammographic characteristics of BC can guide personalized treatment strategies. This literature review aims to investigate the association between laboratory and imaging characteristics of BC.

Methodology

A comprehensive literature search was conducted, including studies published between 2000 till 2023. The key findings from these studies were analysed and synthesized to provide a comprehensive overview of the current knowledge in this field.

Results

Tumors with circumscribed margins were linked to high grade, hormone receptor-negative, and triple-negative BC (TNBC). Lesions eliciting posterior acoustic shadowing were likely to be hormone receptor positive. Posterior acoustic enhancement, circumscribed margin and large tumor size were related to TNBC. The presence of posterior mixed features with microcalcifications was related to HER2-enriched subtypes. Tumor margins were a robust predictor of histologic grade. Spiculated margins and sonographic posterior shadowing are associated with grade 1; while oval / round shapes, indistinct / microlobulated margins and sonographic posterior enhancement are associated with grade 3. Lobulated shape, sonographic hypoechogenicity and posterior acoustic enhancement were predictors of lymphocyte-predominant BC.

Conclusion

Mammography and ultrasound have demonstrated potential in assessing clinicopathological features and tumour microenvironment in BC. Further research are needed to establish the clinical utility of BC imaging features to enhance patient risk stratification and directing individualized treatment plans.

(248 words)

UNRAVELLING THE MYSTERY: NAVIGATING AN UNUSUAL CASE OF ACUTE ABDOMEN

May Foo Tse Ling^{1,2}, Noor Khairiah A. Karim³, Sharmila A/P Arumugam², Preetvinder Singh A/L Dheer Singh²

1 Department of Radiology, School of Medical Sciences, Health Campus, Universiti Sains Malaysia, 16150 Kubang Kerian, Kelantan, Malaysia.

2 Department of Radiology, Hospital Raja Permaisuri Bainun, 30450 Ipoh, Perak, Malaysia.

3 Department of Biomedical Imaging, Advanced Medical and Dental Institute, Universiti Sains Malaysia, Bertam, 13200 Kepala Batas, Pulau Pinang, Malaysia.

Keywords: *Acute Gastric Volvulus, Organo-Axial, Contrast Enhanced Computed Tomography*

Acute gastric volvulus is an uncommon surgical emergency, causing gastric outlet obstruction or vascular compromise with risk of rapidly developing strangulation and stomach perforation. A 75-year-old lady with previous history of laparoscopic paraesophageal hernia repair, complained of worsening abdominal pain and vomiting for 2-3 days. Clinically she had generalized abdominal tenderness and palpable vague central abdominal mass. Laboratory investigations showed leucocytosis and decompensated metabolic acidosis. Diagnosis of septic shock secondary to strangulated incisional hernia was initially made. However contrast enhanced computed tomography (CECT) of abdomen later revealed organo-axial gastric volvulus as evidenced by reversal of lesser and greater curvatures location with abrupt narrowing and twisting of pylorus, which was confirmed intra-operatively. The diagnosis can be challenging as patients often came with non-specific abdominal symptoms. CECT is helpful in such cases when diagnosis is in doubt as early surgical intervention are crucial in management of such condition.

**ATYPICAL PRESENTATION OF LOWER LIMB WEAKNESS AND PAIN WITH PARAVERTEBRAL SOFT TISSUE
MASSES IN ACUTE LYMPHOBLASTIC LEUKAEMIA: A RARE CASE REPORT**

Fadzrie Azim FD¹; Masiyati J¹, Diyana A²

1Radiology Department, Malacca Hospital, 2 Pathology Department, Malacca Hospital.

Keywords: *Leukaemia, Weakness, Paravertebral, Soft Tissue*

Acute Lymphoblastic Leukaemia (ALL) is the most common haematological malignancy in children accounting for 80% of cases, known for its systemic manifestation. Occasionally it may present with unusual extramedullary involvement. We present a case of a 3 year old boy presented with chronic recurrent lower limb pain and constitutional symptoms. Despite initial clinical and laboratory findings to be non-specific, initial lower limb X-ray radiological examination reveals symmetrical osteopenic bony lucencies with supplementary MRI lower limb and spine showing multiple medullary bone lesions with paravertebral soft tissue masses. Further diagnostic workup including bone marrow aspiration and biopsy confirmed diagnosis of pre-B cell acute lymphoblastic leukaemia, in which patient has commenced on an intensive chemotherapy regimen. This case underscores the importance of considering haematological malignancies as part of the differentials in patients presenting with unexplained neurological symptoms with soft tissue masses. Early recognition and management are crucial to optimise patient outcome.

ABSENT MECKEL'S CAVE AS A CAUSE OF TRIGEMINAL NEURALGIA

Hafeeza M 1, Hasyma AH 1, Hilwati H 2

1 Department of Radiology, Hospital Sultan Abdul Aziz Shah, Upm

2 Department of Radiology, Hospital Sultan Al-Abdullah, Uitm

Keywords: *Neuroradiology, Trigeminal Neuralgia, Absent Meckel's Cave*

Trigeminal neuralgia is one of the most common forms of craniofacial neuropathic pain with female predilection. It is most commonly due to vascular compression by adjacent blood vessels; usually the superior cerebellar artery. Other causes include external compression by tumours or demyelinating disease such as multiple sclerosis. Absent or deficient Meckel's cave is one of the rarest and least reported aetiology of trigeminal neuralgia. We present a case of a 34-year-old lady with a 3-week history of right sided facial pain of electrical sensation, triggered by touch, chewing and brushing her teeth. She was prescribed with Amitriptyline and Gabapentin for the treatment of trigeminal neuralgia. Subsequent MRI revealed deficient right Meckel's cave with atrophy of the cisternal and the cavernous segment of the ipsilateral trigeminal nerve. We will discuss on the imaging features and the diagnostic criteria.

CASE OF AN UNFORESEEN CAUSE OF SMALL BOWEL OBSTRUCTION – SMALL BOWEL BEZOAR

Sharllina P1, Mohd Norsyafi H1, Emy Saera R1

Radiology Department, Hospital Sungai Buloh, Jalan Hospital, Sungai Buloh, Malaysia

Keywords: *Phytobezoar, Small Bowel Faeces Sign*

Bezoars are aggregation of indigestible contents within the gastrointestinal tract and can cause small bowel obstruction. Radiological findings are valuable for the diagnosis of bezoars in the preoperative period. We report a case of a 68-year-old male with underlying diabetes mellitus, hypertension and major depressive disorder who presented with bowel obstructive symptoms for 4 days. Abdominal radiograph showed small bowel dilatation. Contrast-enhanced CT demonstrates small bowel faeces sign with mottled gas-patterned intra-luminal mass at the distal jejunum and small bowel obstruction. Patient underwent exploratory laparotomy. Postoperative diagnosis of impacted food bezoar within the jejunum was concluded. Histopathological examination confirmed the diagnosis of phytobezoar. Patient was discharged on day 11 postoperatively. Bezoar is a rare cause of small bowel obstruction which could mimic small bowel faeces sign on CT. Role of imaging is essential in the diagnosis of this case aiding in early treatment.

NEUROIMAGING MANIFESTATIONS OF WILSON'S DISEASE

Tew Hui Sin, Hazwan Amzar Khairul Annuar

Department of Biomedical Imaging, Faculty of Medicine, Universiti Malaya, 50603 Kuala Lumpur, Malaysia.

Keywords: *Wilson's Disease, Double Panda Sign, Kayser-Fleischer Rings, MRI*

A 19-year-old woman presented with progressive slurring of speech over three years, accompanied by sudden-onset unsteady gait for two weeks. Neurological examination revealed rigidity and ataxic gait. CT brain showed symmetrical hypodensities in bilateral thalami and midbrain. MRI revealed T2 hyperintensity involving both putamen, thalami, internal capsules, splenium of the corpus callosum, and brainstem. Notably, the "double panda sign" was evident, indicative of midbrain and pons involvement, alongside severe midbrain atrophy. Areas of restricted diffusion were seen at the splenium of the corpus callosum and both thalami. Further investigations revealed bilateral Kayser-Fleischer rings and reduced serum ceruloplasmin levels, confirming the diagnosis of Wilson's disease. Oral Penicillamine therapy was initiated. This case highlights the importance of recognizing diverse neurological manifestations of Wilson's disease for timely intervention and management.