

A LIGHT EMITTING DIODE IN A CHILD'S AIRWAY

L Chan¹, Yik YP², KN Subramaniam³ and TM Ramanujam²

Department of ¹Anaesthesiology, Department of ²Surgery, Department of ³Otorhinolaryngology University of Malaya Medical Centre, 5060 Kuala Lumpur, Malaysia

ABSTRACT: A case of an unusual foreign body aspiration in a child was managed recently. The mainstay in treatment is urgent extraction of the aspirated foreign body via a bronchoscope under general anaesthesia. A thoracotomy may sometimes be required when endoscopic retrieval fails, as illustrated by this case. She had an increased hospital stay of 16 days, was ventilated for 8 days and her most serious complication was septic shock from which she recovered. (*JUMMEC 2002; 2:150-151*)

KEYWORDS: Foreign body aspiration, children.

Introduction

Foreign body aspiration (FBA) is primarily a disease of children under 4 years old. Significant morbidity and mortality continue to be associated with FBA in children who are at risk because of their curious nature, strong oral tendency and lack of molar teeth.

We report the case of a child who required a thoracotomy following a failed bronchoscopic attempt to extract a light emitting diode in the right main bronchus.

Case report

A five years' old Indian child started coughing and developed fever one day after playing with a light emitting diode (LED). Three days after the incident, she told her mother that she had ingested the LED. She was then brought into the University Hospital Kuala Lumpur for an evaluation. Her presenting complaints were fever and cough but there was no shortness of breath. There was no difficulty in swallowing. Chest auscultation revealed slightly reduced air entry in the right lower lung field. A CXR confirmed the presence of a foreign body in the right main bronchus (Fig. 1).

Emergency removal of the LED through a rigid bronchoscope under general anaesthesia failed and the procedure was abandoned because of oxygen desaturation and bleeding. She was ventilated and managed in the intensive care unit (ICU) to allow airway oedema and inflammation to subside. She received antibiotics (amikacin, metronidazole, ampicillin-sulbactam) for infection control. A postoperative CXR showed that the LED had migrated further down the right main bronchus into the right lower lobe bronchus and that one of the 2 pins of the LED was bent (Fig 2).

After 4 days of uneventful respiratory support she underwent a right thoracotomy and the LED was removed

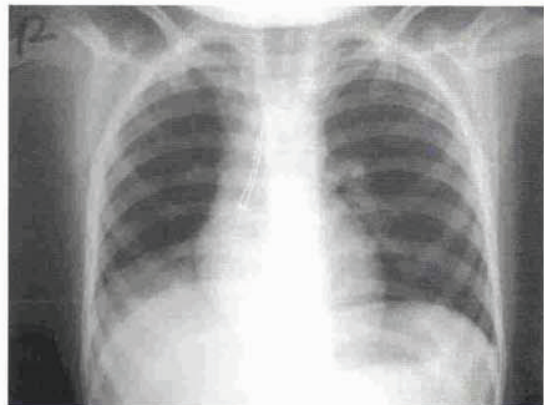


Fig 1. LED in the right main bronchus

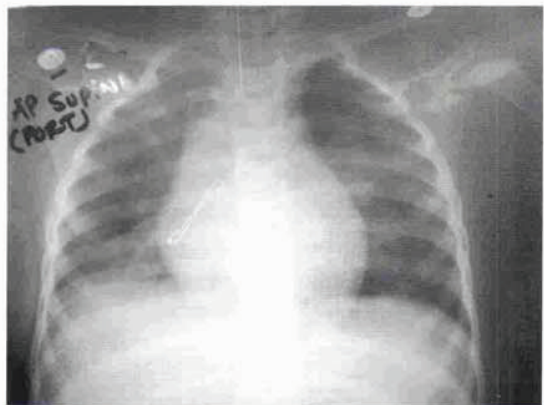


Fig 2. Position of the LED postoperative

Correspondence:

Lucy Chan

Department of Anaesthesiology
University of Malaya Medical Centre
50603 Kuala Lumpur, Malaysia

through a bronchotomy of the right lower lobe bronchus. It was noted that there was granulation tissue with pus proximal and distal to the LED (Fig 3). A chest drain was inserted.

About six hours after the operation, she developed septic shock but responded well to fluids, ionotropes and antibiotics (cloxacillin, imipenem, amikacin and metronidazole). A CXR showed right bronchopneumonia. She recovered from her complications and was extubated on the fourth postoperative day. There was some concern that a bronchopleural fistula might have developed because there was increased bubbling from the chest drain following extubation. However, the bubbling settled and the chest drain was removed five days after extubation. She was discharged well eight days after extubation.




Fig 3. The LED just before removal through bonchotomy

Discussion

Aspiration of a foreign body into the airway remains a major cause of morbidity and mortality in childhood. Food items (peas, corn, beans) are the most common in infants and toddlers, while older children are likely to aspirate non-food items (parts of a ballpoint pen, safety pin). Although a choking crisis is the most common symptom, other frequent symptoms are protracted cough, fever and breathing difficulties (1,2). Radiographic imaging is helpful as in this patient but negative-imaging studies (with vegetative foreign body) do not exclude a foreign body. A careful history and a high index of suspicion may sometimes be the only means of early intervention. Delayed removal after months or years carry increased morbidity. Cataneo et al reviewed a 20-year experience with the treatment of 74 patients (93.8% children) for FBA and observed that the most serious complication was bronchiectasis requiring resection in 6 patients who had the FB retained for years in the lung (3).

The bronchoscope remains the mainstay in the retrieval of airway foreign body (3). The use of the bronchoscope is not without risks as illustrated by this case. Objects with points or sharp edges (such as the LED)

require special care and expertise in removal so as to avoid perforation or laceration of airway. There were also potential problems related to hyperventilation from an obstructed right bronchus, haemorrhage and spillage into the left lung, perforation with mediastinitis and sepsis. The bleeding and bronchial oedema that resulted from the failed bronchoscopic attempt increased hospital stay. Zerella and his researchers looked at 293 bronchoscopies for airway FB in children over 10 years (5). They noted 3 complications: one had vocal cord injury requiring temporary tracheostomy, one had tracheal laceration from removal of an aspirated tooth and another had severe post-operative subglottic oedema that prolonged hospital stay by 4 days.

On rare occasions, when endoscopic removal is not feasible or unsuccessful, open surgery is indicated. A case was reported where a tracheotomy was performed to extract a large foreign body which could not be removed via the subglottic region(6). Fewer than 2% require thoracotomy as most FBs are removed with the use of bronchoscope.

The septic shock that followed the open surgery (delayed removal took place 7 days after aspiration of the LED) might have been prevented if thoracotomy was performed on the day of admission to remove the LED instead of a difficult bronchoscopic procedure.

Successful outcome with reduced morbidity of FBA depends on early diagnosis, urgent extraction of the foreign body and effective control of any complications that may arise. At the source level, preventive strategy in health education and community awareness programs should also consider that children risk exposure at home because of articles brought home by their parents from their place of work.

References

1. Swanson KL, Edell ES. Tracheobronchial foreign bodies. *Chest Surg Clin N Am* 2001; 11(4): 861-72.
2. Metrangolo C, Monetti C, Meneghini L, Zadra N, Ginisti F. Eight years' experience with foreign-body aspiration in children: what is really important for a timely diagnosis? *J Pediatr Surg* 1999; 34(8): 1229-31.
3. Cataneo AJ, Reibschied SM, Ruiz Junior RL, Ferrari GF. Foreign body in the tracheobronchial tree. *Clin Pediatr (Phila)* 1997; 36(12): 701-6.
4. Barrios FJE, Gutierrez C, Lluna J, Vila JJ, Poquet J, Ruiz-Company S. Bronchial foreign body: should bronchoscopy be performed in all patients with a choking crisis? *Pediatr Surg Int* 1997; 12(2-3): 118-20.
5. Zerella JT, Dimler M, McGill LC, Pippus KJ. Foreign body aspiration in children: value of radiography and complications of bronchoscopy. *J Pediatr Surg* 1998; 33(11): 1651-4.
6. Fraga JC, Neto AM, Seitz E, Scholof L. Bronchoscopy and tracheotomy removal of bronchial foreign body. *J Pediatr Surg* 2002; 37(8): 1239-40.