

MAGNETIC RESONANCE IMAGING EVALUATION OF INCIDENTAL CARDIAC IRRADIATION DURING LEFT BREAST CANCER RADIOTHERAPY: A SYSTEMATIC REVIEW

Mohammad Gunda N¹, A. Karim NK^{1,2,3}, Mad Naser MN⁴, Garba I⁵.

¹Department of Biomedical Imaging, Advanced Medical and Dental Institute, Universiti Sains Malaysia, Bertam, 13200 Kepala Batas, Pulau Pinang, Malaysia

²Breast Cancer Translational Research Programme (BCTRP), Advanced Medical & Dental Institute, Universiti Sains Malaysia, Bertam, 13200 Kepala Batas, Pulau Pinang, Malaysia

³Heart Failure Research Initiative, Advanced Medical & Dental Institute, Universiti Sains Malaysia, Bertam, 13200 Kepala Batas, Pulau Pinang, Malaysia

⁴Lam Wah Ee Hospital, Jelutong, 11600 George Town, Pulau Pinang, Malaysia

⁵Department of Radiography, Faculty of Health Sciences, University of Malta, Msida, Malta.

Correspondence:

Noor Khairiah A. Karim,
Department of Biomedical Imaging,
Advanced Medical and Dental Institute,
Universiti Sains Malaysia, Bertam,
13200 Kepala Batas,
Pulau Pinang, Malaysia
Email: drkhairiah@usm.my

Abstract

Breast cancer is one of the most common malignant tumours among women. Radiotherapy plays a key role in the management of breast cancer patients. However, radiotherapy results in incidental exposure of the heart. This work systematically reviewed articles on magnetic resonance imaging (MRI) evaluation of cardiac changes due to incidental cardiac irradiation during left breast radiotherapy and also to identify the MRI sequences used during evaluation. A systematic literature search was conducted in the following three selected databases: PubMed, ScienceDirect and Scopus using carefully defined search terms related to the left breast, MRI and cardiac irradiation. The quality of the included papers was determined using the critical appraisal skills programme for qualitative studies. The review had a total of six articles that were screened and graded for quality. Articles graded as high and moderate in terms of quality assessment were included and characterised based on the sample size, type of cancer treated, treatment methods employed, and period MRI was performed after radiotherapy. The review showed that breast cancer patients who had radiotherapy also developed radiation-induced heart disease (RIHD) few months post treatment. The review noted that breast cancer patients receiving radiation treatment are at high risk of RIHD which may affect their quality of life after completion of treatment. Cardiac MRI facilitates early detection of RIHD, hence better patient management.

Keywords: Breast Cancer, Magnetic Resonance Imaging, Radiation-Induced Heart Disease, Radiotherapy

Introduction

Radiotherapy (RT) is currently administered to about 50% of the patients with malignant neoplasms (1). Approximately 25–30% of patients with malignant neoplasm undergo thoracic radiation therapy which have been proven to improve wellbeing and prolong patients' survival (1,2). Radiotherapy is one of the most principal methods for the treatment of cancerous tumours (3). However, in the process of radiotherapy for the thoracic tumours such as breast cancer, esophageal cancer, lung cancer, and mediastinal lymphoma, the major organ located in the mediastinum which include the heart is affected inevitably by incidental irradiation

(3). The irradiation resulted in cardiac injury/toxicity and various kinds of radiation-related cardiac disease (1,2). Although it was initially thought that cardiovascular system was somewhat resistant to damage induced by radiation, it was until 1930s, when evidence of cardiac injury arising from thoracic radiation exposure was observed to be accumulating (4). In the 1980s, it became well known that radiotherapy in breast cancer may have adverse effects on the heart of long-term survivors (5). Radiation-induced heart disease (RIHD) is a term used to describe all cardiac complications associated to radiotherapy (1). RIHD became recognizable because significant cardiac injury was observed to occur after a dose of higher than 30 gray was administered to the

whole heart (1). RIHD is one of the major complications of cancer treatment that can occur during, shortly after, and even many years post-delivery of treatment (6).

Breast cancer is the most common malignancy in women. Fortunately, it is curable, due to early diagnosis and advances in treatment resulting in high rates of survival, with a figure of about 89% (7). However, in 1975, it was reported that patients with breast cancer treated with radiotherapy showed established evidence of RIHD (4).

Magnetic resonance imaging (MRI) plays a vital role in the field of oncology. It serves as a valuable tool for the non-invasive quantitative and qualitative evaluation of cardiovascular system (8,9). In recent years, the use of cardiac magnetic resonance imaging (CMR) is growing, and it has become instrumental in early diagnosis of cardiac toxicity related to treatment including changes in cardiac chamber structure and function, tissue properties and myocardial perfusion (8,10). This work systematically reviewed articles on MRI evaluation of cardiac changes due to incidental cardiac irradiation during left breast radiotherapy and also to identify the MRI sequences used during evaluation.

Materials and Methods

Systematic literature search was conducted in three databases; ScienceDirect, PubMed and Scopus. They were the databases accessible to the researcher and index journals in radiotherapy, radiology and medical physics. The literature search was conducted using the 'Preferred Reporting Items for Systematic Reviews and Meta- Analysis' (PRISMA) flow chart search strategy (refer Figure 1) (11,12). PRISMA provides an easy way in which authors can ensure complete and transparent method of reporting of systematic reviews (11). Relevant articles were searched for in the databases and selected ones documented at each stage during the screening process. A complimentary manual search via google scholar preceded to make sure that any article(s) published on CMR that was (were) not indexed in the selected databases was (were) not excluded in the systematic review as well. In the same vein, an email alert was set up with the selected databases and linked to the researchers e-mail address to notify the researcher if a new article that is relevant to the review has been published. Appropriate search terms for the review were determined using the model: Population, Intervention and Comparator, Observation (PICO) elements (13,14) (refer Table 1). The element comparator was not applicable to this systematic review hence: population: left breast cancer radiotherapy patients, intervention: magnetic resonance imaging and outcome: cardiac irradiation (13).

The concepts; breast cancer, Radiotherapy, Magnetic Resonance Imaging, cardiac irradiation were derived from the PICO model and search terms for the derived concepts were established using the Medical Subject Headings (MeSH)(15). The lists of search terms were

doubled checked by the researcher and face validation by the researcher followed in order to ensure that the established search terms were suitable and can be deployed to search for relevant articles related to established concepts. Content validation was carried out with the help of six (6) experts, two (2) each in the field of radiology, radiography and radiotherapy with a minimum experience of six years of practice in their respective disciplines. The experts validated the search terms and graded it based on a scale developed by the researcher. The criteria for grading was based on the following: Not relevant=0, Somewhat relevant=1, Relevant=2, Highly relevant=3. Validity index (VI) was calculated based on their grading and a validity index value of 85% was obtained for the search terms. The VI value obtained was within acceptable limits because search terms are considered valid only if the researcher was able to obtain a validity index value > 80% (16).

A test run search was conducted by the researcher in the PubMed database and relevant articles related to the study were identified before the terms were applied in the main study (Table 2). In ScienceDirect database where the acceptable limit for boolean operators applicable for search is less than or equal to eight (17), the search for the review was conducted using two (2) most relevant out of the validated search terms each. A step-by-step search for each term as recommended by PRISMA was carried out in the three databases selected for the study (13).

Screening of identified articles was first conducted by the primary author and then another expert re-screened the articles to ensure that only those articles that met the inclusion criteria are included in the study. The articles included are those of left breast cancer patients that had radiotherapy and whose hearts were evaluated using MRI. The excluded articles were those of: Left breast cancer patients that had chemotherapy and whose hearts were evaluated using MRI, left breast cancer patients that had radiotherapy and whose hearts were evaluated using computed tomography and/or echocardiography, left breast cancer patients that had chemotherapy and whose hearts were evaluated using computed tomography and/or echocardiography and other cancer patients apart from breast cancer patients who had radiotherapy and their hearts evaluated with MRI.

Quality Evaluation

The primary author assessed the quality of each of the screened articles with the aid of critical appraisal skills programme (CASP) checklist for qualitative studies (18,19). The articles were assessed based on quality as high, moderate and weak (18,19). Two (2) additional experts randomly evaluated a sample of five (5) selected articles from the screened articles to ensure that screening and grading process was done appropriately. The decision from the two experts for the five randomly selected articles was tallied.

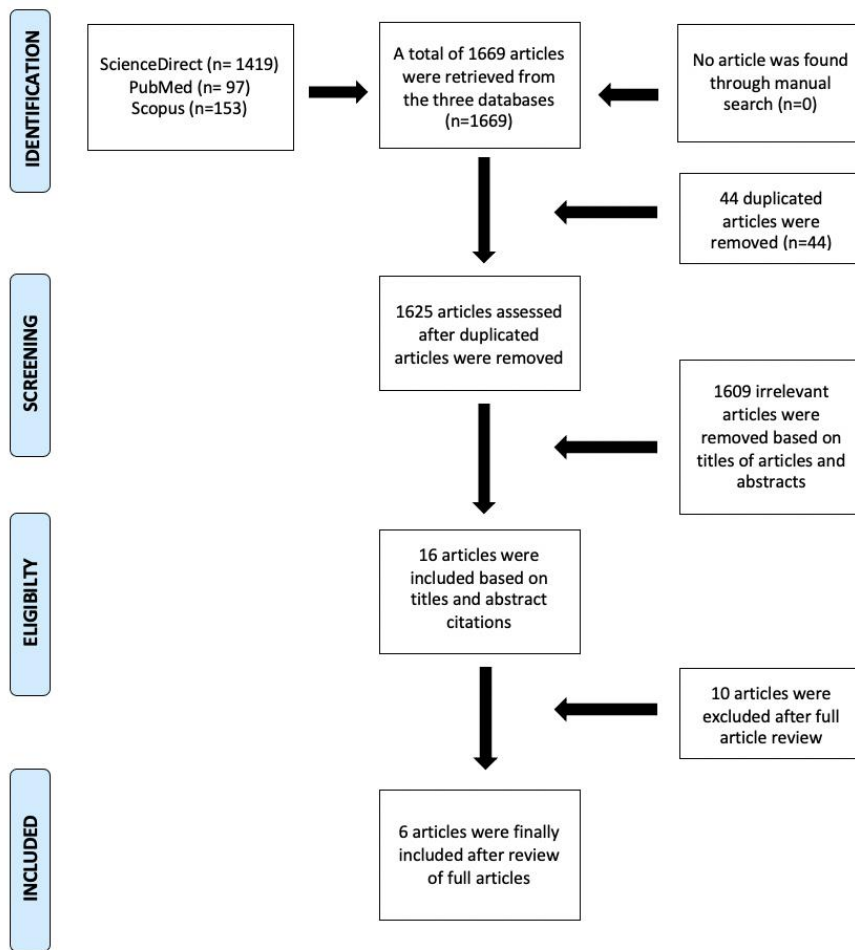


Figure 1: PRISMA flow chart

Table 1: Search terms acquired from research questions with the aid of PICO model

RESEARCH QUESTION	EVALUATION OF INCIDENTAL CARDIAC IRRADIATION IN LEFT BREAST CANCER RADIOTHERAPY PATIENTS USING MRI: A SYSTEMATIC REVIEW
Question components	
Population	Left breast cancer radiotherapy patients
Intervention	Magnetic resonance imaging (MRI)
Comparator	N/A
Outcome	Cardiac Irradiation

Table 2: Characteristic of the six articles included in the review

S/N	AUTHORS	YEAR	SAMPLE SIZE	SIDE OF BREAST CANCER	PERIOD POST MRI	THERAPY RECEIVED	MRI SEQUENCE USED	FINDINGS FROM THE MRI
1	Speers et al.	2021	51	Left breast cancer	3 months (+/- 2 weeks)	Radiotherapy + chemotherapy	SSFP, T2 and T1	No significant cardiac abnormalities
2	Bergom et al.	2020	20	Bilateral breast cancer	8.3 years	Radiotherapy + chemotherapy	SSFP cine sequence	No significant cardiac abnormalities except for 2 patients
3	Andersen et al.	2020	135	Bilateral breast cancer	Before, during and upon completion	Radiotherapy	SSFP cine sequence	Decline in LVEF (cardiac dysfunction)
4	Jasmin et al.	2018	115	Hematological & solid malignancies (breast cancer)	2, 12 and 18 months	Radiotherapy	GraSE and T2 FLASH	Inflammatory myocardial injury
5	Krauss et al.	2005	16	Left breast cancer	52 days	Radiotherapy	HASTE triple inversion recovery sequence	Demonstrate reduction in heart volume irradiated
6	Heggemann et al.	2015	49	Left breast cancer	Before, at 6, 12 and 24 months	Chemotherapy + Radiotherapy	SSFP cine sequence	Decrease in EF

Key: EF=ejection fraction; SSFP=steady-state free precession; STIR=short tau inversion recovery

Results

A total of six (7) articles were screened and graded for quality. Articles graded as high and moderate in terms of quality assessment were included in the study whereas articles graded as weak were excluded in the review because findings from such articles might introduce bias which can affect the overall findings of the study. Four (4) out of the articles were rated as high whereas two (2) as moderate because they were deficient in one or more of the quality assessment criteria provided by CASP. Only one (1) article was graded as weak and was excluded from the study. Table 3 below shows the characteristics of the six (6) articles screened and included in the review as follows:

- Sample size reported in terms of number of patients
- Type of cancer treated
- Treatment methods employed
- Imaging modality(ies) used in evaluating the heart
- Period MRI was done post radiotherapy

Discussion

Radiotherapy plays a significant role in the treatment of breast cancer and is most effective and efficient way to eliminate residual diseases after breast cancer surgery (20,21). Postoperative radiation treatment for breast cancer patients has shown to be of paramount importance as it significantly reduce the threat of local reappearance. It has reduced deaths, and has become the customary treatment for breast cancer at early stages (20,21). Breast cancer radiotherapy can result to

incidental cardiac irradiation due to its proximity to the breast or its presence within the irradiation field(20). Radiotherapy involving a mean dose to the heart of 3Gy would increase the risk of death from ischemic heart disease from 1.9 to 2.4% (21).

In this review, all of the patients were women with long-term or short-term follow-up after radical operation of the left breast or completion of radiotherapy of the left breast or a combination of both breast with or without chemotherapy. Most of the patients involved had no history of clinical evidence of baseline cardiac disease at the time of treatment or prior to their study participation. Manifestations of clinical signs and symptoms that are thought to be related to the heart were noted some period post radiation treatment.

The resultant effect of the irradiation is increased risk for a diversity of cardiac diseases including valvular cardiac dysfunction, chronic constrictive pericarditis, coronary artery disease, cardiomyopathy and aortopathy, all appearing after the radiation treatment (20,22). One of the most common manifestations of RIHD occurs if a portion of at least greater than 30% of the heart receives a dose of 5000 rad during radiotherapy (22).These manifestations can be evaluated using various imaging modalities; echocardiography, doppler ultrasonography, computed tomography and MRI either individually or in conjunction with one another to complement the findings from one another.

In all the modalities that can used for the evaluation, MRI offers superior subclinical information and accurate cardiotoxicity assessment (22,23). Clinical CMR can be performed at different field strengths. In this review

majority of the CMR images were obtained with 1.5 tesla MR systems even though a few number of diagnostic CMR images were acquired with 3.0 tesla MR systems. In majority of cases, the CMRs were acquired in cancer patients after some period post radiation treatment. CMR images were acquired with patients in supine position and some in treatment position using suitable surface RF transmitter/receiver coils. CMR images were acquired using: steady-state free precession (SSFP) cine sequence, rapid multi-slice myocardial perfusion imaging, late-gadolinium enhancement (LGE) imaging, phase-contrast flow quantification imaging and velocity-encoded cine imaging to evaluate the cardiac function, volume, scar and geometry. The acquired MRI images delineated the myocardium demonstrating in majority of the studies myocardial changes in patients receiving cancer-related treatment. Geometric assessment of left ventricle to determine ejection fraction was performed without contrast using a steady-state free precession (SSFP) cine sequence. The review also revealed decline in left ventricular ejection fraction (LVEF) and this occurred in both right or left-sided breast cancer patients treated with radiotherapy which appeared to be temporary or permanent. Additionally, there appears to be an association with cumulative radiation dose received as it relates to the magnitude of the persistent post-treatment decline in LVEF. LGE-MRI is important to understand myocardium damage and the cardiac tissue fibrosis. LGE images were acquired some minutes after intravenous introduction of contrast media for myocardial fibrosis assessment using a T1-weighted, segmented inversion-recovery (IR), fast gradient-echo (GRE) pulse sequence. CMR revealed the effect of RT to critical structures of the heart, including the effect of both radiation dose and volume of the heart exposed ranging from inflammatory changes to cardiomyopathy. The review also revealed that there is increased risk of cancer and other forms of tumours that affect the heart in patients receiving or patients that had received radiation treatment (24).

Conclusion

The number of cancer patients receiving radiation treatment is increasing on daily basis and in the process of treatment, damages mostly on tissues and organs near the treatment area are sustained. Although majority of the breast cancer patients that present for radiotherapy procedure had no history of cardiac disease, post treatment cardiac disease manifest and it affects the quality of life of the breast cancer survivors. RIHD can be asymptomatic in early post treatment periods but the symptoms begin to manifest some months after treatment.

Early detection and proper evaluation using imaging especially CMR is very important. CMR acquired using specialized sequences effectively and efficiently assess the radiation induced effect. Accurate cardiotoxicity assessment will help in proper management of affected

patients and will help develop techniques (shielding during treatment) and personalized treatments to improve therapeutic outcome.

Acknowledgment

This research work is financially supported by the USM RUI grant (1001.CIPPT.8012337). The authors would like to express their gratitude to the staff of Advanced Medical & Dental Institute, USM and members of Breast Cancer Translational Research Programme (BCTRP) and Heart Failure Research Initiative, Advanced Medical & Dental Institute, USM for the continuous support.

Ethical Clearance

This study was approved by the Research Ethics Committee of Universiti Sains Malaysia (USM/JEPeM/16110523).

Competing Interests

The authors declare that there is no conflict of interest in this study.

References

1. Koutroumpakis E, Palaskas NL, Lin SH, Abe J, Liao Z, Banchs J, et al. Modern Radiotherapy and Risk of Cardiotoxicity. *Chemotherapy*. 2020;65(3–4):65–76.
2. Tan W, Li X, Dai Y. Radiation-Related Heart Disease: Up-to-Date Developments. In: Onal C, editor. *Radiotherapy* [Internet]. InTech; 2017 [cited 2021 May 27]. Available from: <http://www.intechopen.com/books/radiotherapy/radiation-related-heart-disease-up-to-date-developments>
3. Liu Y, Wu S, Liu Y, Zhang H, Zhang M, Tang Z, et al. Cathodic protected Mn²⁺ by Na₂WO₃ nanorods for stable magnetic resonance imaging-guided tumor photothermal therapy. *Biomaterials*. 2020;234:119762.
4. Nitsche M, Pahl R, Huber K, Eilf K, Dunst J. Cardiac Toxicity after Radiotherapy for Breast Cancer: Myths and Facts. *Breast Care*. 2015;10(2):131–5.
5. Steiner RE. The hammersmith clinical experience with nuclear magnetic resonance. *Clin Radiol*. 1983;34(1):13–23.
6. Morris ED, Aldridge K, Ghanem AI, Zhu S, Glide-Hurst CK. Incorporating sensitive cardiac substructure sparing into radiation therapy planning. *J Appl Clin Med Phys*. 2020 Nov;21(11):195–204.
7. Ky B. Priorities in the Cardiovascular Care of Breast Cancer Survivors. *J Oncol Pract*. 2018 Apr;14(4):205–11.
8. Jeong D, Gladish G, Chitiboi T, Fradley MG, Gage KL, Schiebler ML. MRI in cardio-oncology: A review of cardiac complications in oncologic care. *J Magn Reson Imaging*. 2019 Nov;50(5):1349–66.
9. Jordan JH, Hundley WG. MRI of Cardiotoxicity. *Cardiol Clin*. 2019 Nov;37(4):429–39.

10. Speers C, Murthy VL, Walker EM, Glide-Hurst CK, Marsh R, Tang M, et al. Cardiac MRI and blood biomarkers for evaluation of radiation-induced cardiotoxicity in breast cancer patients: results of a phase II clinical trial. *Int J Radiat Oncol* [Internet]. 2021; Available from: <https://www.sciencedirect.com/science/article/pii/S0360301621027322>
11. Liberati A, Altman DG, Tetzlaff J, Mulrow C, Gotzsche PC, Ioannidis JPA, et al. The PRISMA statement for reporting systematic reviews and meta-analyses of studies that evaluate healthcare interventions: explanation and elaboration. *BMJ*. 2009 Dec 4;339(jul21 1):b2700–b2700.
12. Akers j. Systematic reviews: CRD guidance for undertaking reviews in healthcare. University of york: York CRD; 2009.
13. Higgins JPT, Cochrane Collaboration, editors. *Cochrane handbook for systematic reviews of interventions*. Second edition. Hoboken, NJ: Wiley-Blackwell; 2020. (Cochrane book series).
14. Eriksen Mette Brandt FTF. The impact of patient, intervention, comparison, outcome (PICO) as a search strategy tool on literature search quality: a systematic review. *J Med Libr Assoc*. 2018 Oct;4(106):420–31.
15. Baumann G. Acromegaly. *Endocrinol Metab Clin North Am*. 1987;16(3):685–703.
16. Carneiro C de S, Lopes J de L, Herdman TH, Lopes CT, Bachion MM, Bottura Leite de Barros AL. Construction and Validation of a Data Collection Tool for the Clinical Assessment of Human Responses of Outpatients With Chronic Cardiovascular Diseases. *Int J Nurs Knowl*. 2014 Oct 1;25(3):161–7.
17. Scienedirect. Make the most of your access to ScienceDirect. p. 21. (Elsevier).
18. Critical Appraisal Skills Programme(CASP). *Critical Appraisal Skills Programme(CASP)-Qualitative checklist 2018*. 2018.
19. Evans N, Lasen M, Tsey K. *A Systematic Review of Rural Development Research: Characteristics, Design Quality and Engagement with Sustainability*. In 2015.
20. Walker V, Crijns A, Langendijk J, Spoor D, Vliegenthart R, Combs SE, et al. Early Detection of Cardiovascular Changes After Radiotherapy for Breast Cancer: Protocol for a European Multicenter Prospective Cohort Study (MEDIRAD EARLY HEART Study). *JMIR Res Protoc*. 2018 Oct 1;7(10):e178.
21. Lai J, Hu S, Luo Y, Zheng R, Zhu Q, Chen P, et al. Meta-analysis of deep inspiration breath hold (DIBH) versus free breathing (FB) in postoperative radiotherapy for left-side breast cancer. *Breast Cancer*. 2020 Mar 1;27(2):299–307.
22. Zhuang X-F, Yang Y-M, Sun X-L, Liao Z-K, Huang J. Late onset radiation-induced constrictive pericarditis and cardiomyopathy after radiotherapy: A case report. *Medicine (Baltimore)*. 2017 Feb;96(5):e5932.
23. Krauss DJ, Kestin LL, Raff G, Yan D, Wong J, Gentry R, et al. MRI-based volumetric assessment of cardiac anatomy and dose reduction via active breathing control during irradiation for left-sided breast cancer. *Int J Radiat Oncol*. 2005;61(4):1243–50.
24. Suehiro S, Matsuda M, Hirata T, Taniyama D, Kuraoka K, Takasaki T-I, et al. Primary cardiac rhabdomyosarcoma developed after receiving radiotherapy for left breast cancer 18 years prior. *J Cardiol Cases*. 2017 Jun;15(6):181–3.