

# RECURRENT PAPILLARY THYROID CARCINOMA POST-TOTAL THYROIDECTOMY WITH LUNG AND NECK LYMPH NODE METASTASES

**Hadmoko ST<sup>1</sup>, Nirmawati K<sup>1</sup>, and Pranoto A<sup>2</sup>.**

<sup>1</sup>Department of Internal Medicine, Faculty of Medicine, Universitas Airlangga – Dr. Soetomo General Academic Hospital, Surabaya, East Java 60285, Indonesia

<sup>2</sup>Division of Endocrine Metabolic and Diabetes, Department of Internal Medicine, Faculty of Medicine, Universitas Airlangga – Dr. Soetomo General Academic Hospital, Surabaya, East Java 60285, Indonesia

## Correspondence:

Kiki Nirmawati,

Department of Internal Medicine, Faculty of Medicine,  
Airlangga University, Surabaya, Indonesia

Dr. Soetomo General Hospital, Surabaya, East Java 60285, Indonesia

Email: ned.indische.artsenschool@gmail.com

## Abstract

Thyroid malignancy, although rare, serves as the most common type of all endocrine gland malignancies and papillary thyroid carcinoma (PTC) represents approximately 70–90% of thyroid malignancies with a low incidence of distant metastases. We report a case of a patient with recurrent PTC post-total thyroidectomy with lung and right neck metastases. The objective of this report was to reduce the possibility of tumor recurrence and to improve treatment outcomes for tumor recurrence. The patient presented to Dr. Soetomo Hospital with a chief complaint of recurrent enlarging non-tender lumps in the front and right regions of neck since March 2018. The patient had a history of total thyroidectomy in 2016 and received levothyroxine therapy. Two years post-surgery, however, the patient stopped the medication due to boredom. Laboratory investigation showed low free thyroxine (FT4) and increased thyroid stimulating hormone (TSH). Ultrasound examination revealed the presence of multiple lesions in the left and right thyroid fossa, assumingly originating from recurrent residual masses. Multisite lymph node metastases were recorded. Fine needle aspiration biopsy (FNAB) was performed and confirmed the recurrent PTC in front and right regions of neck. The patient was diagnosed with stage IVB (T2N1bM1) recurrent PTC post-total thyroidectomy with lung and neck lymph node metastases and hypothyroidism. The patient was treated with levothyroxine 100 mg daily and radioactive iodine (I-131) ablation, and scheduled for thyroidectomy. In conclusion, this case highlights the critical continuous levothyroxine therapy in PTC patients with post- thyroidectomy. Adequate understanding of patients about the disease is therefore critical as well as to maintain their therapy adherence.

**Keywords:** Papillary Thyroid Carcinoma, Thyroid Malignancy, Thyroidectomy, Lymph Node Metastasis, Therapy Adherence.

## Introduction

Thyroid malignancy is considered rare, accounting for approximately 0.85% and 2.5% of all malignancies in men and women, respectively; however, thyroid malignancy is the most common type of all endocrine gland malignancies (1). Differentiated thyroid cancers (DTCs), including papillary thyroid carcinoma (PTC) and follicular cancers, represent the vast majority (> 90%) of all thyroid cancers. There were approximately 63,000 thyroid cancer cases diagnosed in the United States in 2014, almost twice higher compared to those in 2009 (37,200 cases) (2). The incidence increased by almost three times within the period of 3.4 decades (4.9 per 100,000 in 1975 to 14.3 per 100,000 in 2009) (2). In the United Kingdom, the incidence of thyroid cancer is about 5 in 100,000 women

and 2 in 100,000 men (3). Overdiagnosis due to ultrasound screening and cytologic examination (needle aspiration), as well as a high exposure to radiation agents, might have contributed to the increased incidence of differentiated thyroid carcinoma (4).

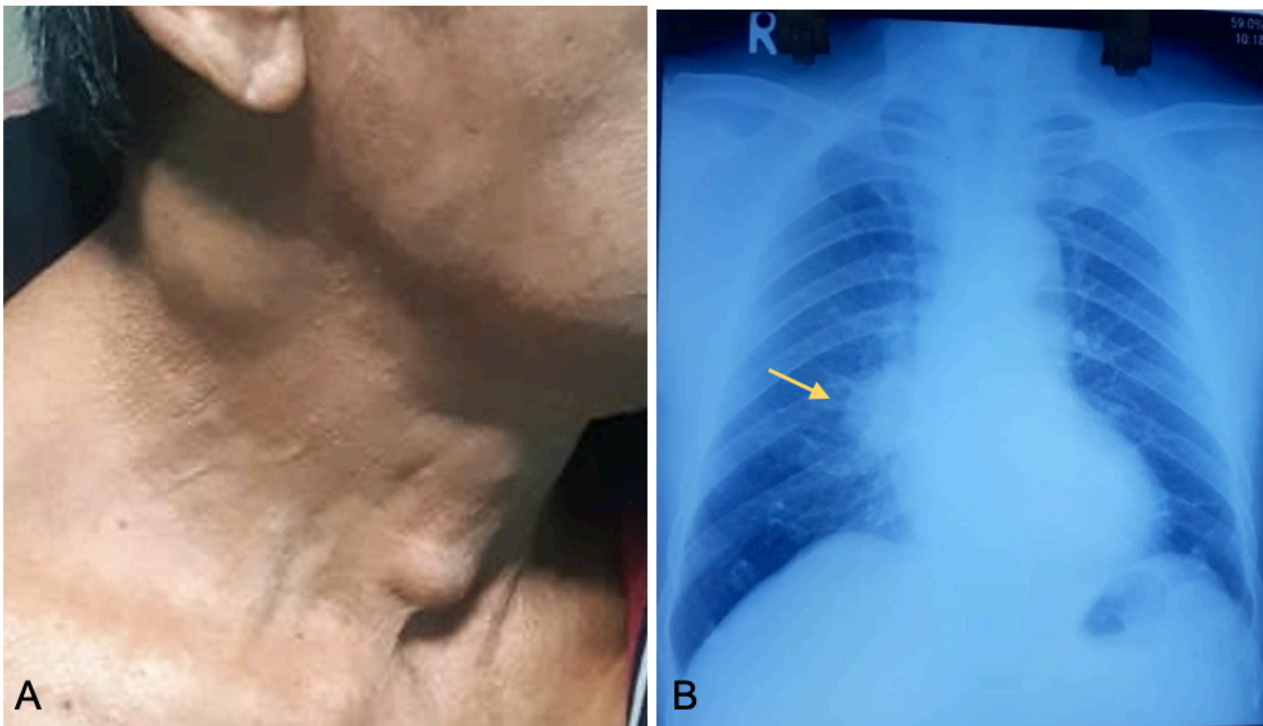
The long-term prognosis of differentiated thyroid cancer is excellent, with a survival rate of 92–98% at 10 years of follow-up (3). However, 5–20% of patients develop local or regional recurrences requiring further treatment, while 10–15% develop distant metastases (3). Several factors such as gender, age at cancer onset, histology, and the stage of tumor may influence the prognosis while accurate diagnosis, treatment, and long-term follow-up are prominent to achieve and maintain good survival rates (3).

Surgery, radioactive iodine ablation, and L-thyroxine suppression therapies are among several therapy modalities for thyroid carcinoma, including differentiated carcinoma in particular. The aggressiveness of therapy depends on the prognostic risk factors in each patient. Treatment outcomes can be evaluated using imaging procedure and markers of malignancy (1). Most thyroid carcinomas are curable, especially those which have not yet distantly metastasized. If the cancer is incurable, removing or destroying as much of the cancer as possible, as well as preventing it from growing, spreading, or recurring for as long as possible might be the goals of treatments (5). This study aims to reduce the risk of tumor recurrence and enhance the effectiveness of treatment for tumor recurrence. In this case report, we report a case of a patient with stage IVB (T2N1bM1) recurrent PTC post

total thyroidectomy with lung and right neck lymph nodes metastases.

### Case report

A 60-year-old male patient presented to the Endocrine unit at Dr. Soetomo General Academic Hospital in March 2020 with a chief complaint of recurrent enlarging tumor on the neck since March 2018 (2 x 2 cm in the neck anterior and 5 x 5 cm in the right neck) (Figure 1A). There were no complaints of tumor pain, hoarseness, shortness of breath, dysphagia, fever, or cough. Weight loss was reported. The patient also often felt tired, weak, lethargic, and sleepy in spite of having adequate sleep. Urination was normal, but bowel movement was hard to pass (once in 3 days). Nausea and vomiting were denied.



**Figure 1:** (A) Lumps on the front and right regions of the neck; (B) The result of chest x-ray exhibited an oval-shaped opacity (arrow) with partially indistinct boundaries and irregular edges in the paracardiac region

The patient had a history of thyroid surgery (total thyroidectomy) in 2016 to remove a multifocal PTC (size: 6 x 4.5 x 2.5 cm<sup>3</sup>) infiltrating into perithyroidal tissue. Multisite lymph node metastases were observed (in the 7 middle, 7 of the 10 right, 4 of the 14 left, and 1 of the 3 level II lymph nodes with perinodal invasion). Angioinvasion and perineural invasions were also detected. The patient then received post-surgical therapy with levothyroxine (2 x 100 mg/day). In 2018, however, the patient stopped his medication due to boredom and did not undergo any treatment until the present hospital admission. History of hypertension, diabetes mellitus, and heart disease was denied. There was no family history of such illness.

The patient had previously worked as a farmer but was currently unemployed.

Physical examination revealed a fair general condition, with a Glasgow Coma Scale (GCS) of 4-5-6, blood pressure of 110/70 mmHg, heart rate of 70 beats per minute, respiratory rate of 20 beats per second, and temperature of 36.8°C. The head and neck evaluation exhibited no anemic conjunctiva, scleral icterus, cyanosis, or dyspnea. The jugular venous pressure (JVP) was normal. Smooth-surface, hard-consistency, fixed, and non-tender lumps measuring 2 x 2 cm and 5 x 5 cm were observed in the front and right regions of the neck, respectively. The assessments

of Cranial nerve IX and X showed normal findings. Chest examination exhibited symmetrical movements and the absence of retractions. S1 and the 2nd heart sound were normal. No murmur, gallops, or pericardial friction rub were heard. There was vesicular breathing over both of the hemithorax during the lung examination. Rhonchi and wheezing were not detected. Abdominal examination indicated normal bowel sounds and non-palpable liver and spleen. There were no muscular defenses, ascites, organomegaly, or tenderness during abdominal palpation. Examination of the extremities showed a warm dry red acral. Edema was not found.

Initial laboratory investigation showed low free thyroxine (FT4) (0.48 ng/dL) and high thyroid stimulating hormone (TSH) (123.938 µIU/mL), considered to indicate hypothyroidism (Table 1). The result of chest x-ray exhibited an oval-shaped opacity (size: ± 4 x 5 cm) with partially blurred boundaries and irregular edges in the right pericardiac region, with differential diagnoses of the metastasis and right lung masses (Figure 1B).

**Table 1:** The results of the patient’s laboratory test

Lab parameters (unit)	Results	
	Initial test	Follow-up
Hemoglobin (g/dL)	13.1	na
White blood cells (/mm <sup>3</sup> )	11,750	na
Platelets (/mm <sup>3</sup> )	305,000	na
Neutrophils (%)	56.8	na
Lymphocyte (%)	28.4	na
Serum glutamic oxaloacetic transaminase (U/L)	36	na
Serum glutamic pyruvic transaminase (U/L)	65	na
Blood urea nitrogen (mg/dL)	15	na
SK (mg/dL)	1.1	na
Random blood glucose (mg/dL)	89	na
Sodium (mmol/L)	141	131
Potassium (mmol/L)	4.6	4.6
Chloride (mmol/L)	109	98
Calcium (mg/dL)	8.8	8.7
Free thyroxin, FT4 (ng/dL)	0.48	2.33
Thyroid stimulating hormone (µIU/mL)	123.938	1.075
Partial thromboplastin time (second)	9.2	na
Activated partial thromboplastin time (second)	27.4	na
Phosphate (mmol/L)	na	4.2

Thyroid ultrasound revealed irregularly shaped lesions with clear margins, and wider-than-tall hypoechoic lesions (1.64 x 1.63 cm and 0.58 x 0.56 cm) in the right thyroid fossa, whereas a heteroechoic nodule with an irregularly

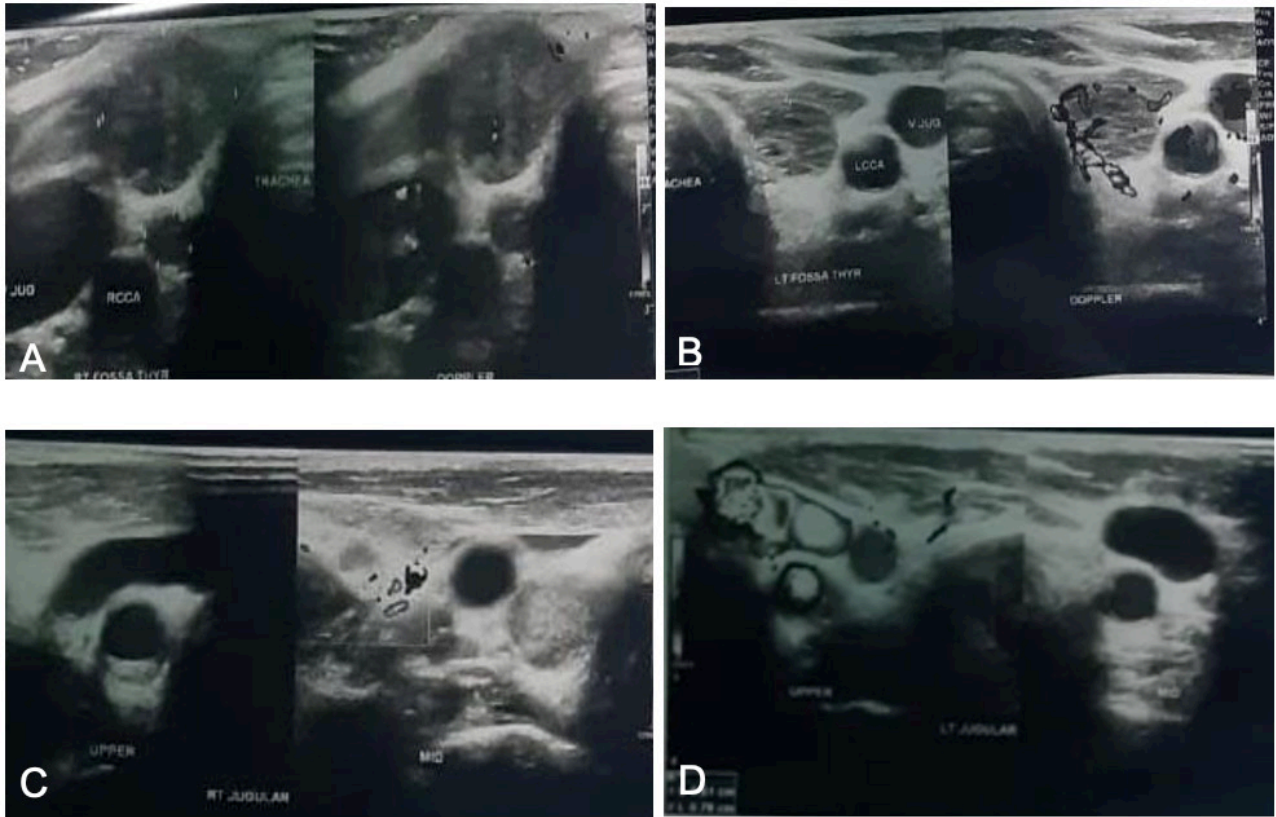
shaped, clear boundary, and wider-than-tall in size (1.1 x 1.01 cm) was observed in the left thyroid fossa. These multiple lesions in both of the thyroid fossa might derive from recurrent residual masses. Intra- and peri-lesion vascularization were detected in both right and left fossa lesions using color doppler ultrasonography (CDUS) (Figure 2A-B). Furthermore, rounded lymph nodes with blurred borders and loss of central echogenic fatty hilum were detected in the right mid and the left upper jugulars 1.2 cm and 0.6 x 0.78 cm in size, respectively. The result of the CDUS showed no hilar vascularization (Figure 2C-D). A fine needle aspiration biopsy (FNAB) of the thyroid and right neck nodules revealed the existence of anaplastic cell clusters and distribution with round-to-oval nuclei, pleomorphic, coarse chromatin, narrow cytoplasm, and visible intranuclear inclusion (Figure 3A-B), leading to the diagnoses of recurrent PTC in the colli anterior and metastases of PTC in the right neck.

Based on all the anamnesis, physical and adjuvant examinations, as well as medical history, the patient was diagnosed with stage IVB (T2N1bM1) recurrent PTC post total thyroidectomy with lung and right neck lymph node metastases. The classification of Tumor Node Metastasis (TNM) staging system based on International guideline (6). The patient was treated with levothyroxine 100 mg daily. After 3 weeks of therapy, an elevated FT4 (2.33 ng/dL) and a decreased TSH (1.075 µIU/mL) values were observed (Table 1). The patient was then intended for nuclear medicine consultation for possible radioiodine (I-131) ablation therapy as well as arranged for thoracic surgery.

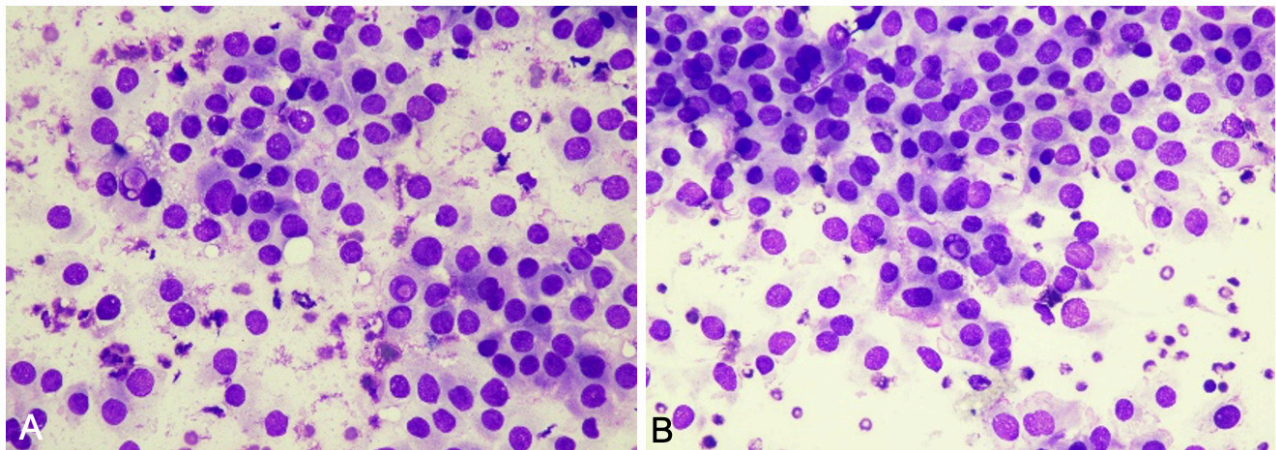
Approximately a month after the last laboratory checkup, the patient presented to the Endocrine Unit for control and complained of an occasional dry cough (no sputum). Fever and shortness of breath were denied, while frequent fatigue, weakness, and hard-to-pass bowel movement were reported. The patient’s general condition was observably fair and the vital signs were as follows: GCS of 4-5-6, blood pressure of 130/70 mmHg, heart rate of 68 x/m, respiratory rate of 20 x/m, and the temperature of 36.2 °C. FT4 and TSH level was 2.01 ng/dl and 1.25 µIU/mL, respectively. The same nodules with a smooth surface, hard consistency, fixed, and painless were still observed on the neck anterior (2 x 2 cm) and the right neck (5 x 5 cm). After consulting a nuclear radiologist, the patient underwent the radioiodine ablation therapy. Levothyroxine was temporarily stopped two weeks prior to the radioiodine ablation.

Two months later, the patient underwent another radioiodine ablation therapy and presented to the Endocrine Unit the next day for control. The patient was in a fair general condition with GCS of 4-5-6. Vital signs were within normal limits (blood pressure of 120/80 mmHg, heart rate of 71 x/m, respiratory rate of 20 x/m, and temperature of 36.5°C). Laboratory evaluation showed FT4 of 2.09 ng/dL, TSH of 0.114 µIU/mL, calcium 8.3 mg/dL, and albumin 3.0 g/dL. The same masses on the front and right regions of the neck with the same sizes and characteristics were still detected. The patient was diagnosed with stage





**Figure 2:** Thyroid ultrasonography showed (A) hypoechoic lesions in the right fossa (left) with intra- and peri-lesion vascularization (right); (B) A heteroechoic lesion in the left fossa (left) with intra- and peri-lesion vascularization (right); A rounded lymph node with the absence of echogenic fatty hilum in the (C) right mid jugular and (D) left upper jugular (lefts). CDUS does not show hilar vascularization (C-D, rights).



**Figure 3:** FNAB of the (A) thyroid and (B) right neck nodules shows the clusters and distribution of anaplastic cells with round-oval nuclei, pleomorphic, coarse chromatin, narrow cytoplasm, and visible intranuclear inclusion.

IVB (T2N1bM1) recurrent PTC post-radioiodine ablation, and therapy with levothyroxine 100 mg/day was continued. In the end of the treatment the patient had good condition.

**Discussion**

Distinguishing malignant and benign thyroid nodules are often clinically challenging since many diseases could be present in the thyroid nodules (6-9). The clinical

presentations of thyroid carcinoma in most cases are generally mild. In malignant nodules, the lesions may develop and appear in several few months or show only mild symptoms from a decade-enlarged thyroid gland, except for anaplastic thyroid carcinoma which develops rapidly with a poor prognosis. Nodules in men have a higher chance of becoming malignant than those in women (1). The age of < 20 or > 60 years; hoarseness; breathing difficulty; coughing; dysphagia; a history of ionizing radiation during childhood; a solid, hard, uneven, and fixed nodule; the presence of cervical lymphadenopathy; and a previous history of thyroid malignancy are among several factors statistically associated with an increased risk of malignancy (1, 2).

In the present case, the patient had a history of total thyroidectomy in 2016, increasing the chance for the patient to develop malignancy. The lesions (non-tender, smooth surface, hard consistency, fixed, and painless) then reappeared and enlarged in the front and right regions of neck two years before admission to the current hospital, suspected as residual malignant nodules. The patient had not shown any symptoms such as hoarseness, shortness of breath, or dysphagia post-surgery, causing the delay in medication. At the presentation, the patient had a fair general condition.

The American Thyroid Association (ATA) guidelines recommend measuring TSH level once a thyroid nodule is detected (10). If the level of TSH is normal or high, a FNAB should be performed on a nodule of  $\geq 1$  cm. Thyroidectomy may become the therapy of choice once suspicious malignancy or malignancy was detected (11). A radionuclide scan (Tc-99m, preferably I-123) should be carried out only if the TSH level is below the normal range (2). Our patient had a very high level of TSH (123.938  $\mu$ U/mL) and a low level of FT4 (0.48 ng/dL), considered indicative of hypothyroidism. The result of the chest x-ray exhibited an oval-shaped right paracardial opacity with partially blurred boundaries and irregular edges (Figure 1B). Ultrasound examination revealed the presence of multiple lesions in the left and right thyroid fossa, assumingly originating from recurrent residual masses. Suspicious lymph nodes in the mid-right and upper left jugulars were also observed (Figure 2A-D). Since the nodules were bigger than 1 cm in size, FNAB was performed and the results suggested recurrent PTC in the colli anterior and metastatic PTC in the right neck. In addition, a previous histopathological examination showed PTC multifocal infiltrating into parathyroid tissue, for which the patient underwent total thyroidectomy to remove the largest tumor (6 x 4.5 x 2.5  $\text{cm}^3$ ). Multisite lymph node metastases were also recorded. The patient was diagnosed with stage IVB (T2N1bM1) recurrent PTC post total thyroidectomy with lung and lymph node metastases of right neck and hypothyroidism.

Distant metastases occur in patients with differentiated thyroid carcinoma with a prevalence of up to 10%, affecting the lungs and bones in particular (12). Surgery

and radioiodine therapies, followed by levothyroxine substitution are among the established therapeutic procedure for the treatment of differentiated thyroid carcinoma and metastatic tumors (2, 13). Thyroidectomy is recommended for all PTCs of > 1 cm and/or for all metastatic or macroscopic invasive PTCs (13) while total thyroidectomy is suggested for patients with tumors greater than 4 cm in diameter or tumors of any size associated with any of the following characteristics: multifocal disease, bilateral disease, extrathyroidal extension (pT3 and pT4a), familial disease, and those with clinically or radiologically lymph nodes and/or distant metastases involvement (3). Radioiodine treatment (RIT) is recommended for DTC patients with a high risk of tumor recurrence to irradiate thyroid remnants and unresectable or incompletely resected DTCs (14). In addition, lifelong thyroid hormone therapy with levothyroxine is required to suppress thyrotropin. Long-term suppression of TSH to <0.1 mU/L is currently only recommended for high-risk patients and patients with indefinitely persistent disease in the absence of specific contraindications. No evidence-based data are available for the optimal duration of TSH suppression. According to the ATA guidelines, serum TSH should be maintained between 0.1 and 0.5 mU/L in patients with high-risk disease but have an excellent or moderate response to therapy for up to 5 years (2).

The re-emergence of the tumor in the patient was presumably associated with the ability of TSH to enhance the growth of the remaining differentiated thyroid carcinoma cells due to the discontinuation of the medication for the past two years before the admission to the current hospital. Since the tumor has metastasized and was suspicious of being malignant, radioactive iodine ablation (RIA) and levothyroxine therapies were given, whereas surgery was still in the scheduling process. Two weeks prior to RIA therapy, levothyroxine treatment was temporarily stopped to ensure a high intake of radioiodine (I-131) in residual tumor or metastatic tissue. levothyroxine therapy was continued once RIA had been completed. This patient had a low prognosis for overall survival.

### **Conclusion**

The patient was diagnosed with stage IVB (T2N1bM1) recurrent PTC post-total thyroidectomy with the lung and the right neck lymph nodes metastases. The ability of TSH to increase the growth of the remaining DTC cells due to the long-term discontinuation of levothyroxine might have contributed to the re-emergence of the tumors in the patient. The patient was also treated with levothyroxine 100 mg daily and since the tumor has metastasized, radioiodine ablation therapy was performed and thyroidectomy was planned.

### **Informed consent**

The patient had agreed and signed informed consent regarding publishing this clinical case in an academic journal without exposing the patient's identity.

### Acknowledgments

We would like to thank the patient and all the hospital staff involved in the patient's care.

### Competing interest

The authors declare no conflict of interest regarding the manuscript.

### Financial support

None.

### References

- Subekti I. Thyroid Carcinoma. Buku Ajar Ilmu Penyakit Dalam PAPDI edisi VI. Jakarta: Interna Publishing. 2014. 2471-7.
- Haugen BR, Alexander EK, Bible KC, Doherty GM, Mandel SJ, Nikiforov YE, *et al.* 2015 American Thyroid Association management guidelines for adult patients with thyroid nodules and differentiated thyroid cancer: the American Thyroid Association guidelines task force on thyroid nodules and differentiated thyroid cancer. *Thyroid*. 2016;26(1):1-133.
- Mitchell A, Gandhi A, Scott-Coombes D, Perros P. Management of thyroid cancer: United Kingdom national multidisciplinary guidelines. *J Lar Otol*. 2016;130(S2):S150-S60.
- Bove A, Panaccio P, Palone G, Esposito L, Marino L, Bongarzone G. Impact of the new guidelines of the American Thyroid Association on the treatment of the differentiated thyroid tumor in an Italian center with medium-high volume thyroid surgery. *BMC surgery*. 2019;18(1):1-4.
- American Cancer Society. Treating Thyroid Cancer. 2019. Available at: <https://www.cancer.org/cancer/thyroid-cancer/treating/by-stage.html>. Accessed 20 January 2022.
- Setiawati R, Wulanhandarini T, Hayati F, Erawati D, Jaya MG, Thoriq AA, *et al.* Clinical and ultrasonography evaluation of thyroid tumor screening in symptomatic patient of Bajulmati primary care center, Banyuwangi, East Java, Indonesia. *J Med*. 2022; 101:e32546.
- Damanik ST, Netty E, Gunawan K, Irmawati M, Harianto A, Indarso F. Subtotal pancreatectomy for persistent hyperinsulinemia hypoglycemia in neonate (a case report). *Folia Medica Indonesiana*. 2003; 39:269.
- Tjokroprawiro A. Thyroid storm: quick diagnosis and quick treatment. *Folia Medica Indonesiana*. 2009;45:78-87.
- Windradi C, Soelistijo SA, Mudjanarko SW, Yusuf M. Rare presentation of subclinical hypothyroidism from a lingual thyroid. *Journal of the ASEAN Federation of Endocrine Societies*. 2021; 36:231.
- Brierley JD, Gospodarowicz MK, Wittekind C. The TNM classification of malignant tumours. 8<sup>th</sup> edition. Oxford: Wiley Blackwell. 2017.
- Burman KD, Wartofsky L. Thyroid nodules. *N Engl J Med*. 2015;373(24):2347-56.
- Benbassat CA, Mechlis-Frishi S, Hirsch D. Clinicopathological characteristics and long-term outcome in patients with distant metastases from differentiated thyroid cancer. *World J Surg* 2006;30(6):1088-95.
- Luster M, Clarke S, Dietlein M, Lassmann M, Lind P, Oyen W, *et al.* European association of nuclear medicine (EANM). *Eur J Nucl Med Mol Imaging*. 2008;35:1941-59.
- Schmidbauer B, Menhart K, Hellwig D, Grosse J. Differentiated thyroid cancer—treatment: state of the art. *Int J Mol Sci*. 2017;18(6):1292.